

## 2010 ACCF/AHA/AATS/ACR/ASA/SCA/SCAI/SIR/STS/SVM Guidelines for the Diagnosis and Management of Patients With Thoracic Aortic Disease

A Report of the American College of Cardiology Foundation/American Heart Association Task Force on Practice Guidelines, American Association for Thoracic Surgery, American College of Radiology, American Stroke Association, Society of Cardiovascular Anesthesiologists, Society for Cardiovascular Angiography and Interventions, Society of Interventional Radiology, Society of Thoracic Surgeons, and Society for Vascular Medicine

*Endorsed by the North American Society for Cardiovascular Imaging*

### WRITING GROUP MEMBERS

Loren F. Hiratzka, MD, Chair\*; George L. Bakris, MD†; Joshua A. Beckman, MD, MS‡; Robert M. Bersin, MD§; Vincent F. Carr, DO||; Donald E. Casey, Jr, MD, MPH, MBA¶; Kim A. Eagle, MD\*#; Luke K. Hermann, MD\*\*; Eric M. Isselbacher, MD\*; Ella A. Kazerooni, MD, MS††; Nicholas T. Kouchoukos, MD‡‡; Bruce W. Lytle, MD§§; Dianna M. Milewicz, MD, PhD; David L. Reich, MD|||; Souvik Sen, MD, MS¶¶; Julie A. Shinn, RN, MA, CCRN†; Lars G. Svensson, MD, PhD###; David M. Williams, MD\*\*\*\*

### ACCF/AHA TASK FORCE MEMBERS

Alice K. Jacobs, MD, FACC, FAHA, Chair 2009–2011; Sidney C. Smith, Jr, MD, FACC, FAHA, Immediate Past Chair 2006–2008†††; Jeffery L. Anderson, MD, FACC, FAHA, Chair-Elect; Cynthia D. Adams, MSN, PhD, FAHA†††; Christopher E. Buller, MD, FACC; Mark A. Creager, MD, FACC, FAHA; Steven M. Ettinger, MD, FACC; Robert A. Guyton, MD, FACC, FAHA; Jonathan L. Halperin, MD, FACC, FAHA; Sharon A. Hunt, MD, FACC, FAHA†††; Harlan M. Krumholz, MD, FACC, FAHA†††; Frederick G. Kushner, MD, FACC, FAHA; Bruce W. Lytle, MD, FACC, FAHA†††; Rick Nishimura, MD, FACC, FAHA†††; Richard L. Page, MD, FACC, FAHA†††; Barbara Riegel, DNSc, RN, FAHA\*\*\*; William G. Stevenson, MD, FACC, FAHA; Lynn G. Tarkington, RN; Clyde W. Yancy, MD, FACC, FAHA

\*ACCF/AHA Representative. †AHA Representative. ‡SVM Representative. §SCAI Representative. ||ACCF Board of Governors Representative. ¶American College of Physicians Representative. #Recused from Section 9.2.2.3.1. Recommendations for Descending Thoracic Aorta and Thoracoabdominal Aortic Aneurysms. \*\*American College of Emergency Physicians Representative. ††ACR Representative. ‡‡STS Representative. §§ACCF/AHA Task Force Liaison. |||SCA Representative. ¶¶ASA Representative. ###AATS Representative. \*\*\*\*SIR Representative. †††Former Task Force member during this writing effort.

Authors with no symbol by their name were included to provide additional content expertise apart from organizational representation.

This document was approved by the American College of Cardiology Foundation Board of Trustees and the American Heart Association Science Advisory and Coordinating Committee in January 2010. All other cosponsoring organizations approved in February 2010.

**The online-only Data Supplement is available with this article at <http://circ.ahajournals.org/cgi/content/full/CIR.0b013e3181d4739e/DC1>.**

The American Heart Association requests that this document be cited as follows: Hiratzka LF, Bakris GL, Beckman JA, Bersin RM, Carr VF, Casey DE Jr, Eagle KA, Hermann LK, Isselbacher EM, Kazerooni EA, Kouchoukos NT, Lytle BW, Milewicz DM, Reich DL, Sen S, Shinn JA, Svensson LG, Williams DM. 2010 ACCF/AHA/AATS/ACR/ASA/SCA/SCAI/SIR/STS/SVM Guidelines for the diagnosis and management of patients with thoracic aortic disease: a report of the American College of Cardiology Foundation/American Heart Association Task Force on Practice Guidelines, American Association for Thoracic Surgery, American College of Radiology, American Stroke Association, Society of Cardiovascular Anesthesiologists, Society for Cardiovascular Angiography and Interventions, Society of Interventional Radiology, Society of Thoracic Surgeons, and Society for Vascular Medicine. *Circulation*. 2010;121:e266–e369.

This article has been copublished in the *Journal of the American College of Cardiology*.

Copies: This document is available on the World Wide Web sites of the American College of Cardiology ([www.acc.org](http://www.acc.org)) and the American Heart Association ([my.americanheart.org](http://my.americanheart.org)). A copy of the document is also available at <http://www.americanheart.org/presenter.jhtml?identifier=3003999> by selecting either the “topic list” link or the “chronological list” link (No. KB-0022). To purchase additional reprints, call 843-216-2533 or e-mail [kelle.ramsay@wolterskluwer.com](mailto:kelle.ramsay@wolterskluwer.com).

Expert peer review of AHA Scientific Statements is conducted at the AHA National Center. For more on AHA statements and guidelines development, visit <http://www.americanheart.org/presenter.jhtml?identifier=3023366>.

Permissions: Multiple copies, modification, alteration, enhancement, and/or distribution of this document are not permitted without the express permission of the American Heart Association. Instructions for obtaining permission are located at <http://www.americanheart.org/presenter.jhtml?identifier=4431>. A link to the “Permission Request Form” appears on the right side of the page.

(*Circulation*. 2010;121:e266–e369.)

© 2010 by the American College of Cardiology Foundation and the American Heart Association, Inc.

*Circulation* is available at <http://circ.ahajournals.org>

DOI: 10.1161/CIR.0b013e3181d4739e

**TABLE OF CONTENTS**

Preamble .....e270

1. Introduction .....e270

    1.1. Methodology and Evidence Review .....e270

    1.2. Organization of the Writing Committee .....e271

    1.3. Document Review and Approval .....e271

    1.4. Scope of the Guideline .....e272

        1.4.1. Critical Issues .....e274

    1.5. Glossary of Terms and Abbreviations Used Throughout Guideline .....e274

2. The Thoracic Aorta .....e275

    2.1. The Normal Aorta .....e275

    2.2. Normal Thoracic Aortic Diameter .....e275

3. Thoracic Aortic Histopathology .....e276

    3.1. Atherosclerosis .....e276

    3.2. Aneurysms and Dissections .....e276

    3.3. Vasculitis and Inflammatory Diseases .....e277

4. Imaging Modalities .....e278

    4.1. Recommendations for Aortic Imaging Techniques to Determine the Presence and Progression of Thoracic Aortic Disease .....e278

    4.2. Chest X-Ray .....e279

    4.3. Computed Tomographic Imaging .....e279

        4.3.1. Computed Tomographic Imaging Technique .....e281

    4.4. Magnetic Resonance Imaging .....e281

        4.4.1. Magnetic Resonance Imaging Technique .....e282

        4.4.2. Black Blood Imaging .....e282

        4.4.3. Noncontrast White Blood Imaging .....e282

        4.4.4. Contrast-Enhanced Magnetic Resonance Angiography .....e282

        4.4.5. Phase Contrast Imaging .....e282

    4.5. Standards for Reporting of the Thoracic Aorta on Computed Tomography and Magnetic Resonance Imaging .....e282

    4.6. Angiography .....e283

    4.7. Echocardiography .....e284

        4.7.1. Echocardiographic Criteria for Thoracic Aortic Aneurysms .....e284

        4.7.2. Echocardiographic Criteria for Aortic Dissection .....e284

            4.7.2.1. Diagnostic Accuracy of Echocardiography for Aortic Dissection .....e285

            4.7.2.2. Diagnostic Accuracy of Echocardiography for Acute Intramural Hematoma .....e285

            4.7.2.3. Role of Echocardiography in Following Patients With Chronic Aortic Disease .....e286

5. Genetic Syndromes Associated With Thoracic Aortic Aneurysms and Dissections .....e286

    5.1. Recommendations for Genetic Syndromes ..e286

        5.1.1. Marfan Syndrome .....e287

        5.1.2. Loeys-Dietz Syndrome .....e288

        5.1.3. Ehlers-Danlos Syndrome, Vascular Form or Type IV .....e288

        5.1.4. Turner Syndrome .....e288

        5.1.5. Other Genetic Syndromes With Increased Risk for Thoracic Aortic Aneurysms and Dissections .....e289

        5.1.6. Recommendations for Familial Thoracic Aortic Aneurysms and Dissections .....e289

    5.2. Summary .....e290

6. Other Cardiovascular Conditions Associated With Thoracic Aortic Aneurysm and Dissection .....e291

    6.1. Recommendations for Bicuspid Aortic Valve and Associated Congenital Variants in Adults ...e291

    6.2. Aberrant Right Subclavian Artery .....e292

    6.3. Coarctation of the Aorta .....e292

    6.4. Right Aortic Arch .....e292

7. Inflammatory Diseases Associated With Thoracic Aortic Disease .....e292

    7.1. Recommendations for Takayasu Arteritis and Giant Cell Arteritis .....e292

    7.2. Takayasu Arteritis .....e293

    7.3. Giant Cell Arteritis .....e295

    7.4. Behçet Disease .....e296

    7.5. Ankylosing Spondylitis (Spondyloarthropathies) .....e296

    7.6. Infective Thoracic Aortic Aneurysms .....e296

8. Acute Aortic Syndromes .....e297

    8.1. Aortic Dissection .....e297

        8.1.1. Aortic Dissection Definition .....e297

        8.1.2. Anatomic Classification of Aortic Dissection .....e297

        8.1.3. Risk Factors for Aortic Dissection .....e299

        8.1.4. Clinical Presentation of Acute Thoracic Aortic Dissection .....e300

            8.1.4.1. Symptoms of Acute Thoracic Aortic Dissection .....e300

            8.1.4.2. Perfusion Deficits and End-Organ Ischemia .....e301

        8.1.5. Cardiac Complications .....e303

            8.1.5.1. Acute Aortic Regurgitation .....e303

            8.1.5.2. Myocardial Ischemia or Infarction .....e303

            8.1.5.3. Heart Failure and Shock ...e303

            8.1.5.4. Pericardial Effusion and Tamponade .....e303

        8.1.6. Syncope .....e303

        8.1.7. Neurologic Complications .....e304

        8.1.8. Pulmonary Complications .....e304

        8.1.9. Gastrointestinal Complications .....e304

        8.1.10. Blood Pressure and Heart Rate Considerations .....e304

        8.1.11. Age and Sex Considerations .....e304

    8.2. Intramural Hematoma .....e304

    8.3. Penetrating Atherosclerotic Ulcer .....e306

    8.4. Pseudoaneurysms of the Thoracic Aorta ...e306

    8.5. Traumatic Rupture of the Thoracic Aorta ...e306

    8.6. Evaluation and Management of Acute Thoracic Aortic Disease .....e307

8.6.1. Initial Evaluation and Management . . . . .	e307	9.2. General Medical Treatment and Risk Factor Management for Patients With Thoracic Aortic Disease. . . . .	e318
8.6.1.1. Recommendations for Estimation of Pretest Risk of Thoracic Aortic Dissection . . . . .	e307	9.2.1. Recommendation for Medical Treatment of Patients With Thoracic Aortic Diseases . . . . .	e318
8.6.1.2. Laboratory Testing . . . . .	e307	9.2.1.1. Recommendations for Blood Pressure Control. . . . .	e319
8.6.1.3. Recommendations for Screening Tests. . . . .	e308	9.2.1.2. Recommendation for Dyslipidemia. . . . .	e319
8.6.1.4. Recommendations for Diagnostic Imaging Studies . . . . .	e308	9.2.1.3. Recommendation for Smoking Cessation. . . . .	e319
8.6.1.5. Recommendations for Initial Management . . . . .	e308	9.2.2. Surgical and Endovascular Treatment by Location of Disease. . . . .	e320
8.6.1.6. Recommendations for Definitive Management. . . . .	e308	9.2.2.1. Ascending Aorta and Aortic Sinuses . . . . .	e320
8.6.2. Evaluation and Management Algorithms . . . . .	e309	9.2.2.1.1. Recommendations for Asymptomatic Patients With Ascending Aortic Aneurysm . . . . .	e320
8.6.3. Initial Management. . . . .	e310	9.2.2.1.2. Recommendation for Symptomatic Patients With Thoracic Aortic Aneurysm . . . . .	e320
8.6.3.1. Blood Pressure and Rate Control Therapy . . . . .	e311	9.2.2.1.3. Endovascular Grafting for Ascending Aortic Aneurysm . . . . .	e321
8.6.3.2. Additional Antihypertensive Therapy . . . . .	e312	9.2.2.1.4. Recommendations for Open Surgery for Ascending Aortic Aneurysm . . . . .	e321
8.6.3.3. Pain Control . . . . .	e312	9.2.2.2. Recommendations for Aortic Arch Aneurysms . . . . .	e323
8.6.3.4. Hypotension . . . . .	e312	9.2.2.2.1. Open Surgery. . . . .	e323
8.6.3.5. Determining Definitive Management . . . . .	e312	9.2.2.3. Descending Thoracic Aorta and Thoracoabdominal Aorta. . . . .	e324
8.6.4. Recommendation for Surgical Intervention for Acute Thoracic Aortic Dissection. . . . .	e312	9.2.2.3.1. Recommendations for Descending Thoracic Aorta and Thoracoabdominal Aortic Aneurysms. . . . .	e324
8.6.5. Endovascular Interventions. . . . .	e313	9.2.2.3.2. Endovascular Versus Open Surgical Approach. . . . .	e324
8.6.6. Principles of Treatment for Intramural Hematoma and Penetrating Atherosclerotic Ulcer. . . . .	e313	9.2.2.3.3. End-Organ Preservation During Thoracic Endograft Implantation. . . . .	e325
8.6.6.1. Intimal Defect Without Intramural Hematoma . . . . .	e313	9.2.2.3.4. Periprocedural Complications of Endograft Procedures . . . . .	e326
8.6.6.2. Intimal Defect With Intramural Hematoma . . . . .	e313	9.2.2.3.5. Open Surgical . . . . .	e327
8.6.6.3. Recommendation for Intramural Hematoma Without Intimal Defect . . . . .	e313	9.2.2.3.6. End-Organ Preservation During Open Thoracoabdominal Repairs . . . . .	e328
8.7. Treatment for the Management of Traumatic Aortic Rupture . . . . .	e313		
9. Thoracic Aortic Aneurysms . . . . .	e314		
9.1. General Approach to the Patient. . . . .	e315		
9.1.1. Recommendation for History and Physical Examination for Thoracic Aortic Disease . . . . .	e315		
9.1.1.1. Coronary Artery Disease. . . . .	e316		
9.1.1.2. Emboli . . . . .	e317		
9.1.1.3. Associated Renal Ischemia . . . . .	e317		
9.1.1.4. Associated Mesenteric Ischemia . . . . .	e317		
9.1.1.5. Associated Peripheral Ischemia . . . . .	e317		
9.1.2. Differential Diagnosis. . . . .	e317		
9.1.2.1. Symptoms. . . . .	e317		
9.1.2.2. Physical Findings . . . . .	e317		
9.1.3. Considerations for Imaging . . . . .	e318		

9.2.2.3.7. Aortic Dissection With Malperfusion . . . . .	e328	14.5.2.1. Monitoring of Spinal Cord Function in Descending Thoracic Aortic Repairs . . . . .	e337
10. Special Considerations in Pregnant Patients With Aortic Disease. . . . .	e328	14.5.2.2. Maintenance of Spinal Cord Arterial Pressure . . . . .	e338
10.1. Effects of Pregnancy on the Aorta . . . . .	e328	14.5.2.3. Cerebrospinal Fluid Pressure and Drainage . . . . .	e338
10.2. Epidemiology of Chronic and Acute Aortic Conditions in Pregnancy . . . . .	e328	14.5.2.4. Hypothermia . . . . .	e339
10.3. Counseling and Management of Chronic Aortic Diseases in Pregnancy. . . . .	e328	14.5.2.5. Glucocorticoids and Mannitol . . . . .	e339
10.3.1. Recommendations for Counseling and Management of Chronic Aortic Diseases in Pregnancy. . . . .	e328	14.5.3. Recommendations for Renal Protection During Descending Aortic Open Surgical and Endovascular Repairs . . . . .	e339
10.4. Evaluation and Management of Acute Aortic Syndromes During Pregnancy . . . . .	e329	14.6. Complications of Open Surgical Approaches . . . . .	e339
11. Aortic Arch and Thoracic Aortic Atheroma and Atheroembolic Disease. . . . .	e329	14.7. Mortality Risk for Thoracic Aortic Surgery . . . . .	e340
11.1. Recommendations for Aortic Arch and Thoracic Aortic Atheroma and Atheroembolic Disease . . . . .	e329	14.8. Postprocedural Care. . . . .	e341
11.2. Clinical Description. . . . .	e329	14.8.1. Postoperative Risk Factor Management . . . . .	e341
11.3. Risk Factors . . . . .	e330	14.8.2. Recommendations for Surveillance of Thoracic Aortic Disease or Previously Repaired Patients . . . . .	e341
11.4. Diagnosis. . . . .	e330	15. Nursing Care and Patient/Family Education . . . . .	e342
11.5. Treatment . . . . .	e330	15.1. Nursing Care of Medically Managed Patients . . . . .	e342
11.5.1. Anticoagulation Versus Antiplatelet Therapy . . . . .	e330	15.2. Preprocedural Nursing Care. . . . .	e342
11.5.2. Lipid-Lowering Agent. . . . .	e331	15.3. Postprocedural Nursing Care. . . . .	e342
11.5.3. Surgical and Interventional Approaches . . . . .	e331	15.4. Nursing Care of Surgically Managed Patients . . . . .	e343
12. Porcelain Aorta . . . . .	e331	16. Long-Term Issues . . . . .	e344
13. Tumors of the Thoracic Aorta. . . . .	e331	16.1. Recommendation for Employment and Lifestyle in Patients With Thoracic Aortic Disease . . . . .	e344
14. Perioperative Care for Open Surgical and Endovascular Thoracic Aortic Repairs . . . . .	e332	17. Institutional/Hospital Quality Concerns. . . . .	e345
14.1. Recommendations for Preoperative Evaluation . . . . .	e332	17.1. Recommendations for Quality Assessment and Improvement for Thoracic Aortic Disease . . . . .	e345
14.1.1. Preoperative Risk Assessment. . . . .	e333	17.2. Interinstitutional Issues . . . . .	e345
14.2. Recommendations for Choice of Anesthetic and Monitoring Techniques. . . . .	e334	18. Future Research Directions and Issues . . . . .	e346
14.2.1. Temperature Monitoring . . . . .	e334	18.1. Risks and Benefits of Current Imaging Technologies . . . . .	e346
14.2.2. Hemodynamic Monitoring. . . . .	e334	18.2. Mechanisms of Aortic Dissection . . . . .	e346
14.2.3. Transesophageal Echocardiography . . . . .	e334	18.3. Treatment of Malperfusion and Reperfusion Injury . . . . .	e346
14.2.4. Transesophageal Echocardiography for Endovascular Repairs of the Descending Thoracic Aorta . . . . .	e335	18.4. Gene-Based Mechanisms and Models . . . . .	e347
14.3. Airway Management for Descending Thoracic Aortic Repairs . . . . .	e335	18.4.1. Aortic Disease Management Based on the Underlying Genetic Defects. . . . .	e347
14.4. Recommendation for Transfusion Management and Anticoagulation in Thoracic Aortic Surgery. . . . .	e335	18.4.2. Biomarkers for Acute Aortic Dissection . . . . .	e347
14.5. Organ Protection . . . . .	e336	18.4.3. Genetic Defects and Molecular Pathway Analyses . . . . .	e347
14.5.1. Recommendations for Brain Protection During Ascending Aortic and Transverse Aortic Arch Surgery . . . . .	e336	18.4.4. Clinical Trials for Medical Therapy for Aortic Aneurysms . . . . .	e347
14.5.2. Recommendations for Spinal Cord Protection During Descending Aortic Open Surgical and Endovascular Repairs . . . . .	e337	18.5. Aortic Atheroma and Atherosclerosis Identification and Treatment . . . . .	e347
		18.6. Prediction Models of Aortic Rupture and the Need for Preemptive Interventions . . . . .	e347
		18.7. National Heart, Lung, and Blood Institute Working Group Recommendations . . . . .	e347

Appendix 1. Author Relationships With Industry and Other Entities . . . . .	e365
Appendix 2. Reviewer Relationships With Industry and Other Entities . . . . .	e367
Appendix 3. Abbreviation List . . . . .	e369
References . . . . .	e348

## Preamble

It is essential that the medical profession play a central role in critically evaluating the evidence related to drugs, devices, and procedures for the detection, management, or prevention of disease. Properly applied, rigorous, expert analysis of the available data documenting absolute and relative benefits and risks of these therapies and procedures can improve outcomes and reduce costs of care by focusing resources on the most effective strategies. One important use of such data is the production of clinical practice guidelines that, in turn, can provide a foundation for a variety of other applications such as performance measures, appropriate use criteria, clinical decision support tools, and quality improvement tools.

The American College of Cardiology Foundation (ACCF) and the American Heart Association (AHA) have jointly engaged in the production of guidelines in the area of cardiovascular disease since 1980. The ACCF/AHA Task Force on Practice Guidelines is charged with developing, updating, and revising practice guidelines for cardiovascular diseases and procedures, and the Task Force directs and oversees this effort. Writing committees are charged with assessing the evidence as an independent group of authors to develop, update, or revise recommendations for clinical practice.

Experts in the subject under consideration have been selected from both organizations to examine subject-specific data and write guidelines in partnership with representatives from other medical practitioner and specialty groups. Writing committees are specifically charged to perform a formal literature review, weigh the strength of evidence for or against particular treatments or procedures, and include estimates of expected health outcomes where data exist. Patient-specific modifiers, comorbidities, and issues of patient preference that may influence the choice of tests or therapies are considered. When available, information from studies on cost is considered, but data on efficacy and clinical outcomes constitute the primary basis for recommendations in these guidelines.

The ACCF/AHA Task Force on Practice Guidelines makes every effort to avoid actual, potential, or perceived conflicts of interest that may arise as a result of industry relationships or personal interests among the writing committee. Specifically, all members of the writing committee, as well as peer reviewers of the document, are asked to disclose all current relationships and those 24 months prior to initiation of the writing effort that may be perceived as *relevant*. All guideline recommendations require a confidential vote by the writing committee and must be approved by a consensus of the members voting. Members who were recused from voting are noted on the title page of this document. Members must recuse themselves from voting on any recommendation where their relationships with industry (RWI) apply. If a writing committee member develops a new relationship with

industry during his/her tenure, he/she is required to notify guideline staff in writing. These statements are reviewed by the Task Force on Practice Guidelines and all members during each conference call and/or meeting of the writing committee, updated as changes occur, and ultimately published as an appendix to the document. For detailed information regarding guideline policies and procedures, please refer to the methodology manual for ACCF/AHA Guideline Writing Committees.<sup>1</sup> RWI and other entities pertinent to this guideline for authors and peer reviewers are disclosed in Appendixes 1 and 2, respectively. Disclosure information for the ACCF/AHA Task Force on Practice Guidelines is also available online at (<http://www.acc.org/about/overview/ClinicalDocumentsTaskForces.cfm>).

These practice guidelines are intended to assist healthcare providers in clinical decision making by describing a range of generally acceptable approaches for diagnosis, management, and prevention of specific diseases or conditions. Clinicians should consider the quality and availability of expertise in the area where care is provided. These guidelines attempt to define practices that meet the needs of most patients in most circumstances. The recommendations reflect a consensus after a thorough review of the available current scientific evidence and are intended to improve patient care. The Task Force recognizes that situations arise where additional data are needed to better inform patient care; these areas will be identified within each respective guideline when appropriate.

Patient adherence to prescribed and agreed upon medical regimens and lifestyles is an important aspect of treatment. Prescribed courses of treatment in accordance with these recommendations are effective only if they are followed. Because lack of patient understanding and adherence may adversely affect outcomes, physicians and other healthcare providers should make every effort to engage the patient's active participation in prescribed medical regimens and lifestyles.

If these guidelines are used as the basis for regulatory or payer decisions, the goal should be improvement in quality of care and aligned with the patient's best interest. The ultimate judgment regarding care of a particular patient must be made by the healthcare provider and the patient in light of all of the circumstances presented by that patient. Consequently, there are circumstances in which deviations from these guidelines are appropriate.

The guidelines will be reviewed annually by the ACCF/AHA Task Force on Practice Guidelines and considered current unless they are updated, revised, or withdrawn from distribution.

*Alice K. Jacobs, MD, FACC, FAHA  
Chair, ACCF/AHA Task Force on Practice Guidelines*

*Sidney C. Smith, Jr, MD, FACC, FAHA  
Immediate Past Chair, ACCF/AHA Task Force on  
Practice Guidelines*

## 1. Introduction

### 1.1. Methodology and Evidence Review

The writing committee conducted a comprehensive search of the medical and scientific literature through the use of

PubMed/MEDLINE. Searches were limited to publications written in the English language. Compiled reports were reviewed and additional articles were provided by committee members. Specifically targeted searches were conducted on the following subtopics: acute aortic dissection, ankylosing spondylitis, aortic dissection and litigation, aortic neoplasm, aortic tumors, Behçet disease, bicuspid aortic valve, calcified aorta, chronic dissection, coarctation of the aorta, D-dimer, dissecting aneurysm, Ehlers-Danlos syndrome, endovascular and aortic aneurysms, medial degeneration, porcelain aorta, giant cell arteritis, imaging and thoracic aortic disease, inflammatory disease, intramural hematoma, Loeys-Dietz syndrome, Marfan syndrome, Noonan syndrome, penetrating aortic ulcer, polycystic kidney disease, thoracic and aortic aneurysms, thoracic aortic disease and patient care, thoracic aortic disease and surgery, thoracic aorta and Kawasaki disease, Takayasu arteritis, thoracoabdominal and aorta or aortic disease, and Turner syndrome. More than 850 references were reviewed, with 830 used as the primary evidence base for the final guideline. The ACCF/AHA Task Force on Practice Guidelines methodology processes were followed to write the text and recommendations. In general, published manuscripts appearing in journals listed in Index Medicus were used as the evidence base. Published abstracts were used only for emerging information but were not used in the formulation of recommendations.

The committee reviewed and ranked evidence supporting current recommendations with the weight of evidence ranked as Level A if the data were derived from multiple randomized clinical trials or meta-analyses. The committee ranked available evidence as Level B when data were derived from a single randomized trial or nonrandomized studies. Evidence was ranked as Level C when the primary source of the recommendation was consensus opinion, case studies, or standard of care. In the narrative portions of these guidelines, evidence is generally presented in chronological order of development. Studies are identified as observational, retrospective, prospective, or randomized. For certain conditions for which inadequate data are available, recommendations are based on expert consensus and clinical experience and are ranked as Level C. An analogous example is the use of penicillin for pneumococcal pneumonia, where there are no randomized trials and treatment is based on clinical experience. When recommendations at Level C are supported by historical clinical data, appropriate references (including clinical reviews) are cited if available. For issues where sparse data are available, a survey of current practice among the clinicians on the writing committee formed the basis for Level C recommendations and no references are cited. The schema for classification of recommendations and level of evidence is summarized in Table 1, which also illustrates how the grading system provides an estimate of the size of the treatment effect and an estimate of the certainty of the treatment effect.

To provide clinicians with a comprehensive set of data, whenever possible, the exact event rates in various treatment arms of clinical trials are presented to permit calculation of the absolute risk difference (ARD), number needed to harm (NNH); the relative treatment effects are described either as

odds ratio (OR), relative risk (RR), or hazard ratio (HR) depending on the format in the original publication. Along with all other point statistics, confidence intervals (CIs) for those statistics are added when available.

The writing committee recognized that the evidence base for this guideline is less robust in terms of randomized clinical trials than prior ACCF/AHA guidelines, particularly those focused on coronary artery disease (CAD) and heart failure. As the reader will discern, much of the evidence base for this topic consists of cohort studies and retrospective reviews, which largely emanate from centers with a specialized interest in specific types of thoracic aortic disease. The writing committee attempted to focus on providing the practitioner with recommendations for evaluation and treatment wherever possible and where controversy exists, identified as such in the text.

The writing committee acknowledges the expertise of the highly experienced and effective practice guidelines staff of the ACCF and AHA. The writing committee chair also acknowledges the commitment and dedication of the diverse writing committee members who were able to put aside issues of specialty “turf” and focus on providing the medical community with a guideline aimed at optimal patient care.

## 1.2. Organization of the Writing Committee

The guideline was written by a committee comprised of experts in cardiovascular medicine, surgery, radiology, and nursing. For many of the previous ACCF/AHA practice guidelines, writing expertise has been available within these 2 organizations. Because of the broad scope and diversity of thoracic aortic diseases, as well as the specialists who treat such patients, the ACCF and AHA sought greater involvement from many specialty organizations. Most, but not all, specialty organizations that represent the major stakeholders caring for patients with thoracic aortic diseases provided writing committee members and financial support of the project, and they are recognized as marquee level partners with the ACCF and AHA. These organizations included the American Association for Thoracic Surgery (AATS), American College of Radiology (ACR), American Stroke Association (ASA), Society of Cardiovascular Anesthesiologists (SCA), Society of Cardiovascular Angiography and Interventions (SCAI), Society of Interventional Radiology (SIR), Society of Thoracic Surgeons (STS), and Society for Vascular Medicine (SVM). The American College of Emergency Physicians (ACEP) and the American College of Physicians (ACP) were also represented on the writing committee. Where additional expertise was needed, the scientific councils of the AHA were contacted for writing committee representatives. Representation was provided or facilitated by the Councils on Cardiovascular Nursing, Cardiovascular Surgery and Anesthesia, Cardiovascular Radiology and Intervention, and Clinical Cardiology, Council for High Blood Pressure Research, and Stroke Council.

## 1.3. Document Review and Approval

This document was reviewed by 3 outside reviewers nominated by the ACCF and 2 outside reviewers nominated by the AHA, as well as 1 or 2 reviewers from each of the following

**Table 1. Applying Classification of Recommendations and Level of Evidence**

		SIZE OF TREATMENT EFFECT <span style="float: right;">➔</span>			
		CLASS I <i>Benefit &gt;&gt;&gt; Risk</i> Procedure/Treatment <b>SHOULD</b> be performed/administered	CLASS IIa <i>Benefit &gt;&gt; Risk</i> <i>Additional studies with focused objectives needed</i> <b>IT IS REASONABLE</b> to perform procedure/administer treatment	CLASS IIb <i>Benefit ≥ Risk</i> <i>Additional studies with broad objectives needed; additional registry data would be helpful</i> Procedure/Treatment <b>MAY BE CONSIDERED</b>	CLASS III <i>Risk ≥ Benefit</i> Procedure/Treatment should <b>NOT</b> be performed/administered <b>SINCE IT IS NOT HELPFUL AND MAY BE HARMFUL</b>
ESTIMATE OF CERTAINTY (PRECISION) OF TREATMENT EFFECT	LEVEL A Multiple populations evaluated* Data derived from multiple randomized clinical trials or meta-analyses	<ul style="list-style-type: none"> <li>■ Recommendation that procedure or treatment is useful/effective</li> <li>■ Sufficient evidence from multiple randomized trials or meta-analyses</li> </ul>	<ul style="list-style-type: none"> <li>■ Recommendation in favor of treatment or procedure being useful/effective</li> <li>■ Some conflicting evidence from multiple randomized trials or meta-analyses</li> </ul>	<ul style="list-style-type: none"> <li>■ Recommendation's usefulness/efficacy less well established</li> <li>■ Greater conflicting evidence from multiple randomized trials or meta-analyses</li> </ul>	<ul style="list-style-type: none"> <li>■ Recommendation that procedure or treatment is not useful/effective and may be harmful</li> <li>■ Sufficient evidence from multiple randomized trials or meta-analyses</li> </ul>
	LEVEL B Limited populations evaluated* Data derived from a single randomized trial or nonrandomized studies	<ul style="list-style-type: none"> <li>■ Recommendation that procedure or treatment is useful/effective</li> <li>■ Evidence from single randomized trial or nonrandomized studies</li> </ul>	<ul style="list-style-type: none"> <li>■ Recommendation in favor of treatment or procedure being useful/effective</li> <li>■ Some conflicting evidence from single randomized trial or nonrandomized studies</li> </ul>	<ul style="list-style-type: none"> <li>■ Recommendation's usefulness/efficacy less well established</li> <li>■ Greater conflicting evidence from single randomized trial or nonrandomized studies</li> </ul>	<ul style="list-style-type: none"> <li>■ Recommendation that procedure or treatment is not useful/effective and may be harmful</li> <li>■ Evidence from single randomized trial or nonrandomized studies</li> </ul>
	LEVEL C Very limited populations evaluated* Only consensus opinion of experts, case studies, or standard of care	<ul style="list-style-type: none"> <li>■ Recommendation that procedure or treatment is useful/effective</li> <li>■ Only expert opinion, case studies, or standard of care</li> </ul>	<ul style="list-style-type: none"> <li>■ Recommendation in favor of treatment or procedure being useful/effective</li> <li>■ Only diverging expert opinion, case studies, or standard of care</li> </ul>	<ul style="list-style-type: none"> <li>■ Recommendation's usefulness/efficacy less well established</li> <li>■ Only diverging expert opinion, case studies, or standard of care</li> </ul>	<ul style="list-style-type: none"> <li>■ Recommendation that procedure or treatment is not useful/effective and may be harmful</li> <li>■ Only expert opinion, case studies, or standard of care</li> </ul>
Suggested phrases for writing recommendations†		should is recommended is indicated is useful/effective/beneficial	is reasonable can be useful/effective/beneficial is probably recommended or indicated	may/might be considered may/might be reasonable usefulness/effectiveness is unknown/unclear/uncertain or not well established	is not recommended is not indicated should not is not useful/effective/beneficial may be harmful

\*Data available from clinical trials or registries about the usefulness/efficacy in different subpopulations, such as sex, age, history of diabetes, history of prior myocardial infarction, history of heart failure, and prior aspirin use. A recommendation with Level of Evidence B or C does not imply that the recommendation is weak. Many important clinical questions addressed in the guidelines do not lend themselves to clinical trials. Even though randomized trials are not available, there may be a very clear clinical consensus that a particular test or therapy is useful or effective.

†In 2003, the ACCF/AHA Task Force on Practice Guidelines developed a list of suggested phrases to use when writing recommendations. All guideline recommendations have been written in full sentences that express a complete thought, such that a recommendation, even if separated and presented apart from the rest of the document (including headings above sets of recommendations), would still convey the full intent of the recommendation. It is hoped that this will increase readers' comprehension of the guidelines and will allow queries at the individual recommendation level.

organizations: the AATS, ACP, ACEP, ACR, ASA, SCA, SCAI, SIR, STS, and the SVM. It was also reviewed by 6 individual content reviewers—2 content reviewers from the ACCF Catheterization Committee and 1 content reviewer from the ACCF Interventional Council. All reviewer RWI information was collected and distributed to the writing committee and is published in this document (see Appendix 2).

This document was approved for publication by the governing bodies of the ACCF and the AHA and the AATS, ACEP, ACR, ASA, SCA, SCAI, SIR, STS, and SVM and was endorsed by the North American Society for Cardiovascular Imaging.

#### 1.4. Scope of the Guideline

The term “thoracic aortic disease” encompasses a broad range of degenerative, structural, acquired, genetic-based, and trau-

matic disease states and presentations. According to the Centers for Disease Control and Prevention death certificate data, diseases of the aorta and its branches account for 43 000 to 47 000 deaths annually in the United States.<sup>2</sup> The precise number of deaths attributable to thoracic aortic diseases is unclear. However, autopsy studies suggest that the presentation of thoracic aortic disease is often death due to aortic dissection (AoD) and rupture, and these deaths account for twice as many deaths as attributed to ruptured abdominal aortic aneurysms (AAAs).<sup>3</sup> The diagnosis of acute thoracic AoD or rupture is often difficult and delayed, and errors in diagnosis may account for deaths otherwise attributed to cardiac arrhythmia, myocardial infarction (MI), pulmonary embolism, or mesenteric ischemia.

The University HealthSystem Consortium (UHC) is an alliance of more than 100 academic medical centers and

**Table 2A. ICD-9 Procedure Codes For Aortic Aneurysms**

Aortic Aneurysm Category	Dissection	Ruptured	No Mention of Rupture
Thoracic	441.01	441.1	441.2
Abdominal	441.02	441.3	441.4
Thoracoabdominal	441.03	441.6	441.7
Aortic (unspecified)	441.00	441.5	441.9

Table courtesy of UHC Clinical DataBase/Resource Manager.

affiliate hospitals. UHC’s Clinical DataBase/Resource Manager allows comparison of patient-level risk-adjusted outcomes for performance improvement. The UHC provided the writing committee with a summary of recent information based on ICD-9 codes for thoracic aortic disease-related hospitalizations from the Clinical DataBase/Resource Manager (Tables 2A and 2B). This data table demonstrates a high number of hospital discharges (more than 135 000) for thoracic, abdominal, thoracoabdominal, and “unspecified” aortic aneurysms in the 5-year period between 2002 and

2007. Subcategories include those with dissection, those with rupture, and those with neither. In the most recent 1-year period assessed (fourth quarter 2006 through third quarter 2007), there were nearly 9000 cases representing all patients with thoracic aortic disease discharged from UHC hospitals. Although these data are unavailable for the entire United States, they provide important estimates of the magnitude of the prevalence of thoracic aortic disease. Additional information regarding the patient admission source, particularly those with acute presentations, is pertinent to the discussion regarding interinstitutional transfer (see Section 17.2).

Most patients with significant thoracic aortic disease will be directed to specialized practitioners and institutions. However, the importance of early recognition and prompt treatment and/or referral for various thoracic aortic diseases by all health-care professionals provides the rationale for this document. This guideline will attempt to provide the practitioner with a sufficient description of background information, diagnostic modalities, and treatment strategies so that appropriate care of these patients can be facilitated and better understood. The goal of this

**Table 2B. Number of Discharges by Year by Category of Aortic Aneurysm Among Academic Medical Centers Reporting Data to the UHC Clinical Database\***

Aortic Aneurysm Category	2002q4–2003q3	2003q4–2004q3	2004q4–2005q3	2005q4–2006q3	2006q4–2007q3	5-Year Total	Category % Distribution	% of All Categories
<b>Thoracic</b>								25.9
Dissection	1607	1683	2028	2321	2355	9994	28.5	
Ruptured	187	225	219	234	251	1116	3.2	
No mention of rupture	3086	4026	4953	5730	6156	23 954	68.3	
Subtotal	4880	5934	7200	8285	8762	35 064		
<b>Abdominal</b>								62.7
Dissection	553	630	747	867	867	3664	4.3	
Ruptured	651	657	720	734	702	3464	4.1	
No mention of rupture	12 075	13 280	15 882	17 818	18 683	77 738	91.6	
Subtotal	13 279	14 567	17 349	19 419	20 252	84 866		
<b>Thoracoabdominal</b>								8.3
Dissection	583	587	674	755	834	3433	30.5	
Ruptured	150	129	110	157	127	673	6.0	
No mention of rupture	1091	1183	1472	1621	1773	7140	63.5	
Subtotal	1824	1899	2256	2533	2734	11 246		
<b>Aortic (unspecified)</b>								3.0
Dissection	223	310	326	343	339	1541	37.6	
Ruptured	9	3	15	9	9	45	1.1	
No mention of rupture	310	385	505	612	701	2513	61.3	
Subtotal	542	698	846	964	1049	4099		
<b>Total No. of cases</b>	20 525	23 098	27 651	31 201	32 797	135 275		
<b>Total No. of inpatient discharges</b>	2 679 334	2 777 880	3 018 141	3 222 542	3 297 834	14 995 731		

UHC indicates University HealthSystem Consortium.

\*Note: Year-to-year increases are due in part to changes in number of reporting hospitals.

Table courtesy of UHC Clinical DataBase/Resource Manager.



guideline is to improve the health outcomes and quality of life for all patients with thoracic aortic disease.

Other practice guidelines developed by ACCF and AHA address the management of patients with cardiac and vascular diseases. The ACCF/AHA guidelines on peripheral arterial disease<sup>4</sup> include recommendations for lower extremity, renal, mesenteric, and abdominal aortic diseases. Data standards on this topic are currently in development, as is a practice guideline on extracranial carotid and vertebral artery diseases. The ACCF/AHA guidelines are published in the *Journal of the American College of Cardiology* and *Circulation* and are available on both the ACC ([www.acc.org](http://www.acc.org)) and AHA ([my.americanheart.org](http://my.americanheart.org)) Web sites.

This guideline includes diseases involving any or all parts of the thoracic aorta with the exception of aortic valve diseases<sup>5</sup> and includes the abdominal aorta when contiguous thoracic aortic diseases are present. Specific disease states are described in the following sections, and the reader is referred to the glossary of terminology in Section 1.5 and Appendix 3 for abbreviations used throughout the guideline.

The reader will note that several topics or referenced areas may appear more than once throughout the guideline. This will appear to be redundant to those who choose to read the entire document, but the writing committee believed that because of the multidisciplinary nature of and organizational involvement in this project, individuals representing specific disciplines may choose to read and extract portions of the document for their own use. Inclusion of the narrative text and references was thought to be appropriate to facilitate a more complete understanding for these disciplines and individuals. Accordingly, the organization of the guideline is meant to be less of a textbook presentation of the various topics but rather a more clinically oriented document applicable to a variety of disciplines.

#### 1.4.1. Critical Issues

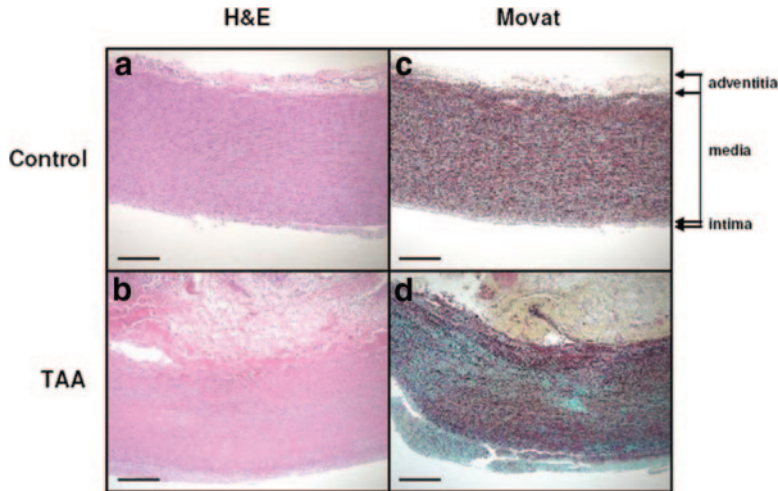
As the writing committee developed this guideline, several critical issues emerged:

- Thoracic aortic diseases are usually asymptomatic and not easily detectable until an acute and often catastrophic complication occurs. Imaging of the thoracic aorta with computed tomographic imaging (CT), magnetic resonance imaging (MR), or in some cases, echocardiographic examination is the only method to detect thoracic aortic diseases and determine risk for future complications (see Section 4).
- Radiologic imaging technologies have improved in terms of accuracy of detection of thoracic aortic disease. However, as the use of these technologies has increased, so also has the potential risk associated with repeated radiation exposure, as well as contrast medium–related toxicity. Whether these technologies should be used repeatedly as a widespread screening tool is discussed in Section 4. In addition, the writing committee formulated recommendations on a standard reporting format for thoracic aortic findings as discussed in Section 4.5.
- Imaging for asymptomatic patients at high risk based on history or associated diseases is expensive and not always covered by payers.
- For many thoracic aortic diseases, results of treatment for stable, often asymptomatic, but high-risk conditions are far better than the results of treatment required for acute and often catastrophic disease presentations. Thus, the identification and treatment of patients at risk for acute and catastrophic disease presentations (eg, thoracic AoD, thoracic aneurysm rupture) prior to such an occurrence are paramount to eliminating the high morbidity and mortality associated with acute presentations (see Section 8.1).
- A subset of patients with acute AoD are subject to missed or delayed detection of this catastrophic disease state. Many present with atypical symptoms and findings, making diagnosis even more difficult (see Sections 8.1.4 and 8.6). This issue has come under greater medical-legal scrutiny, and specific cases have been widely discussed in the public domain. Widespread awareness of the varied and complex nature of thoracic aortic disease presentations has been lacking, especially for acute AoD. Risk factors and clinical presentation clues are noted in Section 8.1.4. The collaboration and cosponsorship of multiple medical specialties in the writing of this guideline will provide unique opportunities for widespread dissemination of knowledge to raise the level of awareness among all medical specialties.
- There is rapidly accumulating evidence that genetic alterations or mutations predispose some individuals to aortic diseases (see Section 5). Therefore, identification of the genetic alterations leading to these aortic diseases has the potential for early identification of individuals at risk. In addition, biochemical abnormalities involved in the progression of aortic disease are being identified through studies of patients' aortic samples and animal models of the disease.<sup>6,7</sup> The biochemical alterations identified in the aortic tissue have the potential to serve as biomarkers for aortic disease. Understanding the molecular pathogenesis may lead to targeted therapy to prevent aortic disease. Medical and gene-based treatments are beginning to show promise for reducing or delaying catastrophic complications of thoracic aortic diseases (see Section 9.2).
- As noted in Section 18, there are several areas where greater resources for research and both short- and long-term outcomes registries are needed.

## 1.5. Glossary of Terms and Abbreviations Used Throughout Guideline

**Aneurysm (or true aneurysm):** a permanent localized dilatation of an artery, having at least a 50% increase in diameter compared with the expected normal diameter of the artery in question. Although all 3 layers (intima, media, and adventitia) may be present, the intima and media in large aneurysms may be so attenuated that in some sections of the wall they are undetectable.

**Pseudoaneurysm (or false aneurysm):** contains blood resulting from disruption of the arterial wall with extravasation of blood contained by periarterial connective tissue and not by the arterial wall layers (see Section 8.4). Such an extravascular hematoma that freely communicates with the intravascular space is also known as a pulsating hematoma.<sup>8–10</sup>



**Figure 1.** Aortic pathology associated with thoracic aortic aneurysm involving the ascending aorta. All panels are identically oriented with the adventitia at the top and the intima at the bottom. H&E staining of aortic sections from a control (a) and a patient (b) with a TAA demonstrates medial degeneration with the fragmentation of elastic fibers, accumulation of proteoglycans, and regions of smooth muscle cell loss. Movat staining of aortic sections from control (c) and patient with an aneurysm (d) shows fragmentation of elastic fibers (stained black), loss of smooth muscle cells (cells stained red and nuclei stained violet), and accumulation of proteoglycans (stained blue) in the medial layer. 40× magnification; scale bars represent 500 mcg. H&E indicates hematoxylin and eosin; and TAA, thoracic aortic aneurysm. Modified from Milewicz et al.<sup>11</sup>

**Ectasia:** arterial dilatation less than 150% of normal arterial diameter.

**Arteriomegaly:** diffuse arterial dilatation involving several arterial segments with an increase in diameter greater than 50% by comparison to the expected normal arterial diameter.

**Thoracoabdominal aneurysm (TAA):** aneurysm involving the thoracic and abdominal aorta (see Section 9.2.2.3).

**Abdominal aortic aneurysm (AAA):** aneurysm involving the infradiaphragmatic abdominal aorta.

**Aortic dissection (AoD):** disruption of the media layer of the aorta with bleeding within and along the wall of the aorta. Dissection may, and often does, occur without an aneurysm being present. An aneurysm may, and often does, occur without dissection. The term “dissecting aortic aneurysm” is often used incorrectly and should be reserved only for those cases where a dissection occurs in an aneurysmal aorta (see Section 8.1).

## 2. The Thoracic Aorta

### 2.1. The Normal Aorta

The thoracic aorta is divided into 4 parts: the aortic root (which includes the aortic valve annulus, the aortic valve cusps, and the sinuses of Valsalva); the ascending aorta (which includes the tubular portion of the ascending aorta beginning at the sinotubular junction and extending to the brachiocephalic artery origin); the aortic arch (which begins at the origin of the brachiocephalic artery and is the origin of the head and neck arteries, coursing in front of the trachea and to the left of the esophagus and the trachea); and the descending aorta (which begins at the isthmus between the origin of the left subclavian artery and the ligamentum arteriosum and courses anterior to the vertebral column, and then through the diaphragm into the abdomen).

The normal human adult aortic wall is composed of 3 layers, listed from the blood flow surface outward (Figure 1):

**Intima:** endothelial layer on a basement membrane with minimal ground substance and connective tissue.

**Media:** bounded by an internal elastic lamina, a fenestrated sheet of elastic fibers; layers of elastic fibers arranged concentrically with interposed smooth muscle cells;

bounded by an external elastic lamina, another fenestrated sheet of elastic fibers.

**Adventitia:** resilient layer of collagen containing the vasa vasorum and nerves. Some of the vasa vasorum can penetrate into the outer third of the media.

### 2.2. Normal Thoracic Aortic Diameter

In 1991, the Society for Vascular Surgery created a table (Table 3) describing the normal diameter of the adult thoracic aorta based on CT and chest x-ray.<sup>12</sup>

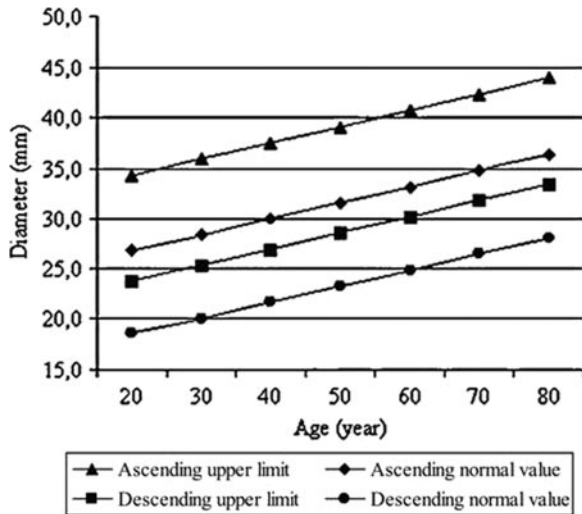
Since then, it has been recognized that the “normal aortic diameter” is influenced by a number of factors, including patient age, sex, and body size; location of aortic measurement; method of measurement; and the robustness and type of imaging methods used. Hannuksela et al<sup>13</sup> noted that diameter increased by 0.12 to 0.29 mm/y at each level measured by CT for 41 men and 36 women aged 18 to 82 years (Figure 2). Aortic diameter for men was larger than that for women, but the difference decreased with age. Body mass index also affected aortic diameter by 0.27 mm (0.14 to 0.44 mm) per unit of body mass index.<sup>13</sup>

Aortic diameter gradually tapers downstream from the sinuses of Valsalva. Hager et al<sup>14</sup> examined 46 men and 24

**Table 3. Normal Adult Thoracic Aortic Diameters**

Thoracic Aorta	Range of Reported Mean (cm)	Reported SD (cm)	Assessment Method
Root (female)	3.50 to 3.72	0.38	CT
Root (male)	3.63 to 3.91	0.38	CT
Ascending (female, male)	2.86	NA	CXR
Mid-descending (female)	2.45 to 2.64	0.31	CT
Mid-descending (male)	2.39 to 2.98	0.31	CT
Diaphragmatic (female)	2.40 to 2.44	0.32	CT
Diaphragmatic (male)	2.43 to 2.69	0.27 to 0.40	CT, arteriography

CT indicates computed tomographic imaging; CXR, chest x-ray; and NA, not applicable. Reprinted with permission from Johnston et al.<sup>12</sup>



**Figure 2.** Normal diameter and upper limit of ascending and descending aorta related to age. Reprinted with permission from Hannuksela et al.<sup>13</sup>

women without cardiovascular disease (age range 1 to 89 years; mean age 50.2 years) using helical CT (Figure 3). For these patients, there was no correlation with weight, height, or body surface area, but aortic diameter increased with age and was larger for men than for women.<sup>14</sup>

Two-dimensional echocardiography has been used to define the “normal” range for aortic diameter at the sinuses of Valsalva in different age categories (and stratified by body surface area).<sup>15</sup> Adjusting for 2 of the key determinants of aortic diameter allows a more precise characterization of aortic size in otherwise healthy individuals<sup>15</sup> (Figure 4). Again, age and sex affected aortic root diameter, but the influence of sex was neutralized when diameter was indexed to body surface area (Table 4).

These tables and definitions help define the presence or absence of a thoracic aortic aneurysm and help define the threshold for considering further treatment for such patients. However, patients with certain genetic syndromes and abnormal tissue morphology may in fact have a normal aortic diameter at the time of acute AoD rupture (see Section 5.1.2). Another challenge relates to abnormal morphology of one aortic segment compared with another. For example, if the diameter of the

ascending aorta exceeds the diameter of the aorta at the level of the sinuses Valsalva, even if both are within normal range, then the ascending aorta is considered to be enlarged. To adjust for body habitus variation, the use of aortic diameter indexed to height has been reported to better indicate surgical timing than might be recommended from aortic diameter alone for an otherwise asymptomatic patient with Marfan syndrome or bicuspid aortic valve.<sup>16</sup> Whenever possible, the writing committee has inserted aortic diameter thresholds for further action, whether the action is for continued surveillance or for endovascular or surgical intervention.

### 3. Thoracic Aortic Histopathology

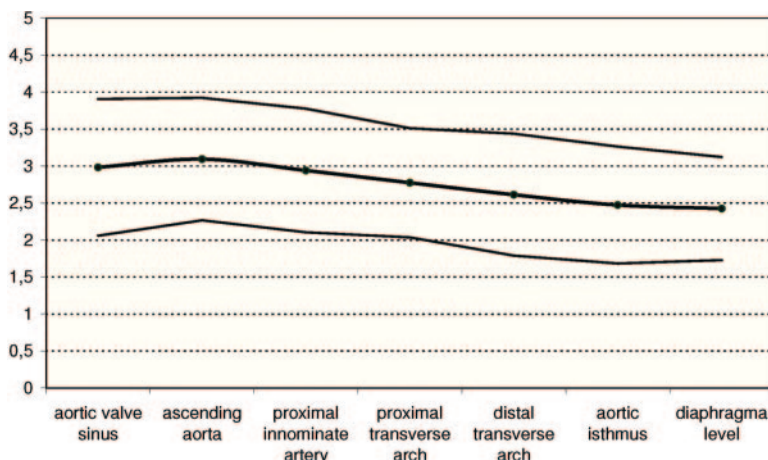
#### 3.1. Atherosclerosis

Atherosclerosis is characterized by intimal lesions called atheromata, or atheromatous or fibrofatty plaques, which protrude into the arterial lumen and weaken the underlying media often associated with calcification. With aging, presence of risk factors, and genetic predisposition, this progresses to complicated lesions with surface defects, hemorrhage, and/or thrombosis. A 1995 consensus document from the AHA defines the types and histologic classes of atherosclerosis<sup>17</sup> (Figure 5).

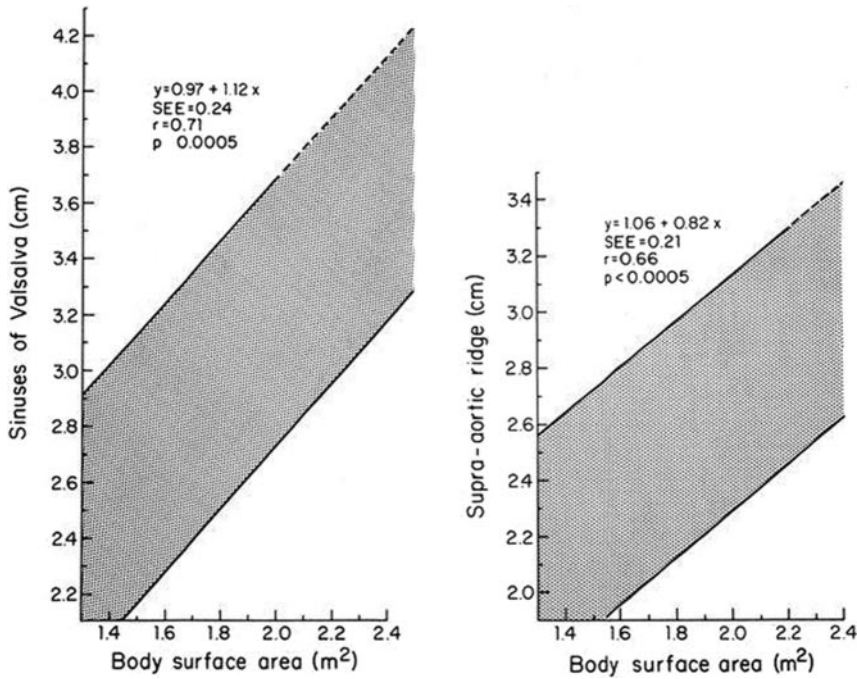
Thoracic aortic atherosclerosis is less common than abdominal aortic atherosclerosis, but the clinical importance is great. Clinical presentations and problems associated with aortic atherosclerosis and atheroma are discussed extensively in Section 11.

#### 3.2. Aneurysms and Dissections

The pathology associated with thoracic aortic aneurysms and dissections was initially termed cystic medial necrosis but this term is a misnomer; the disease is not associated with necrosis of the aorta or with cyst formation. Aortic aneurysm histopathology, more accurately termed medial degeneration, is characterized by disruption and loss of elastic fibers and increased deposition of proteoglycans (Figure 1). Typically, there are areas of loss of smooth muscle cells in the aortic media, but whether there is a total loss of smooth muscle cells in the aortic wall is not clear. There can be atherosclerosis lesions present, but again, these changes are typically superimposed on medial degenerative disease. Although medial degeneration was initially described as a noninflammatory



**Figure 3.** Mean aortic diameters (in cm) at various levels measured by helical CT in 70 adults. Thin lines represent  $\pm 2$  SDs, representing 95% reference area. CT indicates computed tomographic imaging; and SD, standard deviation. Reprinted with permission from Hager et al.<sup>14</sup>



**Figure 4.** Sinus of Valsalva diameter, by body surface area. Left, The 95% normal confidence limits for aortic root diameter at the sinuses of Valsalva in relation to body surface area in adults <40 years of age. Right, The 95% normal confidence limits for the proximal ascending aortic diameter in relation to body surface area in adults <40 years of age. SEE indicates standard error of the estimate. Reprinted with permission from Roman et al.<sup>15</sup>

disease, recent literature supports the presence of inflammatory cell infiltration in this disease.<sup>18,19</sup>

The biochemical pathways and proteins involved with medial degeneration have not been clearly delineated. However, multiple studies have found increased immunostaining for a subset of matrix metalloproteinases (MMPs) in the media of thoracic aortic aneurysms, particularly MMP-2 and MMP-9.<sup>20–23</sup> Immunostaining of aortic media from patients with Marfan syndrome has demonstrated increases in MMP-2 and MMP-9, which were associated with smooth muscle cells at the borders of areas of medial degeneration and on the surface of disrupted elastic fibers. Elevated MMP-2 and MMP-9 immunostaining has been demonstrated in ascending aneurysms from patients with either tricuspid or bicuspid aortic valves<sup>21,23</sup> and inconsistently in ascending aortic tissue from patients with tricuspid aortic valves.<sup>22</sup> These 2 MMPs are known to have elastolytic activity. Variable expression of MMPs and tissue inhibitors of MMPs has also been demonstrated in aortic tissue of patients with Marfan syndrome versus patients without Marfan syndrome.<sup>24</sup> Although accumulation of proteoglycans in the aortic media is another consistent finding in thoracic aortic aneurysms, no studies have determined why this accumulation occurs or whether these are causative in nature.

Medial degeneration is also associated with focal loss of vascular smooth muscle cells. Although there are regions of

smooth muscle cell loss, morphometric analysis of aortic tissue has suggested that hyperplastic cellular remodeling of the media in ascending thoracic aortic aneurysms may be an initial adaptive response to minimize increased wall stress resulting from vascular dilatation.<sup>25</sup> More recent studies of the aortic pathology associated with myosin heavy chain 11, smooth muscle (*MYH11*), and actin, alpha 2, smooth muscle aorta (*ACTA2*) mutations leading to ascending aortic aneurysms demonstrate a hyperplastic response by smooth muscle cells in the aortic media. The aortic media in aneurysm tissue taken from patients harboring mutations in these genes demonstrated focal hyperplasia associated with smooth muscle cells that were remarkable for a lack of structured orientation parallel to the lumen of the aorta, but instead, the smooth muscle cells were oriented randomly with respect to one another.<sup>26,27</sup>

### 3.3. Vasculitis and Inflammatory Diseases

A variety of inflammatory vasculitides may also result in thoracic aortic disease. These include giant cell arteritis (GCA), Takayasu arteritis, and Behçet disease (see Section 7). The pathophysiology of GCA shares important features with Takayasu arteritis.<sup>28</sup> T-cell clonal expansion suggests a specific antigenic response, which currently remains unelucidated. The inflammatory response, which begins in the

**Table 4. Sex Differences in Aortic Root Dimensions in Adults**

Aortic Root	Absolute Values (cm)		P Value	Indexed Values (cm/m <sup>2</sup> )		P Value	Women
	Men	Women		Men	Women		
Annulus	2.6±0.3	2.3±0.2	<0.001	1.3±0.1	1.3±0.1	NS	1.3±0.1
Sinuses of Valsalva	3.4±0.3	3.0±0.3	<0.001	1.7±0.2	1.7±0.2	NS	1.8±0.2
Sinotubular junction	2.9±0.3	2.6±0.3	<0.001	1.5±0.2	1.5±0.2	NS	1.5±0.2
Proximal ascending aorta	3.0±0.4	2.7±0.4	<0.001	1.5±0.2	1.5±0.2	NS	1.6±0.3

NS indicates not significant. Adapted from Roman et al.<sup>15</sup>

Nomenclature and main histology	Sequences in progression	Main growth mechanism	Earliest onset	Clinical correlation
<b>Type I (initial) lesion</b> isolated macrophage foam cells	<pre> graph TD     I((I)) --&gt; II((II))     II --&gt; III((III))     III --&gt; IV((IV))     IV --&gt; V((V))     V --&gt; VI((VI))     VI --&gt; V     V --&gt; IV             </pre>	growth mainly by lipid accumulation	from first decade	clinically silent
<b>Type II (fatty streak) lesion</b> mainly intracellular lipid accumulation			from third decade	
<b>Type III (intermediate) lesion</b> Type II changes & small extracellular lipid pools				
<b>Type IV (atheroma) lesion</b> Type II changes & core of extracellular lipid		accelerated smooth muscle and collagen increase	from fourth decade	clinically silent or overt
<b>Type V (fibroatheroma) lesion</b> lipid core & fibrotic layer, or multiple lipid cores & fibrotic layers, or mainly calcific, or mainly fibrotic				
<b>Type VI (complicated) lesion</b> surface defect, hematoma-hemorrhage, thrombus		thrombosis, hematoma		

**Figure 5.** Atherosclerotic lesions. Flow diagram in center column indicates pathways in evolution and progression of human atherosclerotic lesions. Roman numerals indicate histologically characteristic types of lesions defined at the left of the flow diagram. The direction of the arrows indicates the sequence in which characteristic morphologies may change. From Type I to Type IV, changes in lesion morphology occur primarily because of increasing accumulation of lipid. The loop between Types V and VI illustrates how lesions increase in thickness when thrombotic deposits form on their surfaces. Thrombotic deposits may form repeatedly over varied time spans in the same location and may be the principal mechanism for gradual occlusion of medium-sized arteries. Adapted from Stary et al.<sup>17</sup>

adventitial layer, is marked by augmented cytokine and MMP production causing granuloma formation. Granuloma formation both shields the vessel from the inciting antigen and causes vessel destruction.<sup>29</sup> Behçet disease is a vasculitis affecting both arteries and veins, of all sizes.

#### 4. Imaging Modalities

##### 4.1. Recommendations for Aortic Imaging Techniques to Determine the Presence and Progression of Thoracic Aortic Disease

###### Class I

1. Measurements of aortic diameter should be taken at reproducible anatomic landmarks, perpendicular to the axis of blood flow, and reported in a clear and consistent format (see Table 5). (Level of Evidence: C)
2. For measurements taken by computed tomographic imaging or magnetic resonance imaging, the external diameter should be measured perpendicular to the axis of blood flow. For aortic root measurements, the widest diameter, typically at the mid-sinus level, should be used. (Level of Evidence: C)
3. For measurements taken by echocardiography, the internal diameter should be measured perpendicular to the axis of blood flow. For aortic root measurements, the widest diameter, typically at the mid-sinus level, should be used. (Level of Evidence: C)
4. Abnormalities of aortic morphology should be recognized and reported separately even when aortic diameters are within normal limits. (Level of Evidence: C)
5. The finding of aortic dissection, aneurysm, traumatic injury and/or aortic rupture should be immediately communicated to the referring physician. (Level of Evidence: C)

##### 6. Techniques to minimize episodic and cumulative radiation exposure should be utilized whenever possible.<sup>30,31</sup> (Level of Evidence: B)

###### Class IIa

1. If clinical information is available, it can be useful to relate aortic diameter to the patient's age and body size. (Level of Evidence: C)

Definitive identification or exclusion of thoracic aortic disease or one of its anatomic variants requires dedicated aortic

**Table 5. Essential Elements of Aortic Imaging Reports**

1. The location at which the aorta is abnormal (see Section 2).
2. The maximum diameter of any dilatation, measured from the external wall of the aorta, perpendicular to the axis of flow, and the length of the aorta that is abnormal.
3. For patients with presumed or documented genetic syndromes at risk for aortic root disease measurements of aortic valve, sinuses of Valsalva, sinotubular junction, and ascending aorta.
4. The presence of internal filling defects consistent with thrombus or atheroma.
5. The presence of IMH, PAU, and calcification.
6. Extension of aortic abnormality into branch vessels, including dissection and aneurysm, and secondary evidence of end-organ injury (eg, renal or bowel hypoperfusion).
7. Evidence of aortic rupture, including periaortic and mediastinal hematoma, pericardial and pleural fluid, and contrast extravasation from the aortic lumen.
8. When a prior examination is available, direct image to image comparison to determine if there has been any increase in diameter.

IMH indicates intramural hematoma; and PAU, penetrating atherosclerotic ulcer.

imaging. Selection of the most appropriate imaging study may depend on patient-related factors (ie, hemodynamic stability, renal function, contrast allergy) and institutional capabilities (ie, rapid availability of individual imaging modalities, state of the technology, and imaging specialist expertise). Consideration should be given to patients with borderline abnormal renal function (serum creatinine greater than 1.8 to 2.0 mg/dL)—specifically, the tradeoffs between the use of iodinated intravenous contrast for CT and the possibility of contrast-induced nephropathy, and gadolinium agents used with MR and the risk of nephrogenic systemic fibrosis.<sup>32</sup>

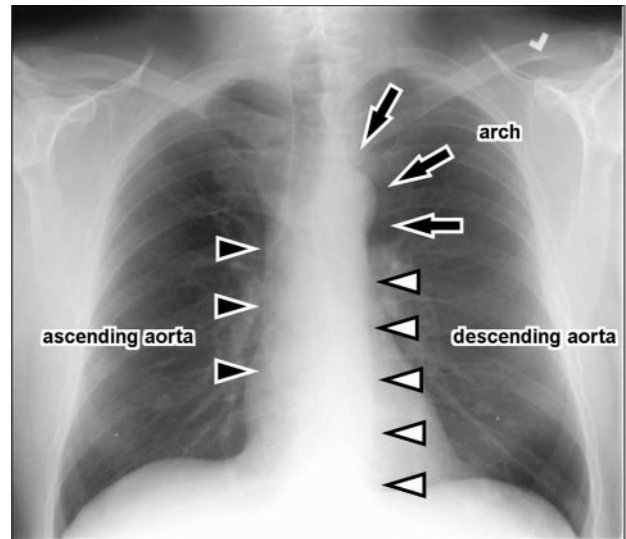
Radiation exposure should be minimized.<sup>31,33–36</sup> The risk of radiation-induced malignancy is the greatest in neonates, children, and young adults.<sup>31</sup> Generally, above the age of 30 to 35 years, the probability of radiation-induced malignancy decreases substantially.<sup>30,31</sup> For patients who require repeated imaging to follow an aortic abnormality, MR may be preferred to CT. MR may require sedation due to longer examination times and tendency for claustrophobia.

CT as opposed to echocardiography can best identify thoracic aortic disease, as well as other disease processes that can mimic aortic disease, including pulmonary embolism, pericardial disease, and hiatal hernia. After intervention or open surgery, CT is preferred to detect asymptomatic post-procedural leaks or pseudoaneurysms because of the presence of metallic closure devices and clips.

We recommend that external aortic diameter be reported for CT or MR derived size measurements. This is important because lumen size may not accurately reflect the external aortic diameter in the setting of intraluminal clot, aortic wall inflammation, or AoD. A recent refinement in the CT measurement of aortic size examines the vessel size using a centerline of flow, which reduces the error of tangential measurement and allows true short-axis measurement of aortic diameter. In contrast to tomographic methods, echocardiography-derived sizes are reported as internal diameter size. In the ascending aorta, where mural thrombus in aneurysms is unusual, the discrepancy between the internal and external aortic diameters is less than it is in the descending or abdominal aorta, where mural thrombus is common. Standardization of aortic diameter measurements is important to the planning of endovascular treatment of an aneurysm, where the diameter of the aorta in the seal zone must be matched to the diameter of an endograft. Here, the choice of internal or external diameter is specified by the manufacturer of the endograft.

#### 4.2. Chest X-Ray

Routine chest x-ray may occasionally detect abnormalities of aortic contour or size that require definitive aortic imaging. Chest x-ray often serves as a part of the evaluation of patients with potential acute AoD, primarily to identify other causes of patient's symptoms, but also as a screening test to identify findings due to a dilated aorta or bleeding. However, chest x-ray is inadequately sensitive to definitively exclude the presence of AoD in all except the lowest-risk patients and therefore rarely excludes the disease. Pooled data from 10 studies places the predictive sensitivity of a widened medi-



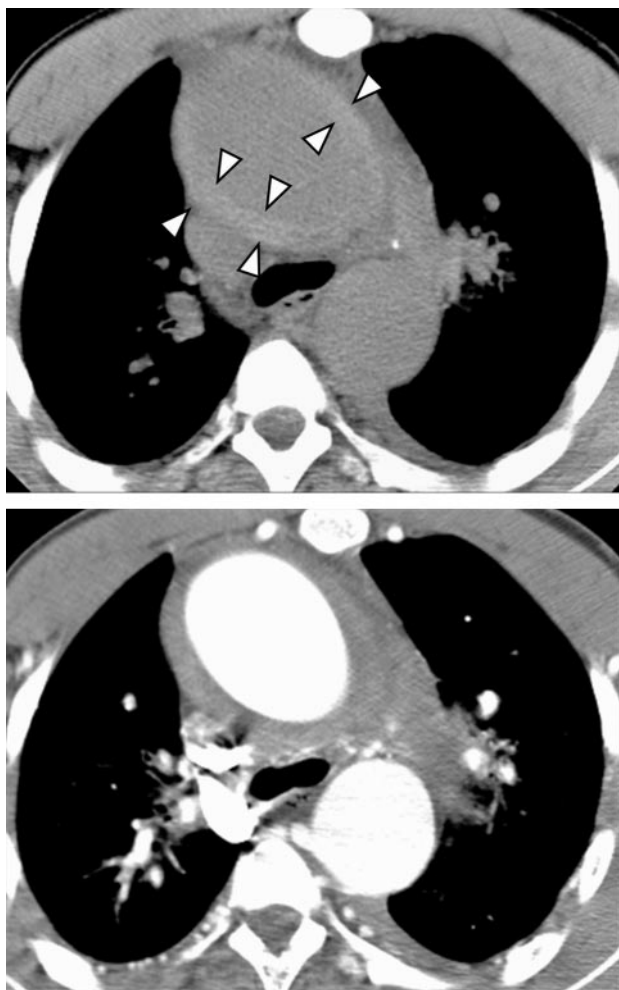**Figure 6.** Chest x-ray of a normal thoracic aorta. Arrows indicate arch, and arrowheads show ascending and descending aorta.

astinum or an abnormal aortic contour associated with significant thoracic aortic disease at 64% and 71%, respectively.<sup>37</sup> In the same analysis, however, including all abnormal radiographic findings increased the sensitivity to 90%, suggesting that a completely normal chest x-ray does lower the likelihood of AoD and may provide meaningful clinical information in very low-risk patients.<sup>37</sup> The presence of a widened mediastinum or other radiographic findings suggestive of thoracic aortic disease increases the likelihood of AoD, particularly among patients who lack a clear alternative source for their symptoms. In a blinded prospective study of 216 patients who underwent evaluation for acute thoracic aortic disease, the specificity of chest x-ray for aortic pathology was 86%.<sup>38</sup>

For patients with chest trauma, chest x-ray is a poor screening test for the diagnosis of aortic injury.<sup>39–41</sup> A sharply demarcated normal mediastinal contour is sometimes used to exclude mediastinal hematoma (suggesting a wide mediastinum, abnormal mediastinal contour, left apical cap, loss of the aortic knob, depression of the left main bronchus, and deviation of an indwelling esophageal tube). However, these signs of hemomediastinum are more often false positive than true positive for aortic injury.<sup>40</sup> Figure 6 illustrates the normal appearance of the thoracic aorta, and its components, on a posteroanterior chest x-ray.

#### 4.3. Computed Tomographic Imaging

CT scanning has been used for more than 2 decades to identify acute AoD and to diagnose and measure other thoracic aortic diseases<sup>42</sup> (see Section 5.1). Advantages include near universal availability—the ability to image the entire aorta, including lumen, wall, and periaortic regions; to identify anatomic variants and branch vessel involvement; and to distinguish among types of acute aortic syndromes (ie, intramural hematoma [IMH], penetrating atherosclerotic ulcer [PAU], and acute AoD)—and the short time required to complete the imaging process and the 3-dimensional data. Electro-

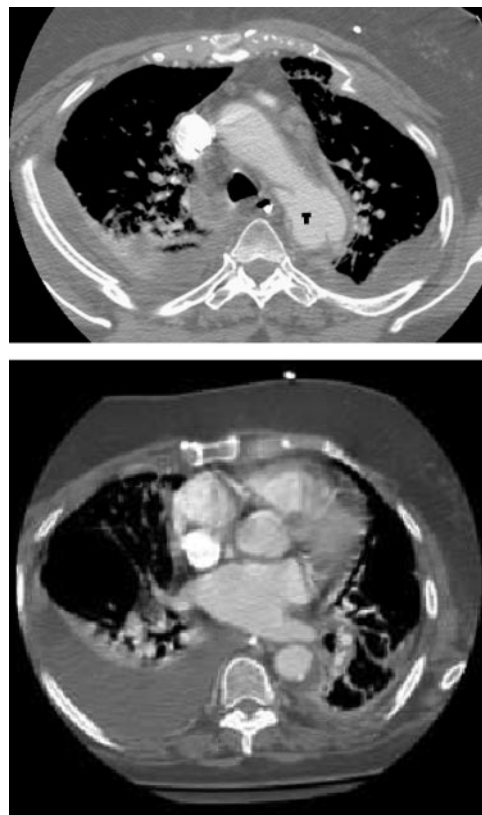


**Figure 7.** Axial CT images demonstrating the value of noncontrast images. Top, Precontrast image demonstrates a high-attenuation aortic hematoma indicating an acute aortic event. Bottom, Images obtained with intravenous contrast material demonstrate the contrast-filled aortic lumen and the hematoma as a relatively lower attenuation band. CT indicates computed tomographic imaging.

cardiogram (ECG)-gated techniques have made it possible to generate motion-free images of the aortic root and coronary arteries, similar to coronary CT angiographic imaging.

Reports of newer-generation multidetector helical CT scanners show sensitivities of up to 100% and specificities of 98% to 99%.<sup>43–46</sup> Data from the International Registry of Acute Aortic Dissection (IRAD) show that for patients with aortic dissection, CT was the initially used diagnostic modality in 61% of patients and transthoracic echocardiography (TTE) and/or transesophageal echocardiography (TEE) was used first in 33% of patients. Whether this was because the first test was insufficient to diagnose dissection or because additional information about cardiac and aortic valve function was required is unclear.<sup>47</sup>

The sequence for CT performed in the potential setting of acute AoD generally would include a noncontrast study to detect subtle changes of IMH (Figure 7), followed by a contrast study to delineate the presence and extent of the dissection flap, identify regions of potential malperfusion,



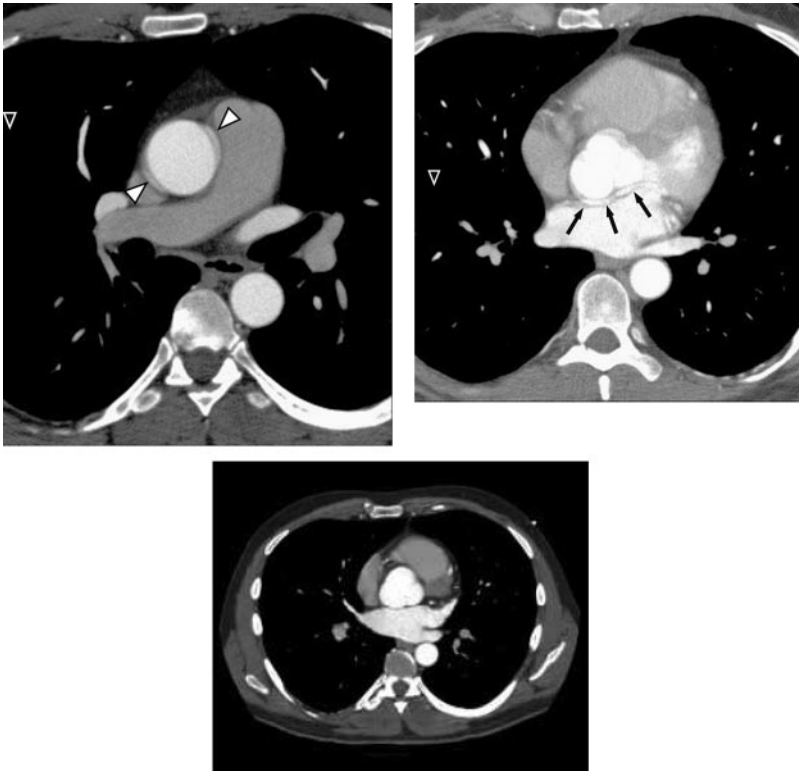
**Figure 8.** Traumatic aortic rupture secondary to a motor vehicle crash. Top, Axial CT image demonstrates a traumatic injury with pseudoaneurysm (T) in the proximal descending thoracic aorta, numerous bilateral rib fractures, and small bilateral pleural effusions, with no significant mediastinal hematoma. Bottom, Still image through the thorax further demonstrates the extent of the aortic trauma. The full cine video for the bottom panel is available in the online-only Data Supplement at <http://circ.ahajournals.org/cgi/content/full/CIR.0b13e3181d4739e/DC1>. CT indicates computed tomographic imaging.

and demonstrate contrast leak indicating rupture. Imaging of the vascular tree from the thoracic inlet to the pelvis, including the iliac and femoral arteries, provides sufficient information to plan surgical or endovascular treatment, if needed. Prompt interpretation and communication of findings to the appropriate treating physicians are essential in the acute setting.

For trauma patients, the sensitivity, specificity, and accuracy of contrast-enhanced multidetector CT for traumatic aortic injury are 96%, 99%, and 99%, respectively.<sup>48–50</sup> The negative predictive value of contrast-enhanced CT approaches 100% in many studies, most with in-hospital follow-up of negative CT examinations<sup>36,48,51,52</sup> (Figure 8).

An outcome study of 278 patients undergoing contrast-enhanced CT for blunt chest trauma revealed 6 patients with aorta/great vessel injury and confirmed the 100% negative predictive value in the remaining patients using an extensive review of medical databases with a median follow-up of 20.5 months.<sup>53</sup>

Regarding other thoracic aortic diseases, CT has been shown to have a 92% accuracy for diagnosing abnormalities of the thoracic aorta, in a series of examinations that included 33 thoracic aneurysms, 3 ruptured thoracic aortic aneurysms,



**Figure 9.** Mimic of aortic dissection created by motion of the aortic root. Top left, Image at the level of the right pulmonary artery demonstrates a normal descending thoracic aorta and pseudodissection of the ascending aorta due to motion artifact that occurs on non-ECG-gated CT examinations (arrow). Top right, Image at the aortic root shows a double contour to the aortic root that may simulate a dissection flap (arrow). Bottom, Still image through the thoracic aorta further delineates the extent of the motion artifact. The full cine video is available in the online-only Data Supplement at <http://circ.ahajournals.org/cgi/content/full/CIR.0b013e3181d4739e/DC1>. CT indicates computed tomographic imaging; and ECG, electrocardiogram.

6 PAUs, 5 AoDs, and 2 pseudoaneurysms. In addition, CT correctly predicted the need for hypothermic circulatory arrest during surgical repair in 94% of patients.<sup>54</sup> For congenital and inflammatory conditions of the thoracic aorta, the literature is primarily descriptive, and accuracy data are not available.

#### 4.3.1. Computed Tomographic Imaging Technique

Although nonhelical CT scanners are capable of diagnosing thoracic aortic disease, the technique used is axial step-and-shoot technology. Inherent limitations include slow scan speed, relatively poor spatial resolution given thicker collimation used to extend the needed craniocaudal coverage, and inherently a noncontiguous dataset. Any patient motion, even minimal, between the acquisition of each image or cluster of images creates a stair-step artifact on multiplanar and 3-dimensional renderings. Helical CT scanners of 4 and greater detector rows consistently provide volumetric acquisitions of the thoracic aorta. Scanners with 16 and greater detector rows provide isotropic resolution in the *x*, *y*, and *z* axes, which allows the datasets to be reconstructed in the optimum imaging plane best suited to any individual vessel.

Technical parameters recommended for image reconstruction are slices of 3-mm or less thickness with a reconstruction interval of 50% or less than the slice thickness at 50% or greater overlap, tube rotation of 1 second or less, and 120 to 140 kVp.<sup>55</sup> ECG gating is particularly useful for ascending aortic disease, eliminating motion artifact at the aortic root that can simulate an AoD (Figure 9), and allowing evaluation of aortic valve morphology and function, as well as evaluation of the proximal coronary arteries. If appropriately acquired, an aorta CT and a complete CT coronary angiogram can be obtained in 1 CT acquisition. For AoD, the scan

coverage should start above the aortic arch and extend at least to the aortoiliac bifurcation, and probably the groin. This is important to determine both branch vessel involvement, such as lesion extension into the abdominal aorta and iliac arteries and characterization and diagnosis of malperfusion syndrome, and to evaluate access for percutaneous repair when transluminal therapy is being considered. (For further information on technique parameters and anatomic coverage, see the online-only Data Supplement.)

The CT angiographic acquisition uses intravenous contrast delivered at rate of 3 to 5 mL/s by a power injector and usually followed by a saline bolus. The total volume of contrast used should be kept as low as possible, to no greater than 150 mL.

Although axial sections remain the mainstay of interpretation, 2- and 3-dimensional reconstructions, such as maximum intensity projection, multiplanar and curved multiplanar reformations, and volume rendering, may augment interpretation and improve communication of the findings.<sup>54</sup> To our knowledge, it has not been scientifically shown that the use of these tools increases diagnostic accuracy or diagnostic confidence among specialists. For example, in 1 study multiplanar reconstructions when added to axial images alone changed the interpretation in only 1 case.<sup>54</sup> However, 3-dimensional reconstruction is likely to play an important role in the planning of surgical or endovascular approaches.

#### 4.4. Magnetic Resonance Imaging

MR has been shown to be very accurate in the diagnosis of thoracic aortic disease, with sensitivities and specificities that are equivalent to or may exceed those for CT and TEE.<sup>44,58–62</sup> Like CT, MR provides a multiplanar evaluation of the



thoracic aorta, and the examination can be extended in coverage to include the length of the aorta and branch vessels, from skull base to the toes. Advantages of MR include the ability to identify anatomic variants of AoD (IMH and PAU), assess branch artery involvement, and diagnose aortic valve pathology and left ventricular dysfunction without exposing the patient to either radiation or iodinated contrast. Disadvantages include prolonged duration of imaging acquisition during which the patient is inaccessible to care providers; inability to use gadolinium contrast in patients with renal insufficiency; contraindication in patients with claustrophobia, metallic implants, or pacemakers; and lack of widespread availability on an emergency basis. Although time-resolved MR techniques are improving, MR often cannot clearly characterize the relationship of an intimal flap and aortic root structures, specifically the coronary arteries. Likely as a result of these considerations, data from IRAD found that MR was the least-used imaging study, used in only 1% of patients as the initial diagnostic study.<sup>63</sup> For traumatic injury and congenital and inflammatory conditions of the thoracic aorta, the literature is primarily descriptive, and accuracy data are not available.

#### **4.4.1. Magnetic Resonance Imaging Technique**

A comprehensive MR examination of the thoracic aorta may include many components, including black blood imaging, may include basic spin-echo sequences, noncontrast white blood imaging, contrast-enhanced MR angiography using gadolinium based agents, and phase-contrast imaging. MR of the thoracic aorta in the acute setting can be shortened to meet urgent patient assessment needs. The use of each is described more specifically later. MR examinations have become faster, with advances in gradient hardware that have significantly reduced repetition times, resulting in ultrafast MR angiography techniques. However, MR examinations remain 2 to 4 times longer than CT examinations. MR terminology across imaging vendors is less consistent than that of CT; therefore, imaging sequences are described later as general types of sequences without vendor-specific details.<sup>58,59</sup>

#### **4.4.2. Black Blood Imaging**

Black blood imaging, using spin-echo sequences, is used to evaluate aortic anatomy and morphology (such as aortic size and shape), and the aortic wall for hematoma or other causes of thickening such as vasculitis. They may be repeated after the administration of gadolinium-based contrast agents to identify wall enhancement. These sequences should use ECG gating at end-diastole and may be performed with or without double inversion recovery techniques that null the signal from blood. These sequences generate 2-dimensional images that can be obtained in the axial, sagittal, and coronal planes, as well as the oblique sagittal or “candy cane” view. T1-weighted gradient echo sequences may be used in place of black blood images and are usually performed both before and after contrast administration. They can be obtained in the axial, sagittal, and coronal planes.

#### **4.4.3. Noncontrast White Blood Imaging**

This is performed using either basic gradient echo sequences or the more advanced balanced steady-state free precession

techniques (SSFP) that are T2\*-weighted and generate images with subsecond temporal resolution. Signal is generated from blood, making it appear white in the absence of contrast. SSFP techniques use ultrashort repetition times that require MR scanners with high-performance gradients. For the latter, an in-plane resolution of approximately  $2.0 \times 1.5 \text{ mm}^2$  can be obtained using a repetition time of 3.2 ms, TE of 1.6 ms, flip angle of 60 to 70 degrees, and a  $256 \times 256$  matrix. SSFP techniques can be performed to generate 2-dimensional, 3-dimensional, and cine images; the 2-dimensional images are usually performed in the axial, sagittal, and coronal planes in an interleaved manner and use ECG gating with triggering at end-diastole to generate images in less than 500 ms that do not require breath holding. Cine SSFP sequences require 7- to 9-second breath holding and are usually only performed at specific anatomic locations of interest, as determined by the findings on the previously generated images. For patients who cannot hold their breath, cine SSFP sequences can be performed without using ECG gating or breath holding but with substantially lower spatial and temporal resolution.

#### **4.4.4. Contrast-Enhanced Magnetic Resonance Angiography**

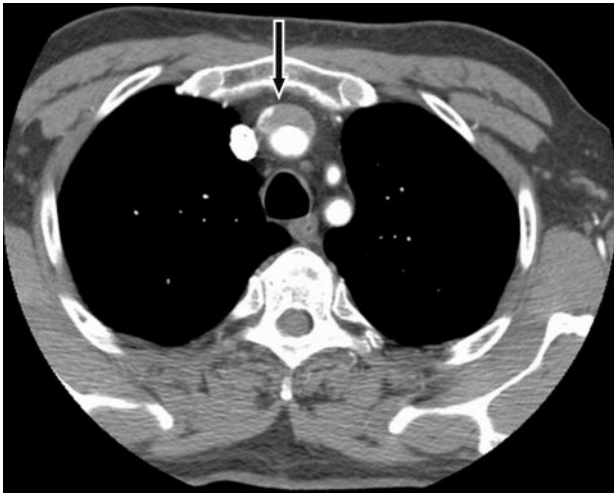
For the thoracic aorta, contrast-enhanced MR angiography is usually performed with ECG gating. Although this increases acquisition time, it provides motion-free images of the aortic root and ascending aorta. For patients without a contraindication to receiving a gadolinium-based contrast agent, contrast-enhanced MR angiography is often the sequence of choice from which most of the diagnostic information is obtained. Contrast-enhanced MR angiography images are obtained as a 3-dimensional volumetric dataset, which can be manipulated and viewed in much the same manner as CT scan datasets. Advances in MR, particularly gradient strength, have markedly reduced the acquisition times of contrast-enhanced MR angiography possible to subsecond acquisition times. This temporally resolved subsecond contrast-enhanced MR angiography is particularly useful in critically ill patients or patients who cannot hold their breath, where motion artifact can degrade other sequences that take longer to acquire, with the tradeoff being a reduction of in-plane resolution.

#### **4.4.5. Phase Contrast Imaging**

These sequences are usually performed to evaluate gradients across an area of stenosis, across an intimal or cardiac valve. Image contrast is produced by differences in velocity. Images are obtained using ECG gating or triggering. Two-dimensional images are generated that center on the area of concern. Peak flow and velocity measurements may be calculated, and time–flow and time–velocity curves are generated.

### **4.5. Standards for Reporting of the Thoracic Aorta on Computed Tomography and Magnetic Resonance Imaging**

Viewing and measuring are best accomplished at a picture archiving and communications system workstation or an independent computer workstation, in which the aorta can be rotated into the best orientation to review each segment of the



**Figure 10.** Left brachiocephalic vein mimics an intramural hematoma on CT. Axial CT image demonstrates a low-attenuation crescent of material anterior to the innominate artery. CT indicates computed tomographic imaging.

aorta and the aortic branches. This minimizes the chance of inadvertently confusing normal structures for vascular abnormality (Figure 10).

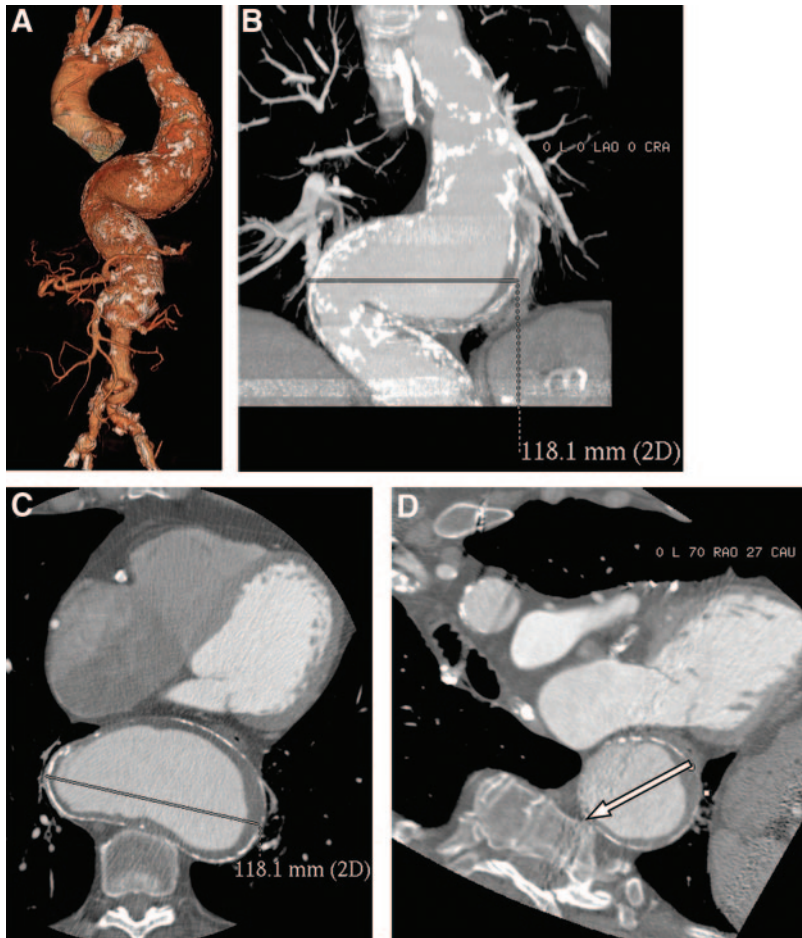
The writing committee believes that specific qualitative and quantitative elements are important to include in reports (Table 5).

Diameter measurements taken from axial images are inherently incorrect unless the artery being measured is perfectly aligned in cross section on the image (Figure 11). It is preferable to make diameter measurements perpendicular to the longitudinal or flow axis of the aorta to correct for the variable geometry of the aorta. Suggested standard anatomic locations are noted in Figure 12. The use of standardized measurements helps minimize errant reports of significant aneurysm growth due to technique or interreader variability in measuring technique.

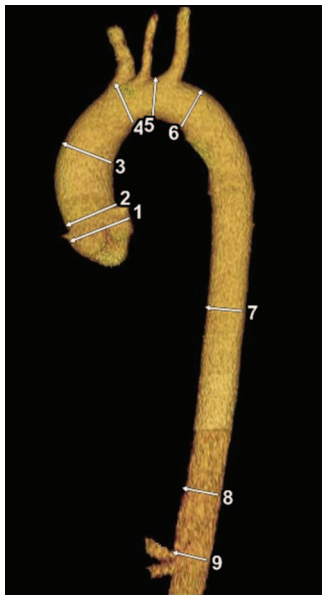
**4.6. Angiography**

Angiography provides accurate information about the site of dissection, branch artery involvement, and communication of the true and false lumens.<sup>60,61</sup> Additionally, angiographic and catheter-based techniques allow for evaluation and treatment of coronary artery<sup>62</sup> and aortic branch (visceral and limb artery) disease, as well as assessment of aortic valve and left ventricular function.<sup>60,63</sup>

Disadvantages of angiography compared with other less invasive modalities include 1) not being universally available because it requires the presence of an experienced physician to perform the study; 2) being an invasive procedure that is time consuming and requires exposure to iodinated contrast; 3) having poor ability to diagnose IMH given a lack of luminal disruption; 4) potentially producing false negative results when a thrombosed false lumen prevents adequate



**Figure 11.** Markedly tortuous aorta with thoracoabdominal aortic aneurysm demonstrated on (A) 3-dimensional shaded surface display rendering. B and C represent incorrect measurement of the aorta on standard coronal and axial images respectively, while D is an image of the aorta perpendicular to the centerline or axis of the aorta, with the arrow demonstrating the correct location for diameter measurement, which in this case was 7.8 cm.



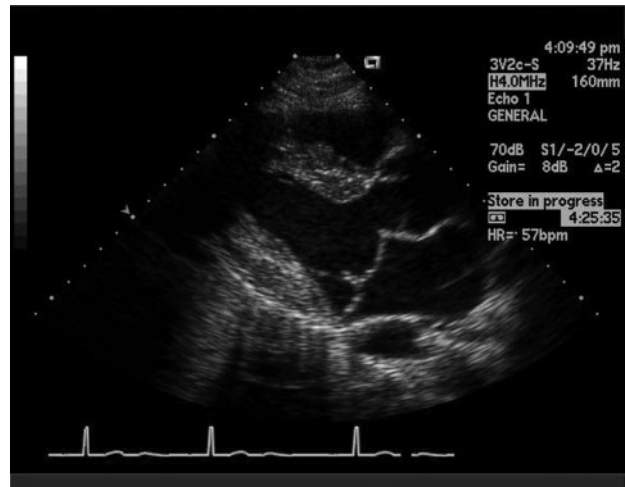
**Figure 12.** Normal anatomy of the thoracoabdominal aorta with standard anatomic landmarks for reporting aortic diameter as illustrated on a volume-rendered CT image of the thoracic aorta. CT indicates computed tomographic imaging. Anatomic locations: 1, Aortic sinuses of Valsalva; 2, Sinotubular junction; 3, Mid ascending aorta (midpoint in length between Nos. 2 and 4); 4, Proximal aortic arch (aorta at the origin of the innominate artery); 5, Mid aortic arch (between left common carotid and subclavian arteries); 6, Proximal descending thoracic aorta (begins at the isthmus, approximately 2 cm distal to left subclavian artery); 7, Mid descending aorta (midpoint in length between Nos. 6 and 8); 8, Aorta at diaphragm (2 cm above the celiac axis origin); 9, Abdominal aorta at the celiac axis origin. CT indicates computed tomographic imaging.

opacification to identify the dissection; and 5) reported sensitivities and specificities of angiography for the evaluation of acute AoD that are slightly lower than those for the other less invasive modalities.<sup>42,64,65</sup> Thus, CT, MR, and TEE have replaced catheter-based angiography as the first-line diagnostic tests to establish the presence of the acute aortic syndrome.<sup>60,63,66,67</sup> Multidetector CT has also largely replaced angiography for the anatomic studies required for treatment planning and monitoring of aortic disease.<sup>68</sup>

#### 4.7. Echocardiography

The aorta and its major branches can be visualized with echocardiography using a variety of imaging fields as well as methods of ultrasound. The suprasternal view is best for visualizing the aortic arch, whereas the aortic root and ascending aorta are best seen in the left (and sometimes right) parasternal projection. When involvement of the innominate artery, left subclavian artery, or left common carotid artery is suspected, orthogonal and longitudinal scanning planes are helpful. Imaging of the descending thoracic aorta is less easily accomplished with echocardiography compared with other imaging modalities. Abdominal scan planes can be used to visualize the caudal descending aorta.

In general, TEE is superior to TTE for assessment of the thoracic aorta. Through the use of multiplane image acquisi-



**Figure 13.** Transthoracic echocardiogram of a patient with Marfan syndrome with mitral valve prolapse and 4-cm ascending aortic aneurysm.

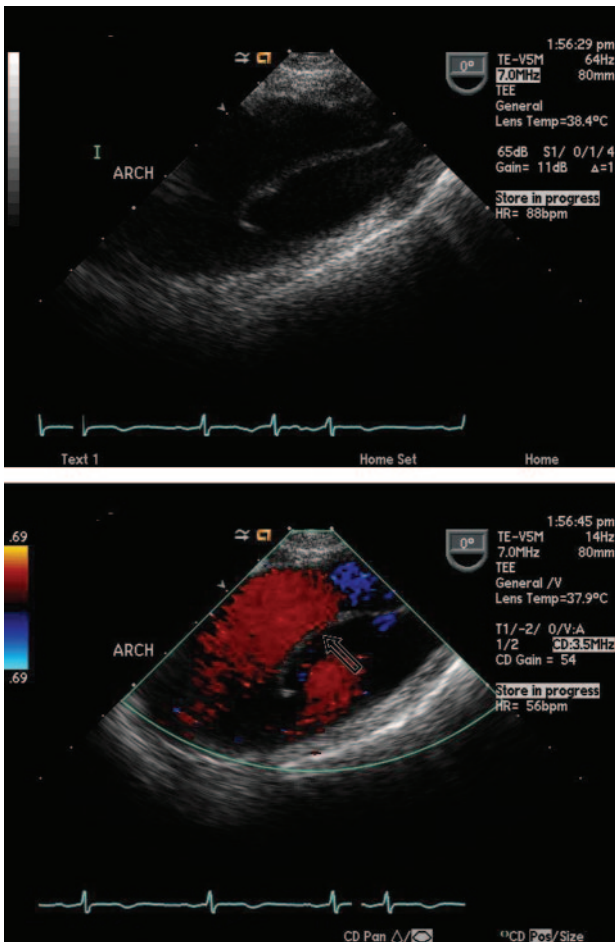
tion, 3-dimensional Doppler TEE is safe and can be performed at the bedside, with a low risk of complications (less than 1% overall, less than 0.03% for esophageal perforation), most of which are related to conscious sedation.<sup>69,70</sup> Reconstruction of the aorta can be performed. Intraoperative use of TEE is noted in Sections 14.2.3 and 14.2.4.

##### 4.7.1. Echocardiographic Criteria for Thoracic Aortic Aneurysms

The echocardiographic diagnosis of thoracic aortic aneurysms is determined on demonstration of aortic enlargement relative to the expected aortic diameter, based on age- and body size-adjusted nomograms (Figures 2, 3, 4, and 13). For other aortic segments, such nomograms have not been developed, so aortic dilatation is diagnosed when the aorta exceeds a generally agreed to standard diameter (Table 3) or when a given aortic segment is larger than contiguous aortic segment(s) of apparently normal size. Beyond establishing the presence of aortic enlargement, echocardiography may reveal associated cardiac pathology that suggests the underlying etiology of the aortic disease (eg, bicuspid aortic valve).

##### 4.7.2. Echocardiographic Criteria for Aortic Dissection

The echocardiographic diagnosis of an AoD requires the identification of a dissection flap separating true and false lumens (Figure 14). However, one of the major limitations of both TTE and TEE is the frequent appearance of artifacts that mimic a dissection flap (Figure 15). These usually arise from a mirror image or reverberation artifact that appears as a mobile linear echodensity overlying the aortic lumen. It is therefore essential that the echocardiographer make certain to distinguish true dissection flaps from such artifacts. The first step is to confirm the presence of the dissection flap from several angles and from several transducer locations. The second step is to confirm that the dissection flap has a motion independent of surrounding structures and that the apparent flap is contained within the aortic lumen (ie, does not pass through the aortic wall in any view). The third step is to use



**Figure 14.** Arch aneurysm with dissection flap. Top, Arch dissection, 2-dimensional view. Bottom, Arch dissection (arrow) with color-flow Doppler margination.

color-flow Doppler to demonstrate differential flow on the 2 sides of the dissection flap. Often one can visualize 1 or more sites of intimal tears, with color-flow Doppler demonstrating sites of flow between the 2 lumens. The true lumen typically exhibits expansion during systole and collapse during diastole. Additional signs of the true lumen include little or no spontaneous echocardiographic contrast, systolic jets directed away from the lumen, and forward flow during systole. The false lumen often exhibits diastolic expansion, evidence of spontaneous contrast, complete or partial thrombosis, and reversed, delayed, or absent blood flow. Imaging criteria for distinguishing the true and false lumens have also been described for intravascular ultrasound<sup>71</sup> and CT.<sup>72</sup> Features that characterize the false lumen of an acute dissection include the wedgelike angle (the “beak sign”) where the dissection flap meets the aortic wall, the presence of strand-like structures (“cobwebs”) in the lumen, and the lack of a laminar structure in the outer wall of the lumen.

Associated echocardiographic findings of clinical importance include identification of a pericardial effusion. Indeed, it is often possible to see a layer of echogenic material within the pericardial fluid that is indicative of hemopericardium. Echocardiography can provide important information about right and left ventricular function and myocardial ischemia

based on assessment of left ventricular segmental wall motion. On TEE, one can identify the ostia of the 2 coronary arteries and detect involvement by the dissection flap. Echocardiography also identifies the presence of aortic regurgitation and permits grading of its severity. On TEE, the mechanisms of acute aortic regurgitation can be defined, and these data can be used to guide the surgeon’s efforts to spare the valve at the time of aortic repair.

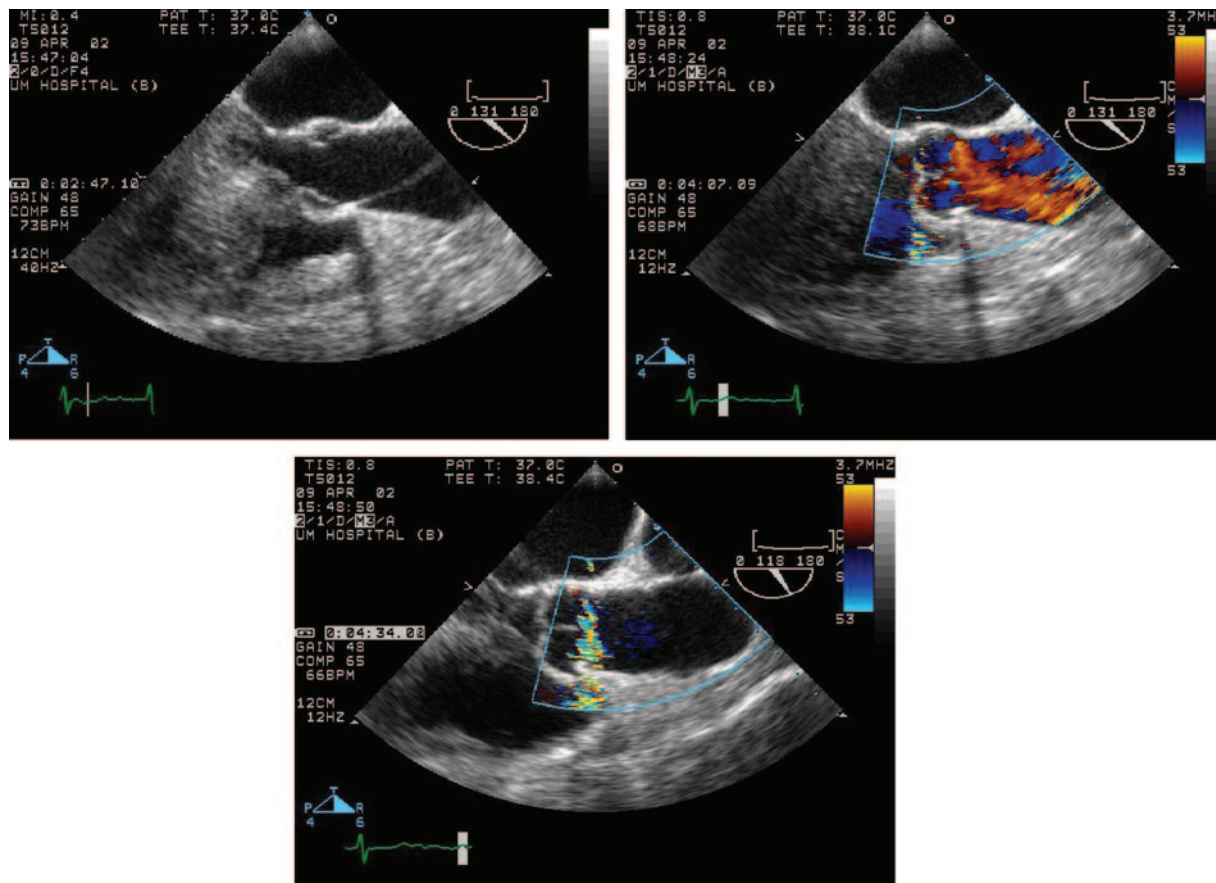
#### 4.7.2.1. Diagnostic Accuracy of Echocardiography for Aortic Dissection

TTE has a sensitivity of 77% to 80% and a specificity of 93% to 96% for identification of proximal AoD. For distal AoD, the sensitivity of TTE is lower. TEE improves the diagnostic accuracy substantially, particularly when a patient’s body shape, chest wall, or concomitant pulmonary disease restricts the transthoracic windows for aortic imaging. With TEE, sensitivity for proximal AoD is 88% to 98% with a specificity of 90% to 95%.<sup>46</sup> A 2006 meta-analysis that evaluated the diagnostic utility of TEE in suspected thoracic AoD included 630 patients from 10 different studies. TEE was shown to both accurately identify and rule out acute AoD with sensitivities and specificities of 98% (95% CI 95% to 99%) and 95% (95% CI 92% to 97%), respectively.<sup>46</sup>

Major advantages of TEE include its portability (allowing for bedside patient evaluation), rapid imaging time, and lack of intravenous contrast or ionizing radiation. Additionally, dissection-related cardiac complications can be evaluated including aortic regurgitation, proximal coronary artery involvement, and the presence of tamponade physiology. Disadvantages of TEE include a potential lack of availability (particularly at small centers and during off hours) and sedation requirements that may include endotracheal intubation.<sup>73</sup> The accuracy of TEE can be quite operator dependent. For the very distal ascending aorta and the proximal aortic arch, TEE may be limited by a blind spot caused by interposition of the trachea and left main bronchus between the esophagus and aorta. Small, circumscribed AoDs or IMHs in this region are less well visualized by TEE. Another limitation of TEE is its inability to visualize the abdominal aorta; if there is concern of a malperfusion syndrome, an abdominal CT may also be required.

#### 4.7.2.2. Diagnostic Accuracy of Echocardiography for Acute Intramural Hematoma

IMH of the aorta has a distinctly different appearance on echocardiography. In contrast to classic AoD, in IMH there is no mobile intimal flap within the aortic lumen, and in most cases the aortic lumen has a relatively normal round appearance. Instead, in IMH there is thickening of the aortic wall that is typically crescentic in shape and extends along a length of the aorta. In some cases it can be difficult to distinguish the wall thickening of IMH from diffuse aortic atherosclerosis or mural thrombus lining an aortic aneurysm. However, atheroma and mural thrombus protrude from the aortic intima into the lumen, thus giving both the aortic wall and the lumen an irregular shape, whereas in IMH the inner lining of the aortic lumen remains smooth. Moreover, in the presence of intimal calcification, intramural thrombus will present as thickening



**Figure 15.** Artifact mimicking dissection. Top left, 2-dimensional view. Top right, Color-flow Doppler without margination. Bottom, Artifact not seen in this view.

external to calcification, whereas mural thrombus will be internal to calcification.

#### 4.7.2.3. Role of Echocardiography in Following Patients With Chronic Aortic Disease

Given that TEE is a semi-invasive procedure; it is usually not preferred for surveillance of patients with thoracic aortic diseases. Also, although TTE is noninvasive, its failure to visualize consistently and measure accurately the tubular portion of the ascending thoracic aorta is problematic. It is not typically used to follow aneurysms in that aortic segment. However, because TTE does accurately visualize the aortic root, its primary role as an imaging method for serial follow-up is in patients with aortic disease limited to the root, particularly those with Marfan syndrome. It is also used, often in conjunction with CT or MR, to observe patients with concomitant structural heart disease, such as bicuspid aortic valve, mitral valve prolapse, cardiomegaly, or cardiomyopathy.

## 5. Genetic Syndromes Associated With Thoracic Aortic Aneurysms and Dissection

### 5.1. Recommendations for Genetic Syndromes

#### Class I

1. An echocardiogram is recommended at the time of diagnosis of Marfan syndrome to determine the

aortic root and ascending aortic diameters and 6 months thereafter to determine the rate of enlargement of the aorta. (*Level of Evidence: C*)

2. Annual imaging is recommended for patients with Marfan syndrome if stability of the aortic diameter is documented. If the maximal aortic diameter is 4.5 cm or greater, or if the aortic diameter shows significant growth from baseline, more frequent imaging should be considered. (*Level of Evidence: C*)
3. Patients with Loays-Dietz syndrome or a confirmed genetic mutation known to predispose to aortic aneurysms and aortic dissections (*TGFBR1*, *TGFBR2*, *FBN1*, *ACTA2*, or *MYH11*) should undergo complete aortic imaging at initial diagnosis and 6 months thereafter to establish if enlargement is occurring.<sup>74–77</sup> (*Level of Evidence: C*)
4. Patients with Loays-Dietz syndrome should have yearly magnetic resonance imaging from the cerebrovascular circulation to the pelvis.<sup>23,78,79</sup> (*Level of Evidence: B*)
5. Patients with Turner syndrome should undergo imaging of the heart and aorta for evidence of bicuspid aortic valve, coarctation of the aorta, or dilatation of the ascending thoracic aorta.<sup>80</sup> If initial imaging is normal and there are no risk factors for aortic dissection, repeat imaging should be performed every 5 to 10 years or if otherwise clinically indicated. If abnormalities exist, annual imaging or follow-up imaging should be done. (*Level of Evidence: C*)

## Class IIa

1. It is reasonable to consider surgical repair of the aorta in all adult patients with Loeys-Dietz syndrome or a confirmed *TGFBR1* or *TGFBR2* mutation and an aortic diameter of 4.2 cm or greater by transesophageal echocardiogram (internal diameter) or 4.4 to 4.6 cm or greater by computed tomographic imaging and/or magnetic resonance imaging (external diameter).<sup>78</sup> (Level of Evidence: C)
2. For women with Marfan syndrome contemplating pregnancy, it is reasonable to prophylactically replace the aortic root and ascending aorta if the diameter exceeds 4.0 cm.<sup>74</sup> (Level of Evidence: C)
3. If the maximal cross-sectional area in square centimeters of the ascending aorta or root divided by the patient's height in meters exceeds a ratio of 10, surgical repair is reasonable because shorter patients have dissection at a smaller size and 15% of patients with Marfan syndrome have dissection at a size less than 5.0 cm.<sup>16,76,81</sup> (Level of Evidence: C)

## Class IIb

1. In patients with Turner syndrome with additional risk factors, including bicuspid aortic valve, coarctation of the aorta, and/or hypertension, and in patients who attempt to become pregnant or who become pregnant, it may be reasonable to perform imaging of the heart and aorta to help determine the risk of aortic dissection. (Level of Evidence: C)

### 5.1.1. Marfan Syndrome

Marfan syndrome is a heritable disorder of the connective tissue with a high penetrance but variable expression. Approximately 25% of patients do not have a family history and represent new cases due to sporadic mutations for the condition. Marfan syndrome results from mutations in the *FBNI* gene, with over 600 mutations currently entered into the *FBNI* mutation database causing Marfan syndrome or related conditions (<http://www.umd.be/>). The *FBNI* gene encodes fibrillin-1, a large glycoprotein that is secreted from cells and deposited in the extracellular matrix in structures called microfibrils. Microfibrils are found at the periphery of elastic fibers, including the elastic fibers in the medial layer of the ascending aorta, and in tissues not associated with elastic fibers.<sup>82</sup> Only 12% of *FBNI* mutations causing Marfan syndrome have been observed more than once in unrelated individuals, a fact that complicates using mutational detection for diagnosis. A second locus for Marfan syndrome, termed *MFS2*, was recently identified to be caused by mutations in the transforming growth factor-beta type II receptor (*TGFBR2*).<sup>83</sup> The phenotype of this locus may overlap for Loeys-Dietz syndrome. The criteria for Marfan syndrome is based primarily on clinical findings in the various organ systems affected in the Marfan syndrome, along with family history and *FBNI* mutations status.<sup>84</sup>

The cardinal features of Marfan syndrome involve the cardiovascular, ocular, and skeletal systems. Patients with Marfan syndrome are highly predisposed to thoracic aortic

aneurysm and/or dissection, with virtually every patient with the syndrome having evidence of aortic disease at some point during their lifetime. Other cardiovascular manifestations include valvular disease, primarily mitral valve prolapse and regurgitation.<sup>85</sup> Aortic regurgitation can result from distortion of the aortic valve cusps by an enlarged aortic root. The skeletal manifestations reflect overgrowth of the long bones and include arachnodactyly, dolichostenomelia, kyphoscoliosis, dolichocephaly, and pectus deformities. Abnormalities in the connective tissues are also manifested as joint laxity, recurrent or incisional hernias, striae atrophica, and dural ectasia.<sup>84</sup> The ocular manifestation that is both sensitive and fairly specific for Marfan syndrome is ectopia lentis or lens dislocation. The presence of ectopia lentis is a particularly useful clinical finding to differentiate Marfan syndrome from Loeys-Dietz syndrome.<sup>78</sup>

Most patients with Marfan syndrome present with dilatation of the aortic root/ascending aorta or Type A dissection. Internal aortic diameter measured at the sinuses of Valsalva provides a baseline for future evaluations because this is the aortic segment that dilates in Marfan syndrome. Of note, echocardiographic studies measure the internal diameter, whereas most patients undergo definitive imaging by CT and/or MR, which measures the external diameter (expected to be 0.2 to 0.4 cm larger than internal diameter), and external diameter is the measurement used in most cases to determine the threshold for surgical repair. There is growing awareness of the importance of relating this measurement to normal values based on age and body surface area<sup>15</sup> (Table 4). The severity of the aortic disease is related to the degree and segment length of aortic dilatation with dilatation limited to the sinuses of Valsalva having a less malignant prognosis than dilatation that extends to the aortic arch.<sup>86</sup> After diagnosis, follow-up imaging studies are recommended at 6 months and then annually if stability is documented based on the high likelihood of aortic disease progression. In most cases, TTE can be used to monitor the size of the sinuses of Valsalva.

A subset of patients present with Type B dissection, and a rare patient will present with AAA. The poor outcome of patients with Marfan syndrome with acute Type B dissections has led some to advocate early surgical repair.<sup>87</sup>

Studies addressing the efficacy of beta blockade in patients with Marfan syndrome have shown slower aortic root growth, fewer cardiovascular end points (defined as aortic regurgitation, dissection, surgery, heart failure, or death), and improved survival.<sup>88</sup> Patients continue to enlarge their aorta and dissect on therapy, so such medication does not preclude the need for routine imaging and prophylactic aortic repair when the diameter of the aorta warrants repair. It is also important to note that significant aortic root dilatation is correlated negatively with therapeutic response.<sup>88</sup> Recent studies in a mouse model of Marfan syndrome with aortic disease similar to that seen in humans showed that treatment with losartan normalized aortic root growth,<sup>6</sup> and a clinical trial using losartan in Marfan syndrome patients under the age of 25 years is in progress<sup>89,90</sup> (see Section 9.2.1.1).

Surgical repair of the dilated aortic root/ascending aorta for patients with Marfan syndrome is usually performed at a threshold of an external diameter of 5.0 cm,<sup>91</sup> smaller than that for other patients because of the greater tendency for AoD at a smaller diameter (see Section 9.2.2.1). Factors that will prompt repair at an external diameter of less than 5.0 cm are rapid growth defined as greater than 0.5 cm/y, family history of AoD at a diameter less than 5.0 cm, or the presence of significant aortic regurgitation.

After prophylactic repair of the ascending aorta, the arch and descending aorta are sites for later-onset aneurysms and dissections in patients with Marfan syndrome, prompting the need for routine imaging of the arch and descending aorta. Survival in patients with Marfan syndrome has been significantly improved with medical and surgical management of the aortic disease.<sup>76,92,93</sup> The David valve sparing reimplantation operation for suitable patients undergoing elective aortic root surgery at centers with a high volume of these cases has become standard practice,<sup>76,92–99</sup> although some have reported less-optimal long-term results with valve-sparing procedures.<sup>100,101</sup>

Pregnant patients with Marfan syndrome are at increased risk for AoD if the aortic diameter exceeds 4 cm<sup>102</sup> (see Section 10). All women with Marfan syndrome warrant frequent cardiovascular monitoring throughout pregnancy and into the puerperium. Limited data on the treatment of women with Marfan syndrome who experience dissections during pregnancy suggest a better outcome with cesarean section with concomitant aortic repair.<sup>103</sup>

### 5.1.2. Loeys-Dietz Syndrome

The Loeys-Dietz syndrome is an autosomal dominant aortic aneurysm syndrome with involvement of many other systems.<sup>78,104</sup> Loeys-Dietz syndrome results from mutations in either the transforming growth factor receptor Type I or II (*TGFBR1* or *TGFBR2*) genes and the diagnosis is confirmed through mutational analysis of these genes.<sup>105</sup>

The disease is characterized by the triad of arterial tortuosity and aneurysms, hypertelorism and bifid uvula or cleft palate, or a uvula with a wide base or prominent ridge on it. The arterial tortuosity is most commonly observed in the head and neck vessels but can occur in other vessels. These patients also have a spectrum of other features, which include the following: velvety and translucent skin, craniosynostosis, malar hypoplasia, retrognathia, blue sclera, patent ductus arteriosus, skeletal features similar to Marfan syndrome, dural ectasia, atrial septal defects, developmental delay, cervical spine abnormalities, and joint laxity. The vascular disease in these patients is particularly aggressive with a mean age of death of 26 years.<sup>78</sup> Most patients have aortic root aneurysms (98%) that lead to AoD. Because there are multiple reports of AoD occurring in patients with Loeys-Dietz when the aortic diameter was less than 5.0 cm, repair is recommended at smaller diameters<sup>78</sup> (see Section 5.1). For young children with severe systemic manifestations of Loeys-Dietz syndrome, specifically prominent craniofacial features that are associated with more severe aortic disease, once the aortic diameter exceeds the 99th percentile for age and the aortic valve annulus reaches 1.8 to 2.0 cm, prophylactic

surgery allows for the placement of a graft of sufficient size to accommodate growth. Of note, echocardiographic examinations that measure the internal aortic diameter were used in these studies to determine the threshold for surgical repair.

Patients with Loeys-Dietz also develop aneurysms of other vessels (53%), leading to the recommendation that they have yearly MR imaging from the cerebrovascular circulation to the pelvis. Current studies indicate that aggressive surgical management of the aneurysms in these patients can be achieved with few complications.<sup>23,78</sup> Surgical procedures in patients with Loeys-Dietz syndrome are not complicated by tissue fragility.<sup>23,79</sup>

### 5.1.3. Ehlers-Danlos Syndrome, Vascular Form or Type IV

The vascular form of Ehlers-Danlos syndrome is a rare autosomal dominant disorder characterized by easy bruising, thin skin with visible veins, characteristic facial features, and rupture of arteries, uterus, or intestines. Rupture of the gastrointestinal tract is more likely to occur prior to arterial rupture, and the majority of patients survive the gastrointestinal rupture.<sup>106</sup> Most of the fatal complications are caused by arterial rupture, with most deaths attributable to arterial dissections or ruptures involving primarily the thoracic or abdominal arteries, including AoDs and ruptures. These arterial ruptures lead to reduced life expectancy, with the median survival of only 48 years, and often no aneurysms are documented. If the rupture of an artery is life threatening, it can be surgically repaired, but tissue fragility, tendency to hemorrhage extensively, and poor wound healing may complicate the surgical repair.<sup>107</sup> Whether there is a role for the repair of unruptured aneurysms in patients with this syndrome is not clear, which is in contrast to Loeys-Dietz syndrome, where a role for prophylactic surgical repair of aneurysms is already well established. Nevertheless, when these patients present with AoD or aortic root aneurysms, successful aortic surgery can be achieved with careful handling of tissues and resewing of anastomoses with pledgeted sutures.<sup>76</sup> Noninvasive vascular imaging is preferred as fatal complications have been associated with invasive imaging in these patients.<sup>106</sup> The outcome of pregnancy in women with Ehlers-Danlos syndrome is poor because of rupture of the gravid uterus and vessel rupture at delivery or in the postpartum period. The diagnosis of vascular Ehlers-Danlos syndrome is based on DNA or protein studies identifying a defect in type III collagen, encoded by the *COL3A1* gene.

### 5.1.4. Turner Syndrome

Turner syndrome is defined as complete or partial absence of 1 sex chromosome in a phenotypic female, most commonly 45, X. Short stature and ovarian failure are the most prevalent findings, but women with Turner syndrome have an increased cardiovascular mortality rate from both structural and ischemic heart disease, especially AoD.<sup>108,109</sup> Between 10% and 25% of patients with Turner syndrome have a bicuspid aortic valve. Aortic coarctation is present in approximately 8% of patients. Determining aortic dilatation in patients with Turner syndrome is difficult because aortic dilatation is based on body surface area so the aortas of patients with Turner syndrome are expected to be smaller than those of the general

population because of the patient's short stature. If one defines aortic dilatation as an ascending-to-descending aortic diameter ratio of greater than 1.5, then 33% of women with Turner syndrome had aortic dilatation.<sup>110</sup>

The average age of AoD in Turner syndrome was 31 years, and less than half of the patients survived the event.<sup>111</sup> Data indicate a population-based AoD incidence of 36:100 000 Turner syndrome years (1.4% among individuals with Turner syndrome) compared with 6:100 000 in the general Danish population.<sup>112</sup> Therefore, the risk of AoD is much lower in patients with Turner syndrome compared with patients with Marfan syndrome or Loeys-Dietz syndrome. The majority of dissections in women with Turner syndrome occur in patients with known risk factors for dissection, such as cardiovascular malformations (bicuspid aortic valve or coarctation of the aorta), systemic hypertension, or both. Therefore, the evidence base regarding the value of screening for aortic disease in women with Turner syndrome is not available. However, there appears to be an increased risk for dissection in these women, suggesting that imaging of the heart, aorta, and pulmonary veins at the time of diagnosis might be valuable.<sup>80,113</sup> For patients with no risk factors for AoD (bicuspid aortic valve, coarctation, dilated aorta), re-evaluation of the aorta has been suggested every 5 to 10 years or if clinically indicated (eg, attempting pregnancy<sup>114</sup> or transition to an adult clinic). Patients with risk factors for AoD should undergo more frequent imaging. Recently, studies have not shown an effect of growth hormone treatment in women with Turner syndrome on either ascending or descending aortic diameter.<sup>113</sup> In addition, studies have not found any evidence of left ventricular hypertrophy in patients with Turner syndrome who were treated with growth hormone.<sup>115,116</sup>

#### 5.1.5. Other Genetic Syndromes With Increased Risk for Thoracic Aortic Aneurysms and Dissections

A substantial proportion of patients with Ehlers-Danlos syndrome who do not have the vascular form also have aortic root dilatation, but the progression of this dilatation to AoD is rare.<sup>76,117</sup> Similarly, patients with congenital contractural arachnodactyly or Beals syndrome due to mutations in *FBN2* have had aortic root enlargement without documented progression to dissection.<sup>118,119</sup>

There are other genetic syndromes that have multiple reports or documentation of thoracic aortic aneurysms leading to Type A dissections. There are multiple case reports of AoD in patients with autosomal dominant polycystic kidney disease.<sup>120,121</sup> Although AoD is a complication of autosomal dominant polycystic kidney disease, it is less common than cerebral aneurysms leading to subarachnoid hemorrhage in this population. There is insufficient information to gauge the value of routine or screening imaging for these patients.

Similar to autosomal dominant polycystic kidney disease, there are multiple reports in the literature of patients with Noonan syndrome who are experiencing AoDs.<sup>122–124</sup> The value of imaging or routine monitoring of these patients is unknown. A review of 200 patients with Alagille syndrome also identified thoracic aortic disease in a small subset of these patients.<sup>125</sup>

#### 5.1.6. Recommendations for Familial Thoracic Aortic Aneurysms and Dissections

##### Class I

1. **Aortic imaging is recommended for first-degree relatives of patients with thoracic aortic aneurysm and/or dissection to identify those with asymptomatic disease.**<sup>126,127</sup> (Level of Evidence: B)
2. **If the mutant gene (*FBN1*, *TGFBR1*, *TGFBR2*, *COL3A1*, *ACTA2*, *MYH11*) associated with aortic aneurysm and/or dissection is identified in a patient, first-degree relatives should undergo counseling and testing. Then, only the relatives with the genetic mutation should undergo aortic imaging.** (Level of Evidence: C)

##### Class IIa

1. **If one or more first-degree relatives of a patient with known thoracic aortic aneurysm and/or dissection are found to have thoracic aortic dilatation, aneurysm, or dissection, then imaging of second-degree relatives is reasonable.**<sup>126</sup> (Level of Evidence: B)
2. **Sequencing of the *ACTA2* gene is reasonable in patients with a family history of thoracic aortic aneurysms and/or dissections to determine if *ACTA2* mutations are responsible for the inherited predisposition.**<sup>26,27,77,78,128,129</sup> (Level of Evidence: B)

##### Class IIb

1. **Sequencing of other genes known to cause familial thoracic aortic aneurysms and/or dissection (*TGFBR1*, *TGFBR2*, *MYH11*) may be considered in patients with a family history and clinical features associated with mutations in these genes.**<sup>26,27,77,78,128,129</sup> (Level of Evidence: B)
2. **If one or more first-degree relatives of a patient with known thoracic aortic aneurysm and/or dissection are found to have thoracic aortic dilatation, aneurysm, or dissection, then referral to a geneticist may be considered.** (Level of Evidence: C)

A genetic basis of nonsyndromic familial thoracic aortic aneurysms and dissection has only recently been defined. Familial aggregation studies of patients referred for repair of thoracic aortic aneurysm and dissection that did not have a genetic defect have indicated that between 11% and 19% of these patients have a first-degree relative with thoracic aortic aneurysms and dissection.<sup>127,130</sup> Patients with a family history of thoracic aortic aneurysm and dissection present at a younger mean age than do sporadic patients but at a significantly older age than patients with Marfan or Loeys-Dietz syndrome. The disease is primarily inherited in an autosomal dominant manner with decreased penetrance primarily in women and variable expression.<sup>131</sup> These mapping studies have firmly established that there is significant genetic heterogeneity for familial thoracic aortic aneurysm and dissection (ie, many different genes can be mutated and cause the same clinical condition).<sup>27,77,129,132–134</sup> The causative gene has been identified for the following loci: *TAAD2* is due to *TGFBR2* mutations, the mutant gene at 16p is the *MYH11* gene, and the *TAAD4* defective gene is *ACTA2*.



**Table 6. Gene Defects Associated With Familial Thoracic Aortic Aneurysm and Dissection**

Defective Gene Leading to Familial Thoracic Aortic Aneurysms and Dissection	Contribution to Familial Thoracic Aortic Aneurysms and Dissection	Associated Clinical Features	Comments on Aortic Disease
<i>TGFBR2</i> mutations	4%	Thin, translucent skin Arterial or aortic tortuosity Aneurysm of arteries	Multiple aortic dissections documented at aortic diameters <5.0 cm
<i>MYH11</i> mutations	1%	Patent ductus arteriosus	Patient with documented dissection at 4.5 cm
<i>ACTA2</i> mutations	14%	Livedo reticularis Iris flocculi Patent ductus arteriosus Bicuspid aortic valve	Two of 13 patients with documented dissections <5.0 cm

*ACTA2* indicates actin, alpha 2, smooth muscle aorta; *MYH11*, smooth muscle specific beta-myosin heavy chain; and *TGFBR2*, transforming growth factor-beta receptor type II.

The defective gene at the *TAAD2* locus for familial thoracic aortic aneurysms and dissection was identified as *TGFBR2*, which is the same gene that is mutated in approximately two thirds of patients with Loeys-Dietz syndrome. Genetic testing of unrelated families with familial thoracic aortic aneurysm and dissections demonstrated that *TGFBR2* mutations were only present in 1% to 5% of families.<sup>26</sup> All 4 families had mutations that affected *TGFBR2* arginine 460 of the receptor, suggesting that missense mutation was associated with familial thoracic aortic aneurysm and dissection (ie, genotype-phenotype correlation). Although the majority of vascular disease in these families involved the ascending aorta, affected family members also had descending aortic disease and aneurysms of other arteries, including cerebral, carotid, and popliteal aneurysms. It is notable that similar to Loeys-Dietz syndrome, AoDs occur in patients with *TGFBR2* mutation at diameters less than 5.0 cm, leading to the recommendation that aortic repair be considered at a internal diameter by echocardiography of 4.2 cm or greater<sup>78</sup> (see Section 5.1).

A large French family with thoracic aortic aneurysm and dissection associated with patent ductus arteriosus was used to map the defective gene causing this phenotype to 16p.<sup>135</sup> The defective gene at this locus was identified as the smooth muscle cell-specific myosin heavy chain 11 (*MYH11*), a major protein in the contractile unit in smooth muscle cells.<sup>77</sup> Subsequent analysis of DNA from 93 unrelated families with thoracic aortic aneurysm and dissection failed to identify any *MYH11* mutations. Sequencing DNA from 3 unrelated families with thoracic aortic aneurysm and dissection associated with patent ductus arteriosus identified *MYH11* mutations in 2 of these families<sup>26</sup>; the remaining family had a *TGFBR2* mutation as the cause of the thoracic aortic aneurysm and dissection and patent ductus arteriosus. Therefore, *MYH11* mutations are responsible for familial thoracic aortic aneurysm and dissection associated with patent ductus arteriosus and a rare cause of familial thoracic aortic aneurysm and dissection.

A defective gene at the locus *10q23–24* was identified in a large family with multiple members with thoracic aortic aneurysm and dissection as *ACTA2*, which encodes the the smooth muscle-specific alpha-actin, a component of the contractile complex and the most abundant protein in vascular smooth

muscle cells.<sup>27,136</sup> Approximately 15% of families with thoracic aortic aneurysm and dissection have *ACTA2* mutations.<sup>27</sup> Features identified in some families with *ACTA2* mutation included livedo reticularis and iris flocculi, although the prevalence of these features has not been determined. The majority of affected individuals presented with acute Type A or B dissections or Type B dissections, with 16 of 24 deaths occurring due to Type A dissections. Two of 13 individuals experienced Type A dissections with a documented ascending aortic diameter less than 5.0 cm. AoDs occurred in 3 individuals under 20 years of age, and 2 women died of dissections postpartum. Finally, 3 young men had Type B dissection complicated by rupture or aneurysm formation at the ages of 13, 16, and 21 years.

Identification of the underlying genetic mutation leading to familial thoracic aortic aneurysms and dissections provides critical clinical information for the family. First, only family members who harbor mutations need to be routinely imaged for aortic disease. Second, identification of the underlying mutation may lead to different management of the aortic disease, as is the case for *TGFBR2* mutations. In addition to providing information to families, identification of genes leading to familial thoracic aortic aneurysms and dissections has emphasized the roles of smooth muscle contractile function in preventing aortic diseases.<sup>11</sup> Individuals who undergo genetic testing for thoracic aortic disease should receive genetic counseling prior to the testing to explain the implications for the testing for their medical follow-up and implications for family members.

## 5.2. Summary

The genes leading to nonsyndromic forms of aortic aneurysms and dissections are in the early stages of identification. Tables 6 and 7 summarize the current clinical features associated with mutations in these genes and recommendations for when to sequence these genes in families with multiple members with familial thoracic aortic aneurysm and dissection.

Given the familial risk of thoracic aortic aneurysms, screening the proband's first-degree relatives with appropriate imaging studies is indicated in the absence of identification of the defective gene leading to the disease.

Because thoracic aortic disease is typically asymptomatic until a life-threatening event (eg, AoD) occurs, evaluating

**Table 7. Genetic Syndromes Associated With Thoracic Aortic Aneurysm and Dissection**

Genetic Syndrome	Common Clinical Features	Genetic Defect	Diagnostic Test	Comments on Aortic Disease
Marfan syndrome	Skeletal features (see text) Ectopia lentis Dural ectasia	<i>FBN1</i> mutations*	Ghent diagnostic criteria DNA for sequencing	Surgical repair when the aorta reaches 5.0 cm unless there is a family history of AoD at <5.0 cm, a rapidly expanding aneurysm or presence or significant aortic valve regurgitation
Loeys-Dietz syndrome	Bifid uvula or cleft palate Arterial tortuosity Hypertelorism Skeletal features similar to MFS Craniosynostosis Aneurysms and dissections of other arteries	<i>TGFBR2</i> or <i>TGFBR1</i> mutations	DNA for sequencing	Surgical repair recommended at an aortic diameter of $\geq 4.2$ cm by TEE (internal diameter) or 4.4 to $\geq 4.6$ cm by CT and/or MR (external diameter)
Ehlers-Danlos syndrome, vascular form	Thin, translucent skin Gastrointestinal rupture Rupture of the gravid uterus Rupture of medium-sized to large arteries	<i>COL3A1</i> mutations	DNA for sequencing Dermal fibroblasts for analysis of type III collagen	Surgical repair is complicated by friable tissues Noninvasive imaging recommended
Turner syndrome	Short stature Primary amenorrhea Bicuspid aortic valve Aortic coarctation Webbed neck, low-set ears, low hairline, broad chest	45,X karyotype	Blood (cells) for karyotype analysis	AoD risk is increased in patients with bicuspid aortic valve, aortic coarctation, hypertension, or pregnancy

AoD indicates aortic dissection; *COL3A1*, type III collagen; CT, computed tomographic imaging; *FBN1*, fibrillin 1; MFS, Marfan syndrome; MR, magnetic resonance imaging; TEE, transesophageal echocardiogram; *TGFBR1*, transforming growth factor-beta receptor type I; *TGFBR2*, transforming growth factor-beta receptor type II.

\*The defective gene at a second locus for MFS is *TGFBR2* but the clinical phenotype as MFS is debated.

other family members can potentially prevent premature deaths. Most syndromes and familial forms of thoracic aortic disease are inherited in an autosomal dominant manner. Therefore, an individual with an inherited predisposition to thoracic aortic aneurysm and dissections has up to a 50% risk of passing on this predisposition to their children, which is the basis for genetic evaluation of the offspring. In addition, siblings and parents of the patient need to be evaluated for possible predisposition to thoracic aortic aneurysm and dissections. Because of the variable age of onset of aortic disease in familial thoracic aortic aneurysms and dissections, the writing committee believes that imaging of family members at risk of the disease every 2 years is warranted.

## 6. Other Cardiovascular Conditions Associated With Thoracic Aortic Aneurysm and Dissection

### 6.1. Recommendations for Bicuspid Aortic Valve and Associated Congenital Variants in Adults

#### Class I

1. **First-degree relatives of patients with a bicuspid aortic valve, premature onset of thoracic aortic disease with minimal risk factors, and/or a familial form of thoracic aortic aneurysm and dissection should be evaluated for the presence of a bicuspid aortic valve and asymptomatic thoracic aortic disease. (Level of Evidence: C)**

2. **All patients with a bicuspid aortic valve should have both the aortic root and ascending thoracic aorta evaluated for evidence of aortic dilatation.<sup>137-140</sup> (Level of Evidence: B)**

Bicuspid aortic valves is the most common congenital abnormality affecting the aortic valve and the aorta and is found in 1% to 2% of the population.<sup>137</sup> Nine percent of patients have family members who also have bicuspid aortic valves.<sup>141</sup> The ACC/AHA Valvular Heart Disease Guidelines specifically address this condition.<sup>5</sup> Of importance to this guideline, bicuspid aortic valves can be inherited in families as an autosomal dominant condition and may be associated with thoracic aortic aneurysm formation. It is important to note that in these families, members can have thoracic aortic aneurysms in the absence of bicuspid aortic valves.<sup>142</sup> The valves are prone to either aortic valve regurgitation, most commonly seen in younger patients, or aortic valve stenosis, more common in older patients. Bicuspid aortic valve repair for regurgitation has excellent long-term results, an important consideration in the absence of prosthetic aortic valve alternatives in this young population.<sup>99,139,140,143</sup> The most common site of fusion of the leaflets is at the left and right leaflet commissure, and less so at the right noncoronary leaflet commissure. The latter is typically more often associated with aortic valve stenosis. In a study of 2000 patients at the Cleveland Clinic who underwent bicuspid aortic valve surgery, 20% had concurrent ascending aortic aneurysms that required repair.<sup>139,140</sup>

AoD is also common, and as many as 15% of patients with acute AoD have bicuspid aortic valves,<sup>144</sup> a frequency more common than Marfan syndrome. AoD was present in 12.5% of patients with bicuspid valves with an aortic diameter less than 5 cm, reminiscent of patients with Marfan syndrome in whom 15% had AoD at a size less than 5 cm.<sup>16,143</sup>

The writing committee discussed the potential need to screen relatives of patients who have undergone aortic valve replacement before age 70, as these younger patients were more likely to have had bicuspid aortic valve as their primary pathology. However, 40% of women and around one third of men over age 70 undergoing aortic valve replacement have bicuspid aortic valve disease.<sup>145</sup> The yield from screening relatives of younger patients with bicuspid aortic valve disease compared with relatives of older patients is not known.

## 6.2. Aberrant Right Subclavian Artery

Aberrant right subclavian artery, which arises as the fourth branch from the aorta, courses behind the esophagus in approximately 80% of patients and causes dysphagia in many patients.<sup>146–149</sup> The dysphagia usually occurs in adults as the artery enlarges (Kommerell diverticulum).<sup>150,151</sup> In most adult patients, the aorta is also abnormal and is prone to aneurysm formation, dissection, and rupture. Surgical treatment in adults involves resection of the aneurysmal segment of the subclavian artery (the diverticulum) and the adjacent aorta and replacement of the aorta with a graft.<sup>152</sup> An alternative treatment is exclusion of the right subclavian artery origin and adjacent aorta using an aortic endograft, although long-term follow-up of this endovascular approach is not available and the compression and aneurysm growth may continue.<sup>153</sup> The distal normal segment of the subclavian artery is usually not reimplanted into the descending aorta directly but rather revascularized using an interposition graft or carotid-subclavian bypass. Alternatively, the subclavian artery can be ligated or coiled distal to the aneurysm, implanting the distal segment into the adjacent carotid artery in the neck and thus restoring flow to the upper extremity and the ipsilateral vertebral artery.<sup>148,149,152</sup>

## 6.3. Coarctation of the Aorta

Coarctation of the aorta is a relatively common abnormality that occurs in about 40 to 50 of every 100 000 live births, with a 2:1 ratio in males versus females. Most lesions are treated soon after birth or in childhood, and adults presenting with untreated coarctation of the aorta are rare. More often, patients have had previous procedures and present with later problems such as heart failure, intracranial hemorrhage, hypertension particularly with exercise, aneurysm formation, AoD, rupture of old repairs, undersized grafts of previous repairs, and infections. It is of particular importance in previously treated patients with some aortic narrowing to check for a gradient across the stenosis and for hypertension during exercise testing.<sup>154</sup>

Untreated coarctation of the aorta has a dismal prognosis, with 80% of patients dying from complications associated with the coarctation. Approximately one quarter will die from AoD or rupture, one quarter will die from heart failure, one

quarter will die from intracranial hemorrhage, and the remainder will die from other complications.

Surgical options, depending on the lesion, include subclavian artery patch aortoplasty, patch aortoplasty, bypass of the coarctation, tube graft replacement, aneurysm replacement, 2-stage combined bicuspid valve surgery, and arch and descending aorta replacement or ascending aorta-to-descending aorta bypass.<sup>3</sup> Endovascular balloon dilatation and stent placement has been used successfully and is becoming a less invasive alternative to conventional open surgical procedures.<sup>155</sup> Occasionally, the adult aorta may be redundant and kinked opposite the ligamentum arteriosum without any pressure gradient, the so-called pseudocoarctation. Aneurysms that require surgical treatment may develop proximal and distal to the kinked area.<sup>156</sup>

## 6.4. Right Aortic Arch

A right-sided aortic arch is present in approximately 0.5% of the population and rarely requires surgical repair. However, some patients present with dysphagia or asthma-like symptoms with expiratory wheezing. CT or MR readily diagnoses the problem of either tracheal compression or esophageal compression with the esophagus enlarged and filled with gas above the level of the arch. Felson and Palayew described 2 types.<sup>157</sup>

In Type I, the great vessels come off the right-sided arch in a manner that is a mirror image to normal anatomy; however, compression of the esophagus or trachea is caused by an enlarged aorta where it crosses the vertebral bodies or by the vascular ring formed by the atretic ductus arteriosus. In Type II, the aberrant left subclavian artery comes off the descending aorta and typically runs posterior to the trachea and compresses the trachea. As with an aberrant right subclavian artery, the proximal segment of the subclavian artery may enlarge and form a Kommerell diverticulum. Other variations are also seen but are exceedingly rare. A separate trunk may arise from the arch, and from this trunk, the innominate, carotid, and subclavian arteries arise. Another rare finding is a right-sided arch with a stump of left-sided aorta joining the right-sided arch after it crosses into the left chest. The stump of the left-sided aorta gives off a branch to the left subclavian artery. The aorta with right-sided arches is also abnormal and typically very fragile and prone to AoD, rupture, or aneurysm formation. Surgical repair involves resection of the aorta and, if needed, reimplantation or bypass of the aberrant left subclavian artery.

## 7. Inflammatory Diseases Associated With Thoracic Aortic Disease

### 7.1. Recommendations for Takayasu Arteritis and Giant Cell Arteritis

See Table 8.

#### Class I

1. Initial therapy for active Takayasu arteritis and active giant cell arteritis should be corticosteroids at a high dose (prednisone 40 to 60 mg daily at initiation or its equivalent) to reduce the active inflammatory state.<sup>158,159</sup> (*Level of Evidence: B*)

**Table 8. Inflammatory Diseases Associated With Thoracic Aortic Aneurysm and Dissection**

Names	Criteria Used in Diagnosis/Source	When Is Diagnosis Established?
Takayasu arteritis <sup>163</sup>	Age of onset <40 y Intermittent claudication Diminished brachial artery pulse Subclavian artery or aortic bruit Systolic BP variation of >10 mm Hg between arms Aortographic evidence of aorta or aortic branch stenosis	≥3 criteria are present (sensitivity 90.5%; specificity 97.8%)
Giant cell arteritis <sup>164</sup>	Age >50 y Recent-onset localized headache Temporary artery tenderness or pulse attenuation Elevated erythrocyte sedimentation >50 mm/h Arterial biopsy shows necrotizing vasculitis	≥3 criteria are present (sensitivity greater than 90%; specificity >90%)
Behçet disease <sup>165</sup>	Oral ulceration Recurrent genital ulceration Uveitis or retinal vasculitis Skin lesions—erythema nodosum, pseudo-folliculitis, or pathergy	Oral ulceration plus 2 of the other 3 criteria
Ankylosing spondylitis <sup>166</sup>	Onset of pain <40 y Back pain for >3 mo Morning stiffness Subtle symptom onset Improvement with exercise	4 of the diagnostic criteria are present

BP indicates blood pressure.

2. **The success of treatment of patients with Takayasu arteritis and giant cell arteritis should be periodically evaluated to determine disease activity by repeated physical examination and either an erythrocyte sedimentation rate or C-reactive protein level.<sup>160,161 (Level of Evidence: B)</sup>**
3. **Elective revascularization of patients with Takayasu arteritis and giant cell arteritis should be delayed until the acute inflammatory state is treated and quiescent.<sup>162 (Level of Evidence: B)</sup>**
4. **The initial evaluation of Takayasu arteritis or giant cell arteritis should include thoracic aorta and branch vessel computed tomographic imaging or magnetic resonance imaging to investigate the possibility of aneurysm or occlusive disease in these vessels. (Level of Evidence: C)**

**Class IIa**

1. **It is reasonable to treat patients with Takayasu arteritis receiving corticosteroids with an additional**

**anti-inflammatory agent if there is evidence of progression of vascular disease, recurrence of constitutional symptoms, or re-elevation of inflammatory marker.<sup>158 (Level of Evidence: C)</sup>**

**7.2. Takayasu Arteritis**

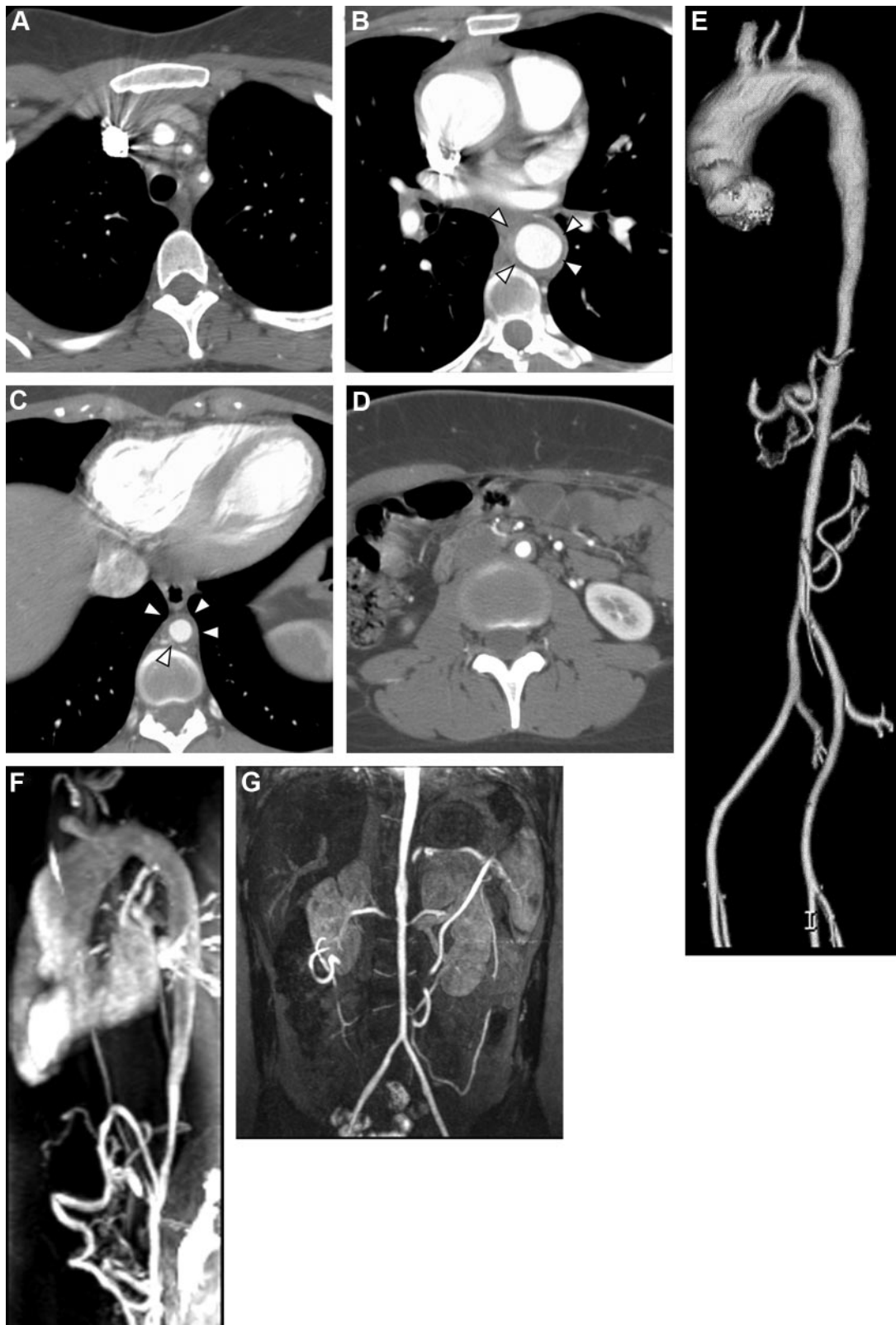
Takayasu arteritis, also known as pulseless disease, is an idiopathic vasculitis of the elastic arteries, involving the aorta and its branches. Initially described in Japan, the disease is found worldwide. In the United States, a review of cases in Olmsted County, Minn, reported a rate of 2.6 cases per million persons.<sup>158</sup> In the United States, the disease affects all ethnic and racial groups in proportion to the census with a moderate Asian overrepresentation. The disease affects women approximately 10 times more often than men. Most commonly diagnosed in the third decade (ie, the 20s) of life, the disease has been found in children and adults in the fifth decade (ie, the 40s). Two specific disease distributions have been reported: Japanese and Indian.<sup>167,168</sup>

In the Japanese distribution, the thoracic aorta and great vessels are most commonly affected. In contrast, in the Indian type, the disease most commonly affects the abdominal aorta and the renal arteries.<sup>28</sup> The pathogenesis of Takayasu arteritis remains poorly defined. A T-cell-mediated panarteritis, the disease proceeds from adventitial vasa vasorum involvement inward. The antigen for the localized inflammatory process is undefined but likely specific as the T cells undergo clonal expansion. The outcome process of destruction and fibrotic repair depends on the dominant pathophysiologic process: destruction yields aneurysms while fibrosis causes stenosis.

The diagnosis of Takayasu arteritis may be made using the 1990 American College of Rheumatology criteria: 1) age of onset younger than 40 years, 2) intermittent claudication, 3) diminished brachial artery pulse, 4) subclavian artery or aortic bruit, 5) systolic blood pressure variation of greater than 10 mm Hg between arms, and 6) angiographic (CT, MR) evidence of aorta or aortic branch vessel stenosis<sup>163</sup> (Figure 16). When 3 of the criteria are manifest, the sensitivity and specificity for diagnosis are 90.5% and 97.8%, respectively. Laboratory testing may aid in diagnosis. Markers of inflammation, such as C-reactive protein and erythrocyte sedimentation rate, are elevated in approximately 70% of patients in the acute phase and 50% in the chronic phase of disease.<sup>158</sup>

The clinical manifestations of the disease typically develop in 2 phases: acute and chronic. Acutely, the inflammation associated with Takayasu arteritis causes a host of constitutional, or “B,” symptoms, such as weight loss, fatigue, night sweats, anorexia, and malaise.<sup>158</sup> More chronically, once the vascular process has endured, patients report symptoms referable to the organs involved. In the largest US experience, more than half of all patients experienced upper extremity claudication, half had symptoms associated with cerebrovascular insufficiency (vision loss, lightheadedness, stroke), and a third reported carotid artery pain.<sup>158</sup> In an Indian series, hypertension as a result of renal artery involvement was the most common presenting sign.<sup>169</sup>

The aorta itself may develop either aneurysm or stenosis. In a Japanese series of 116 patients with Takayasu arteritis,



**Figure 16.** Takayasu arteritis with involvement of the thoracoabdominal aorta and great vessels as shown on contrast-enhanced CT and MR examinations. Note narrowing of the arterial lumen and circumferential soft tissue thickening of the walls of the great vessels and thoracic and abdominal aorta. Panel A, Image through the great vessels with narrowing of the left common carotid and left subclavian arteries. Panel B, Mid descending thoracic aorta (arrowheads). Panel C, Aorta just above the diaphragm (arrowheads). Panel D, Infrarenal aorta. Panel E, Volume-rendered image from CT demonstrates the extent of involvement. Panel F, Oblique sagittal MR of the thoracic aorta. Panel G, Coronal MR of the abdominal aorta. CT indicates computed tomographic imaging; and MR, magnetic resonance imaging.

nearly 32% of the patients had aortic aneurysm formation.<sup>170</sup> Most commonly, aneurysm formation developed in the descending aorta, followed by the abdominal, then ascending aortic segments. In the National Institutes of Health series of 60 patients with Takayasu arteritis, 23% had aortic aneurysm formation.<sup>158</sup> Aneurysms most commonly formed in the aortic arch or root, abdomen, and then other thoracic segments. Stenosis of the aorta is more common than is aneurysm formation, occurring in 53% of patients in the National Institutes of Health series. Any segment of the aorta may be involved, but the abdominal aortic segment is affected more than 70% of the time if stenosis is found.

Treatment of Takayasu arteritis begins with inflammation reduction with corticosteroids. Steroids are typically started at high dose, 40 to 60 mg daily at initiation to lower the erythrocyte sedimentation rate or C-reactive protein to normal, and are required for 1 to 2 years to ensure proper disease treatment.<sup>169</sup> Despite the prolonged regimen, nearly half of the patients will relapse during tapering, requiring additional immunosuppression. Second-line agents that have been used include methotrexate, azathioprine, and antitumor necrosis factor- $\alpha$  agents.<sup>158,169</sup> Unfortunately, markers of inflammation are imperfect barometers of disease activity. Disease progression has been shown to occur in the setting of normal marker levels.<sup>158</sup>

Revascularization for aortic stenosis or aneurysm occurs for the same indications as in noninflammatory disorders: secondary organ vascular insufficiency or risk of rupture. There are no randomized trials of percutaneous or surgical intervention in this disease.<sup>158,171–173</sup> Nonrandomized reports have shown that revascularization of either variety may be appropriate, with one caveat. The risk of graft failure is higher in patients with active local inflammation.<sup>162</sup> Moreover, the presence of aneurysmal disease itself may be problematic. One report documented a 12% incidence of anastomotic aneurysms over 2 decades of follow-up related to the presence of aneurysms at surgery.<sup>174</sup>

### 7.3. Giant Cell Arteritis

GCA, also known as temporal arteritis, is an elastic vessel vasculitis involving the aorta and its secondary and tertiary branches. Distinguishing it from Takayasu arteritis, GCA affects patients above the age of 50 years, with an incidence peaking in the eighth decade of life.<sup>175</sup> The disease affects women in a 3:2 ratio to men and has a predilection for those of northern European ancestry.<sup>29</sup> In the United States, epidemiologic investigation reports a prevalence of 20 cases per 100 000 persons. The incidence is higher in Scandinavian nations but lower in southern Europe, suggesting a genetic predisposition in certain populations.<sup>176</sup>

The clinical presentation of GCA is varied, requiring a heightened suspicion by clinicians for early diagnosis. Half of the patients report constitutional symptoms, such as weight loss, night sweats, malaise, and fever.<sup>177</sup> Because of the predilection for secondary and tertiary thoracic branches of the aorta, cranial symptoms are common. Scalp tenderness and headache are present in two thirds of patients and in up to 90% of patients with biopsy-proved disease.<sup>177</sup> Jaw claudication is common and affects half of the patients, 20%

develop visual changes, and other neurologic symptoms such as stroke or neuropathy occur in nearly one third.<sup>29</sup> Visual changes are particularly important to notice, because early treatment may prevent permanent blindness. Patients may report diplopia, amaurosis fugax, or blurriness prior to blindness. Polymyalgia rheumatica characterized by a generalized inflammatory state with proximal muscle involvement is found in nearly half of patients with GCA.<sup>29</sup> Patients with polymyalgia rheumatica report muscular pain and stiffness, particularly on initiation of movement.

Extracranial vascular involvement is less common in GCA than in Takayasu arteritis, occurring in 25% of patients. In a 50-year study of Olmsted County, Minn, that included 168 patients with GCA, aortic aneurysm/dissection was found in 18% of the subjects, whereas large-artery stenosis was noted in 13% of patients.<sup>178</sup> No patient had stenosis of the aorta. Aortic aneurysm formation represents an important marker. Although aneurysm formation per se does not reduce survival compared with the GCA cohort as a whole, AoD in the setting of an aneurysm reduces survival to an average of 1.1 years.<sup>178</sup> Similarly, aortic aneurysm rupture or dissection caused two thirds of deaths in a series of patients with GCA in California.<sup>179</sup>

The American College of Rheumatology diagnostic criteria for GCA include 1) age older than 50 years, 2) recent-onset localized headache, 3) temporal artery pulse attenuation or tenderness, 4) erythrocyte sedimentation rate greater than 50 mm/h, and 5) an arterial biopsy demonstrating necrotizing vasculitis.<sup>164</sup> Three or more criteria confer a sensitivity and specificity above 90% for the disease. With intracranial disease, temporal artery biopsies are diagnostic in up to 80% of cases.<sup>180</sup> The rate of positivity declines with initiation of glucocorticoid therapy, but this should not delay treatment to avoid GCA complications. Biopsies performed within 7 days of steroid initiation retain a high diagnostic yield.<sup>181</sup>

The pathophysiology of GCA shares important features with Takayasu arteritis.<sup>28</sup> GCA is marked by a T-cell clonal expansion suggesting a specific antigenic response, which currently remains unelucidated. The inflammatory response, which begins in the adventitial layer, is marked by augmented cytokine and MMP production causing granuloma formation. Granuloma formation both shields the vessel from the inciting antigen and causes vessel destruction. The inflammatory environment within the vessel wall with the possible formation of aneurysms or vessel stenosis is histologically identical to that of Takayasu arteritis. Because of the multiyear cyclical nature of disease incidence, some have posited an infectious etiology.<sup>29</sup>

Corticosteroids represent the standard in therapy for patients with GCA.<sup>182</sup> The typical treatment regimen includes starting prednisone dose of 40 to 60 mg daily, although recent evidence suggests a similar efficacy with 30 to 40 mg daily.<sup>183</sup> Therapy is typically required for 1 to 2 years to avoid recurrence, although the dose may be tapered beginning 2 to 3 months after initiation. Patients commonly report feeling much better rapidly but, as with Takayasu arteritis, new vascular involvement may occur in up to half of patients treated with steroids.<sup>184</sup> In contrast to Takayasu arteritis, additional immunomodulatory agents do not seem to modulate the disease's progress. Methotrexate studied in a double-

blind, placebo-controlled study as an adjunct to prednisone did not reduce morbidity, erythrocyte sedimentation rate level, or cumulative prednisone dose.<sup>184a</sup> Revascularization recommendations follow the same pattern as in Takayasu arteritis.

#### 7.4. Behçet Disease

In 1937, Hulusi Behçet described his eponymous syndrome based on a set of 3 symptoms: uveitis, aphthous stomatitis, and genital ulcers. Most common in Turkey, with a prevalence of 80 to 370 cases per 100 000 persons,<sup>185,186</sup> the disease is much less common in the United States, with an estimated prevalence of 1 to 3 cases per million persons.<sup>187</sup> The diagnostic criteria were established by the International Group for Behçet's disease and require oral ulceration and 2 of these 3 lesions: recurrent genital ulceration, uveitis or retinal vasculitis, or skin lesions, such as erythema nodosum, pseudofolliculitis, or pathergy.<sup>188</sup> In addition to these cardinal manifestations, vascular involvement may occur in one third of patients. A small vessel vasculitis commonly associated with the human leukocyte antigen (*HLA*) *B51* allele,<sup>187</sup> Behçet disease is 1 of 2 vasculitides that may also involve veins. Venous involvement is most commonly superficial thrombophlebitis, but deep vein thrombosis in the vena cava, varices, and cerebral sinuses has been reported.<sup>189</sup> The small vessel involvement of Behçet disease may result in nonvascular complaints, such as erythema nodosum, arthritis, and gastrointestinal involvement with diarrhea, gastrointestinal bleeding, or perforation.<sup>187</sup> Treatment of Behçet disease varies based on the manifestation of disease. Systemic corticosteroids are the typical therapy for those with vascular involvement.

Specifically with regard to vascular manifestations of Behçet disease, any artery or vein, large or small, systemic or pulmonary, may be involved by the vasculitic process. Aortic histopathology shows lymphocytic infiltration mixed with histiocytes and eosinophils with giant cells around vasa vasorum of media and adventitia. Destruction of media leads to aneurysm formation and may proceed to pseudoaneurysm formation and rupture. Aneurysm formation may occur in multiple sites and in different sites over a period of follow-up. Aneurysm, stenotic lesions, and occlusion of brachiocephalic arteries may occur with or without aortic involvement. Although aortic involvement is unusual for patients with Behçet vasculitis, aneurysm rupture can be unpredictable and fatal.<sup>190,191</sup> With regard to surgical repair, anastomotic pseudoaneurysms often occur (12.9% within 18 months in 1 series) and may be related to ongoing inflammatory changes in the area of anastomotic suture lines.<sup>192</sup> Endovascular repair with stent grafts has also been described.<sup>193</sup>

#### 7.5. Ankylosing Spondylitis (Spondyloarthropathies)

The group of diseases labeled spondyloarthropathies are linked by the strong association of major histocompatibility complex *HLA B-27* and the absence of rheumatoid factor.<sup>194,195</sup> Several features are common to the spondyloarthropathies, including sacroiliitis, inflammatory arthritis or enthesitis (inflammation of tendon insertions), associations with inflammatory bowel disease or psoriasis, and aortitis and heart block.<sup>195</sup>

Ankylosing spondylitis is the most common variant and often begins with back pain and stiffness in the second or third decade of life. It affects men 2 to 3 times as often as women, worsens with inactivity, and commonly takes years for the diagnosis to be made.<sup>196</sup> The diagnosis requires 4 of the 5 criteria: onset of pain at younger than 40 years, back pain for longer than 3 months, morning stiffness, subtle symptom onset, and improvement with exercise.<sup>197</sup> Patients may also report constitutional symptoms, such as malaise or fever. Acute anterior uveitis is reported in up to 40% of patients. Aortic root and aortic valve involvement are reported in up to 80% of patients.<sup>198</sup> When involved, the aortic valve may have a nodular appearance, and aortic valvular regurgitation is present in nearly half of the patients.<sup>198</sup> Treatment of aortic root expansion and aortic valvular abnormalities is the same as for other conditions.

#### 7.6. Infective Thoracic Aortic Aneurysms

Infection (due to bacterial, fungal, viral, spirochetal, or tubercular organisms) is a rare cause of thoracic aortic aneurysms. Originally named mycotic endarteritis by Osler,<sup>199</sup> the terms *infected aneurysm* or *infectious aortitis* are now used more commonly, because the majority of etiologic agents are nonfungal. Saccular aneurysms are most common, but infected aneurysms can be fusiform and often even pseudoaneurysms. The ascending thoracic aorta, aortic arch, and descending thoracic aorta can all be affected, as can prosthetic aortic grafts and aortic homografts. Typically, the sites of infected aneurysms are opposite the great vessels in the aortic arch or opposite the visceral arteries in the abdomen. There are several mechanisms by which the aortic infection may arise. First, there may be contiguous spread from adjacent thoracic structures, such as mediastinitis, abscess, infected lymph nodes, infectious pericarditis, empyema, or paravertebral abscess. Second, there may be septic emboli from underlying bacterial endocarditis. Third, there may be hematogenous dissemination of bacteria in the setting of sepsis or intravenous drug abuse. Infection most often arises in a diseased aorta, either in a preexisting aneurysm, at the site of an atherosclerotic plaque, or at the site of some accidental or iatrogenic aortic trauma. Indeed, infected thoracic aortic aneurysms may arise as a late complication of cardiac surgery, often associated with postoperative mediastinitis, typically at the sites of aortic cannulation or anastomotic suture lines.<sup>200,201</sup>

Various organisms can infect the aorta, with most infections being bacterial. *Staphylococcus aureus* and *Salmonella* are the organisms most commonly identified.<sup>202–204</sup> *Pneumococcus* and *Escherichia coli* are relatively common gram-positive and gram-negative pathogens, respectively.

*Treponema pallidum*, the gram-negative spirochete bacterium that causes syphilis, as well as other *Treponema* species, can cause infected aortitis, with the ascending thoracic aorta most often involved. However, in syphilitic aortitis, thoracic aortic aneurysm does not appear for 10 to 25 years after the initial spirochetal infection. Fungal infections of the aorta, with either *Candida* or *Aspergillus*, occur less often<sup>205</sup> and typically occur in the setting of impaired immunity, such as

patients with systemic illness, human immunodeficiency virus, or prior organ or bone marrow transplant.

Indeed, patients with impaired immunity are also at increased risk of tuberculous aortitis attributable to *Mycobacterium tuberculosis*. Tuberculous aortitis has until now been exceedingly rare, but the incidence may rise as the prevalence of tuberculosis rises worldwide. Tuberculous aortitis typically affects the distal aortic arch and descending thoracic aorta, likely because the aorta is thought to become infected via direct extension from continuous infected lymph nodes, empyema, or pericarditis.<sup>206</sup>

Finally, there appears to be an independent association between human immunodeficiency virus and ascending thoracic aortic dilatation, although its mechanisms are poorly understood.<sup>207,208</sup> Moreover, the incidence of frank aneurysms remains extremely low.

## 8. Acute Aortic Syndromes

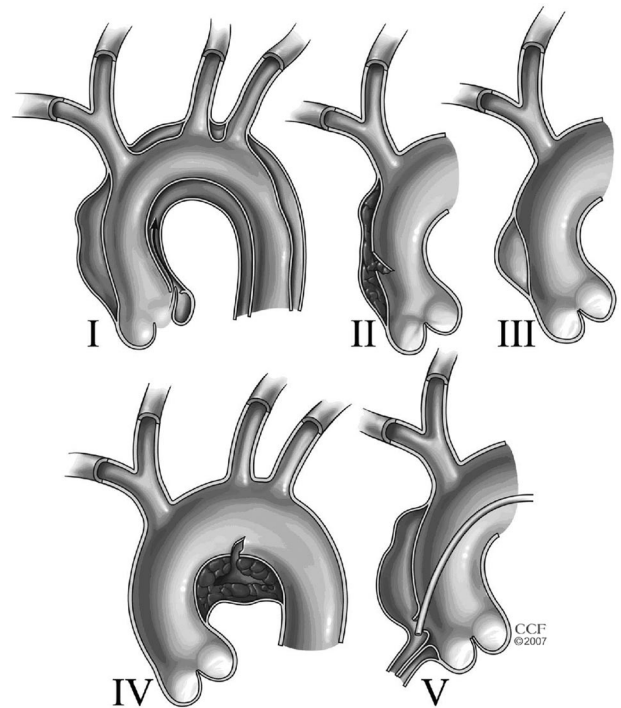
Acute aortic syndromes consist of 3 interrelated conditions with similar clinical characteristics and include AoD, IMH, and PAU.<sup>209</sup>

### 8.1. Aortic Dissection

#### 8.1.1. Aortic Dissection Definition

AoD is defined as disruption of the media layer of the aorta with bleeding within and along the wall of the aorta resulting in separation of the layers of the aorta. In the majority of patients (90%), an intimal disruption is present that results in tracking of the blood in a dissection plane within the media. This may rupture through the adventitia or back through the intima into the aortic lumen (Figure 17). This classic dissection results in a septum, or “flap,” between the 2 lumens (Figure 18). The false lumen may thrombose over time (Figure 19). While on noninvasive imaging, 15% of patients with aortic dissection syndromes have an apparent IMH without evidence of an intimal tear, autopsy studies show only 4% have no visible intimal tear; indeed, at the time of surgery a tear is found in most patients.<sup>210,211</sup> Occasionally, AoD originates from a small atheromatous ulcer that is difficult to identify. On the other hand, extensive atheromatous disease of the aorta may lead to PAU or a localized IMH.

The true incidence of acute AoD is difficult to define for 2 principal reasons: 1) acute AoD can be rapidly fatal, and when patients die prior to hospitalization, death may be erroneously attributed to another cause and 2) acute AoD is frequently missed on initial presentation, and early mortality among this group may be misclassified as non-dissection related. Population-based studies suggest that the incidence of acute AoD ranges from 2 to 3.5 cases per 100 000 person-years, which correlates with 6000 to 10 000 cases annually in the United States.<sup>75,212,215–217</sup> A review of 464 patients from IRAD reported a mean age at presentation of 63 years, with significant male predominance (65%).<sup>47</sup> The prevalence of AoD appears to be increasing, independent of the aging population, as noted by Olsson and colleagues,<sup>218</sup> who found the incidence of AoD among Swedish men has increased to 16 per 100 000 men yearly. It may be that 2 to 3 times as many patients die from AoD than from ruptured AAA; approximately 75% of patients with AAA will reach an emer-



**Figure 17.** Classes of intimal tears. I. Classic dissection with intimal tear and double lumen separated by septum. Communication between lumens is typically in descending aorta at sheared-off intercostal arteries or distal reentry site. II. IMH. No intimal tear or septum is imaged but is usually found at surgery or autopsy. DeBakey Types II and IIIa are common extent of this lesion. III. Intimal tear without medial hematoma (limited dissection) and eccentric aortic wall bulge. Rare and difficult to detect by TEE or CT. Patients with Marfan syndrome prone to this type. May result in aortic rupture or extravasation. IV. PAU usually to the adventitia with localized hematoma or saccular aneurysm. May propagate to Class I dissection, particularly when involving ascending aorta or aortic arch. V. Iatrogenic (catheter angiography or intervention)/traumatic (deceleration) dissection. CT indicates computed tomographic imaging; IMH, intramural hematoma; PAU, penetrating atherosclerotic ulcer; and TEE, transesophageal echocardiography. Figure reprinted with permission from the Cleveland Clinic Foundation. Legend adapted from Svensson et al,<sup>212</sup> Chirillo et al,<sup>213</sup> and Murray et al.<sup>214</sup>

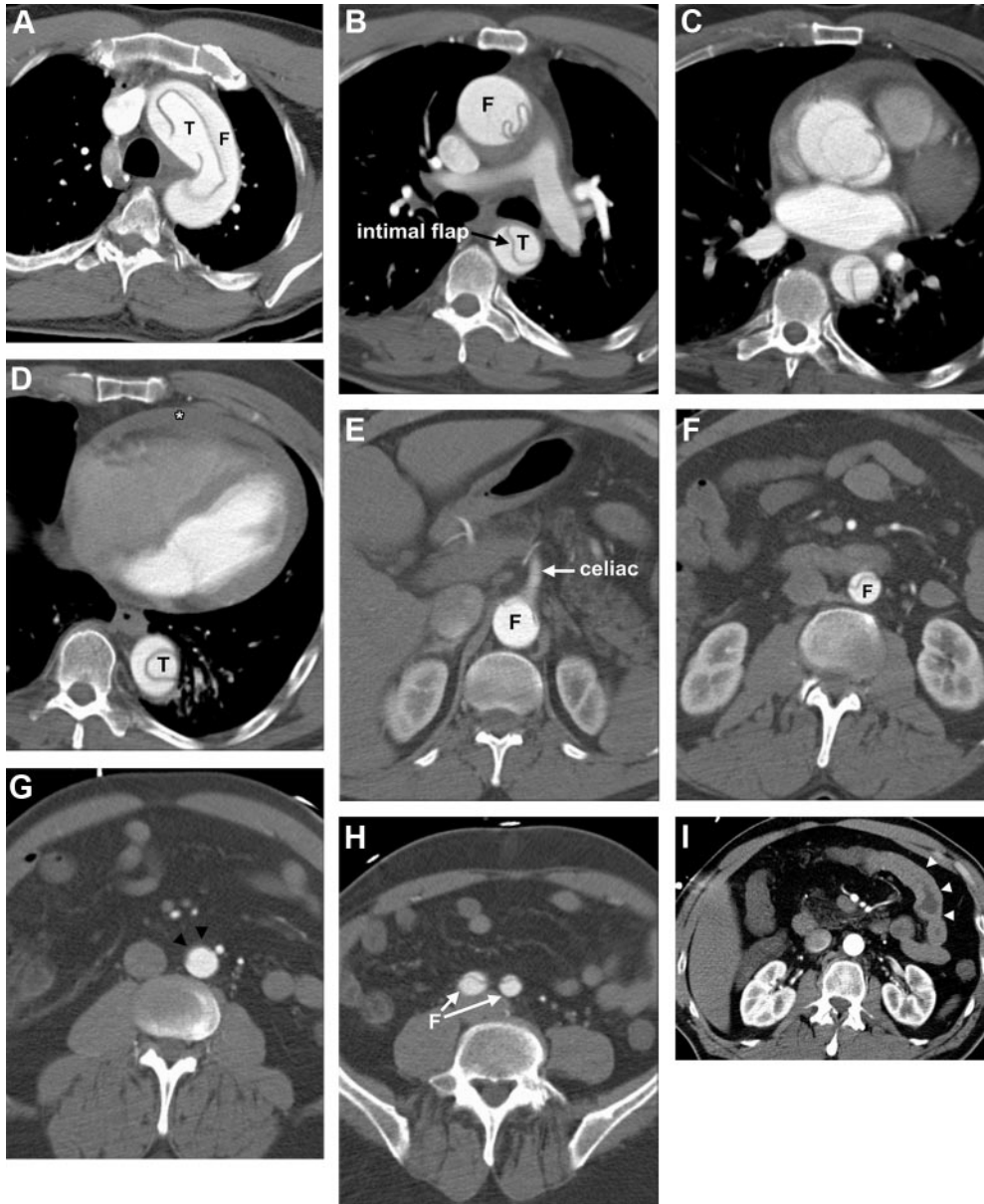
gency department alive, whereas for AoD, the prognosis appears to be worse, with 40% dying immediately, 1% per hour dying thereafter, and between 5% and 20% dying during or shortly after surgery.<sup>219–221</sup> Furthermore, only 50% to 70% will be alive 5 years after surgery depending on age and underlying etiology.<sup>222</sup> Because AoD tends to occur in areas of aneurysmal dilatation, treatment of aneurysms before dissection occurs is important to long-term survival<sup>3</sup> (see Section 8.1).

Regarding time from onset of initial symptoms to time of presentation, acute dissection is defined as occurring within 2 weeks of onset of pain; subacute, between 2 and 6 weeks from onset of pain; and chronic, more than 6 weeks from onset of pain.

#### 8.1.2. Anatomic Classification of Aortic Dissection

Anatomically, acute thoracic AoD can be classified according to either the origin of the intimal tear or whether the dissection involves the ascending aorta (regardless of the site of origin). Accurate classification is important as it drives decisions regarding surgical versus nonsurgical management. The 2 most





**Figure 18.** Type A aortic dissection and extent of involvement depicted on axial CT images from the cranial to caudal direction. Although the flap appears to disappear in the infrarenal, it is actually compressed against the anterior wall of the aorta in Panel G (arrowheads) and it is clearly present caudally in the common iliac arteries in Panel H. Hemopericardium (asterisk) is visible in Panel D. Bowel wall thickening (arrowheads) indicates ischemia in Panel I. Panel A, Aortic arch. Panel B, Mid thorax. Panel C, Aortic root. Panel D, Just above the diaphragm. Panel E, At the level of the celiac axis. Panel F, Mid kidneys. Panel G, Infrarenal aorta. Panel H, Proximal common iliac arteries. Panel I, Image through the mid abdomen at narrow window/level settings demonstrates small bowel wall thickening due to bowel ischemia caused by apposition of the flap against the origins of the celiac axis and superior and inferior mesenteric arteries. CT indicates computed tomographic imaging; F, false lumen; and T, true lumen.

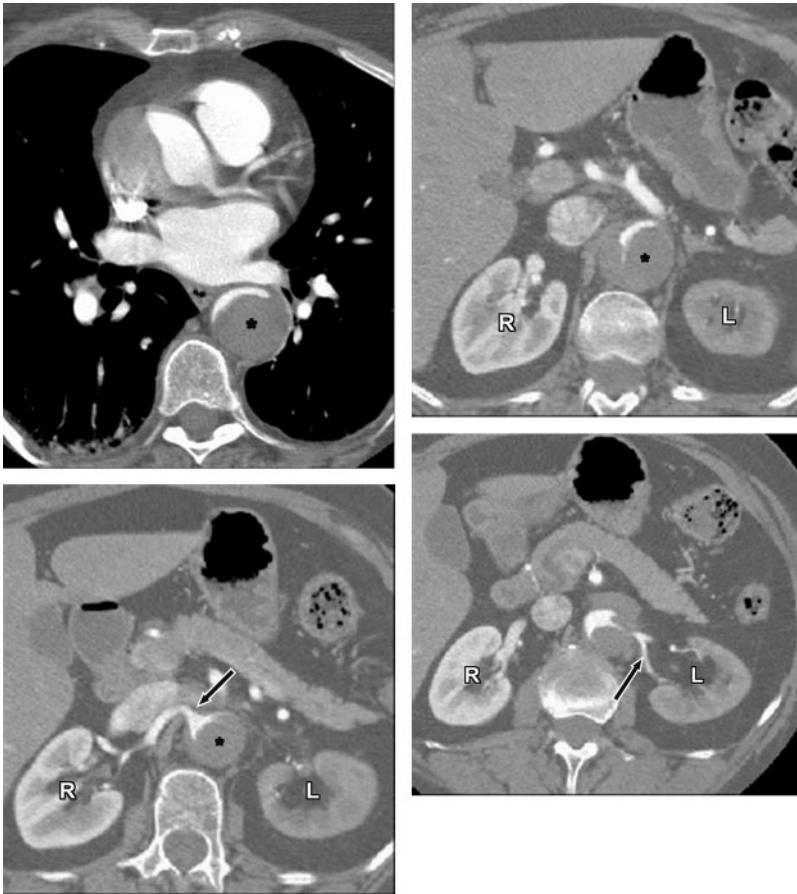
commonly used classification schemes are the DeBakey and the Stanford systems (Figure 20). For purposes of classification, the ascending aorta refers to the aorta proximal to the brachiocephalic artery, and the descending aorta refers to the aorta distal to the left subclavian artery.

The DeBakey classification system categorizes dissections based on the origin of the intimal tear and the extent of the dissection:

- Type I: Dissection originates in the ascending aorta and propagates distally to include at least the aortic arch and typically the descending aorta (surgery usually recommended).

- Type II: Dissection originates in and is confined to the ascending aorta (surgery usually recommended).
- Type III: Dissection originates in the descending aorta and propagates most often distally (nonsurgical treatment usually recommended).
  - Type IIIa: Limited to the descending thoracic aorta.
  - Type IIIb: Extending below the diaphragm.

The Stanford classification system divides dissections into 2 categories, those that involve the ascending aorta and those that do not.



**Figure 19.** Type A Aortic dissection with thrombosed false lumen and left renal artery involvement depicted on axial CT images. Demonstrates marked narrowing of the true lumen, patent right renal artery arising from the true lumen (bottom left, arrow), and narrow left renal artery compressed by thrombus in the false lumen, with secondary decreased enhancement of the left kidney compared with the right kidney. Top left, At the level of the left main coronary artery. Top right, At the celiac axis. Bottom left, At the right renal artery (arrow). Bottom right, At the left renal artery (arrow). \*Thrombus in false lumen. CT indicates computed tomographic imaging; L, left kidney; and R, right kidney.

- Type A: All dissections involving the ascending aorta regardless of the site of origin (surgery usually recommended) (Figures 18 and 20).
- Type B: All dissections that do not involve the ascending aorta (nonsurgical treatment usually recommended). Note involvement of the aortic arch without involvement of the ascending aorta in the Stanford classification is labeled as Type B (Figure 21).

At this time, there is no unanimity regarding which classification system is the ideal one to use. Some of the writing committee members believe that a more pragmatic approach is to refer to the dissection involving the aorta as either proximal or distal to the left subclavian artery. Others of the writing committee do not use this approach. Thus, if a patient has an arch dissection even without ascending aortic involvement, then immediate surgery would be recommended by some, if feasible and the patient is viable. Others on the writing committee would select medical management if the patient has only an arch dissection without proximal extension, malperfusion, or bleeding, as long as repeat imaging demonstrates stability. If there is evidence of malperfusion or bleeding in such a patient, then the writing committee would usually select a surgical approach.

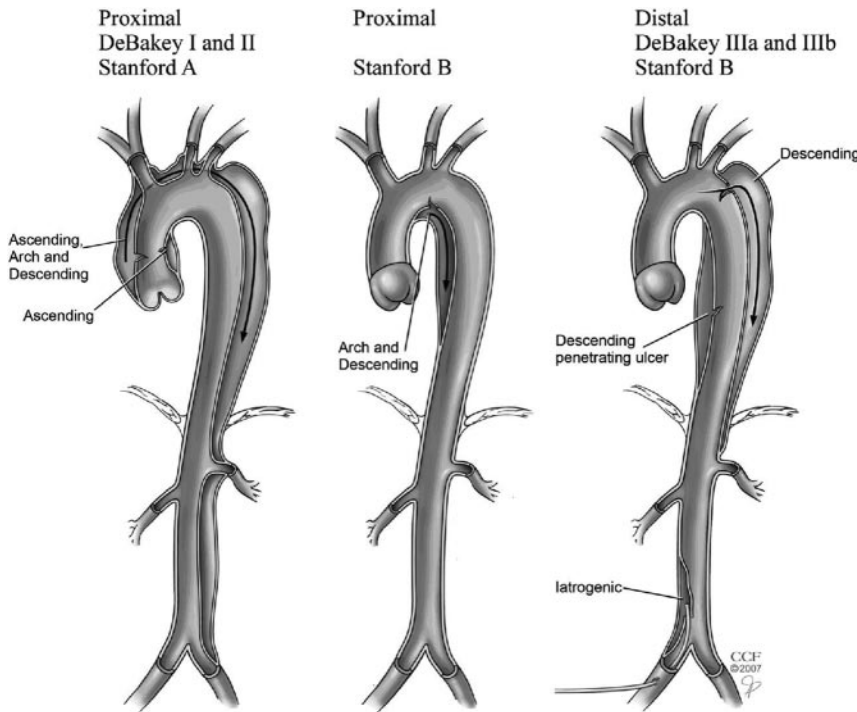
The intimal tear and AoD can also be categorized into classes that may have a bearing on treatment<sup>212,213</sup> (Figure 17).

### 8.1.3. Risk Factors for Aortic Dissection

Risk factors for AoD include conditions that result in aortic medial degeneration or place extreme stress on the aortic wall

(Table 9). Two thirds to three quarters of patients have hypertension, which is often uncontrolled. Genetic predisposition (see Section 5) to AoD can occur in the context of a syndrome, such as Marfan syndrome or Loeys-Dietz syndrome, or can be inherited in families in the absence of syndromic features.<sup>3</sup> IRAD data showed that of patients under 40 years of age with AoD, 50% had a history of Marfan syndrome.<sup>223</sup> Other congenital or genetically based diseases as well as inflammatory conditions associated with a higher risk of AoD are noted in Sections 6.3, 6.4, and 7.

First and foremost, a family history of thoracic aortic aneurysm is an important risk factor. In 2 separate clinical studies, 13% to 19% of patients without an identified genetic syndrome with thoracic aortic aneurysms had first-degree relatives with thoracic aortic aneurysms or AoD.<sup>127,130</sup> The term “familial thoracic aortic aneurysm and dissection syndrome” is often applied (see Section 5). In taking a history for thoracic aortic disease, one should be careful to distinguish a history of an *abdominal aortic aneurysm* from a *thoracic aortic aneurysm*. Many people, even healthcare providers, mistakenly use the terms *AAA* or *triple A* for any aortic aneurysm, regardless of location. Clarifying that the aneurysm was thoracic rather than abdominal affects one’s consideration of risk. Also, one must consider the potential underlying diagnosis when a patient reports a family history of “sudden death” or “heart attack” when there was no confirmatory autopsy. If the patient’s father, at the age of 45, had sudden onset of chest pain and then died moments later,



**Figure 20.** Aortic dissection classification: DeBakey and Stanford Classifications. Reprinted with permission from the Cleveland Clinic Foundation.

there is a chance that the death may have been from an acute AoD rather than an acute MI.

The history may reveal syndromic causes of thoracic aortic aneurysm and dissections, especially Marfan, Loeys-Dietz, and vascular Ehlers-Danlos syndromes. In some cases, patients have only some of the features of Marfan or Loeys-Dietz syndrome, rather than the full-blown clinical syndrome, so a history of any phenotypic features, such as mitral valve prolapse or pectus excavatum, should prompt consideration of thoracic aortic aneurysms or dissections.<sup>224,225</sup> Bicuspid aortic valve is a strong risk factor for ascending thoracic aortic aneurysms, as well as coarctation of the aorta. In addition, a history of extreme exertion or emotional distress may precede the onset of pain.<sup>226</sup>

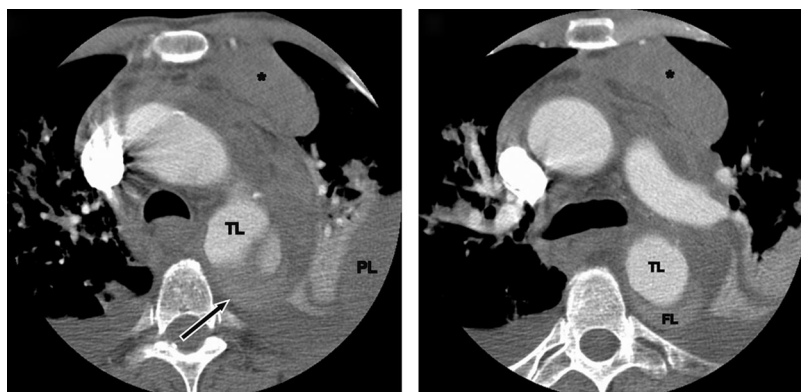**8.1.4. Clinical Presentation of Acute Thoracic Aortic Dissection**

The clinical presentation of acute AoD spans a spectrum from the overt with classic pain and physical examination findings to the enigmatic as a painless process with few physical manifestations of the disease (Table 10). Given its exceed-

ingly high mortality, clinicians must maintain a high index of suspicion for acute AoD, as noted in Section 8.6 (Figure 22).

**8.1.4.1. Symptoms of Acute Thoracic Aortic Dissection**

Patients with acute aortic syndromes often present in a similar fashion, regardless of whether the underlying condition is AoD, IMH, PAU, or contained aortic rupture. Pain is the most commonly reported presenting symptom of acute AoD regardless of patient age, sex, or other associated clinical complaint.<sup>228–235</sup> Pooled data from over 1000 patients in 8 studies found that the pain of acute dissection is perceived as abrupt in onset in 84% of cases (95% CI 80% to 89%) and of severe intensity in 90% of cases (95% CI 88% to 92%).<sup>236</sup> Although classically described as having a tearing or ripping quality, registry data suggest patients are more likely to describe the pain of acute dissection as sharp or stabbing (51% to 64%, respectively) and that report of a migrating quality to pain is highly variable (12% to 55%).<sup>228,236</sup> Pain may subsequently ease or abate, leading to a false reassurance on the part of the patients and physicians.



**Figure 21.** Type B aortic dissection with mediastinal hematoma and pleural blood. Ruptured Type B aortic dissection with mediastinal hematoma (\*) and pleural blood. Left, Flap arises in the proximal descending thoracic aorta, with faint contrast-enhanced blood adjacent to the site of rupture outside the confines of the aortic wall (arrow). Right, At the level of the aortopulmonary window. FL indicates false lumen; PL, pleural blood; and TL, true lumen.

**Table 9. Risk Factors for Development of Thoracic Aortic Dissection**

Conditions associated with increased aortic wall stress	
Hypertension, particularly if uncontrolled	
Pheochromocytoma	
Cocaine or other stimulant use	
Weight lifting or other Valsalva maneuver	
Trauma	
Deceleration or torsional injury (eg, motor vehicle crash, fall)	
Coarctation of the aorta	
Conditions associated with aortic media abnormalities	
Genetic	
Marfan syndrome	
Ehlers-Danlos syndrome, vascular form	
Bicuspid aortic valve (including prior aortic valve replacement)	
Turner syndrome	
Loeys-Dietz syndrome	
Familial thoracic aortic aneurysm and dissection syndrome	
Inflammatory vasculitides	
Takayasu arteritis	
Giant cell arteritis	
Behçet arteritis	
Other	
Pregnancy	
Polycystic kidney disease	
Chronic corticosteroid or immunosuppression agent administration	
Infections involving the aortic wall either from bacteremia or extension of adjacent infection	

Pain location and other associated symptoms reflect the site of initial intimal disruption and may change as the dissection extends along the aorta or involves other arteries or organ systems.<sup>236</sup> Data from 464 patients enrolled in IRAD found that patients with Type A dissections most frequently present with chest pain (80%), more commonly described as anterior (71%) than as posterior (32%).<sup>228</sup> Although less common, patients with Type A dissection report back pain (47%) and abdominal pain (21%), presumably as a result of antegrade dissection into the descending aorta.<sup>228</sup> In contrast, patients with Type B dissections are most likely to present with back pain (64%) followed by chest and abdominal pain (63% and 43%, respectively).<sup>228</sup> Some patients present with abdominal pain in the absence of chest pain or with only painful or numb lower extremities related to end-organ ischemia. In 1 retrospective study of 44 patients ultimately diagnosed with acute thoracic AoD, the location of the patient's pain was highly predictive of the clinician's suspicion for acute AoD; dissection was suspected in 86% of patients who presented with chest and back pain, 45% of those who presented with chest pain alone, and only 8% of those primarily abdominal pain.<sup>237</sup>

Although uncommon, acute AoD may present without pain.<sup>238–240</sup> In a separate analysis of 977 IRAD patients, 63

**Table 10. International Registry of Acute Aortic Dissection (IRAD) Physical Findings of 591 Patients With Type A Aortic Dissection**

Presenting Hemodynamics and Clinical Findings	Frequency/Finding
Hypertensive	32%
Normotensive	45%
Hypotensive	14%
Shock	13%
Cardiac tamponade	5%
Murmur of aortic insufficiency	45%
Pulse deficits	26%
Pericardial friction rub	2%
Cerebrovascular accident	8%
Ischemic peripheral neuropathy	3%
Ischemic spinal cord damage	2%
Ischemic lower extremity	10%
Coma/altered consciousness	12%
Congestive heart failure	5%
First blood pressure systolic, mean	130 mm Hg
First blood pressure diastolic, mean	75 mm Hg

Adapted from Pape et al.<sup>227</sup>

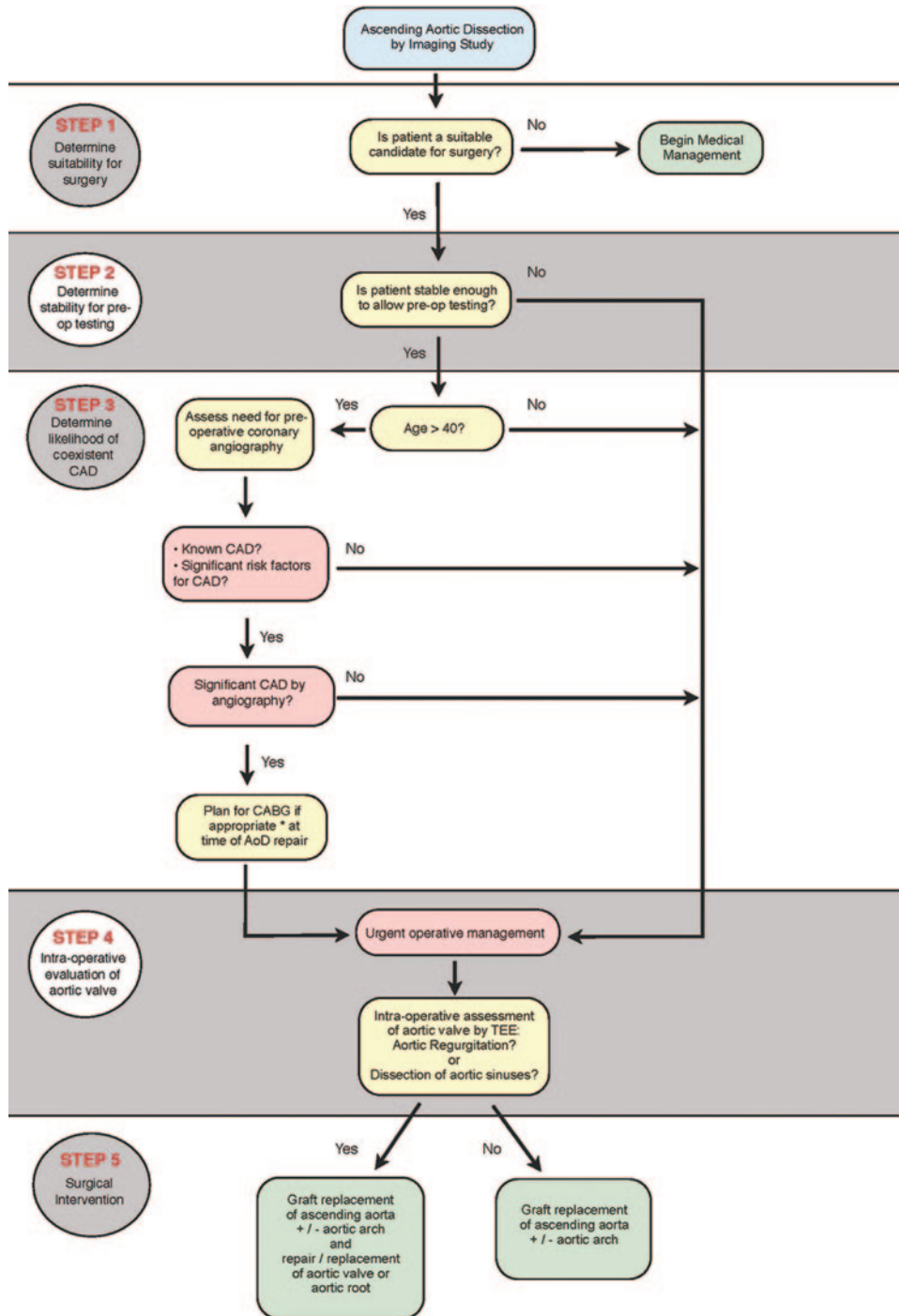
patients (6.4%) presented without pain.<sup>241,242</sup> This group of patients was noted to be older and more likely to present with syncope, stroke, or congestive heart failure than were patients with painful dissection.<sup>241</sup> Patients on steroids and patients with Marfan syndrome may be more prone to present without pain.<sup>243</sup>

*8.1.4.2. Perfusion Deficits and End-Organ Ischemia*

Perfusion deficits as a result of dissection-related obstruction of aortic branch vessels have long been recognized as a common clinical manifestation, resulting in organ complications at initial presentation (Table 11). End-organ involvement in acute thoracic AoD can occur via several mechanisms. Most occlusions are caused by obstruction by the dissection flap, which can either prolapse across a vessel origin without entering it (dynamic obstruction) or directly extend into a vessel (static obstruction)<sup>244</sup> (Figure 18). Other causes include postobstructive arterial thrombosis, embolism to branches of either the true or false lumen, direct compression of an aortic branch artery or adjacent structures by an expanding false lumen,<sup>245</sup> rupture or leakage of the false lumen into contiguous structures, and occlusion or dissection of coronary arteries and/or aortic valve distortion leading to heart failure.

Physical examination is insensitive to renal and mesenteric ischemia early in the course of acute AoD. Elevated serum creatinine or refractory hypertension may be due to renal ischemia but may represent the clinical baseline in a patient with poorly documented or inadequately treated prior medical conditions. Serologic markers of mesenteric ischemia may not be present until hours after onset.

Combined data from over 1500 patients in 16 studies found that pulse deficits were present in 31% of cases (95% CI 24%



**Figure 22.** Acute surgical management pathway for AoD. \*Addition of ‘if appropriate’ based on Patel et al.<sup>226a</sup> AoD indicates aortic dissection; CABG, coronary artery bypass graft surgery; CAD, coronary artery disease; TAD, thoracic aortic disease; and TEE, transesophageal echocardiogram.

to 39%) and, when present, were strongly suggestive of AoD (positive likelihood ratio 5.7; 95% CI 1.4 to 23)<sup>37</sup> and predict increased risk. Of 513 cases of Type A dissection, patients with perfusion deficits were more likely to present with hypotension, shock, neurologic deficits, and tamponade and were more likely to have higher rates of hospital complications and mortality (41% versus 25%,  $P=0.0002$ ).<sup>246</sup> Furthermore, overall mortality rates correlated with the number of

pulse deficits present, likely as a reflection of the extent of vascular compromise and associated end-organ ischemia.<sup>246</sup> Similarly, of 118 patients with Type A acute dissection, limb ischemia (defined as loss of pulse with associated pain and neurologic symptoms) was present in 38 cases (32%).<sup>247</sup> The presence of limb ischemia was associated with an increased likelihood of other end-organ ischemia (ie, cerebral, visceral, or coronary) and a significant increase in overall mortality.<sup>247</sup>

**Table 11. End-Organ Complications of Acute Aortic Dissection**

Type	End-Organ Complication
Cardiovascular	Aortic insufficiency
	Syncope
	Pericardial tamponade
	Myocardial ischemia or infarction
	Congestive heart failure
Neurologic	Ischemic stroke or transient ischemic attack
	Peripheral neuropathy
	Paraplegia/paraparesis
	Spinal ischemia
Pulmonary	Pleural effusion
	Aortopulmonary fistula with hemorrhage
Gastrointestinal	Mesenteric ischemia or infarction
	Aortoenteric fistula with hemorrhage
Renal	Renal failure
	Renal ischemia or infarction
Extremities	Limb ischemia

Among the 38 patients with limb ischemia, in-hospital mortality was 45% compared with 15% among the 61 patients without organ malperfusion.<sup>247</sup>

These studies underscore the clinical importance of an adequate vascular examination to help both identify the disease and stratify risk once the diagnosis is established. Every patient being evaluated for possible acute AoD should have pulses checked in all extremities to identify the presence of perfusion deficits. In patients with acute limb ischemia versus those without, renal and mesenteric malperfusion were nearly 2-fold more frequent and mortality was twice as high, further highlighting the importance of this finding.<sup>248</sup>

### 8.1.5. Cardiac Complications

The heart is the most frequently involved end organ in acute AoD involving the ascending aorta. In distinction to other end-organ pathology, most cardiac complications are a direct result of dissection-related disruption of normal anatomic relationships.<sup>215,245</sup>

#### 8.1.5.1. Acute Aortic Regurgitation

Acute aortic regurgitation is the most commonly recognized cardiac complication of Type A dissection,<sup>228–234</sup> occurring in 41% to 76% of cases.<sup>228–232</sup> Three distinct dissection-related mechanisms for acute aortic valve incompetence have been identified, and they can occur in combination: 1) acute dilatation of the aortic root by an expanding false lumen, resulting in incomplete aortic valve closure; 2) a dissection extending into the aortic root and disrupting aortic valve commissural attachments, resulting in valve leaflet prolapse; and 3) a portion of dissection flap prolapsing through the aortic valve in diastole, preventing adequate leaflet closure.<sup>235</sup> Clinical manifestations of dissection-related aortic regurgitation span the spectrum from only a hemodynamically insignificant diastolic murmur to congestive heart failure and cardiogenic shock.<sup>236,249</sup>

#### 8.1.5.2. Myocardial Ischemia or Infarction

Myocardial ischemia or infarction is an infrequent but serious complication of acute AoD. Registry and review data suggest that ECG evidence of myocardial ischemia was present in up to 19% of patients with acute AoD, whereas pooled data from 988 patients in 9 different studies found that acute MI was present in 7% of cases (95% CI 4% to 14%).<sup>37,47,250</sup> Coronary artery flow can be compromised by an expanding false lumen compressing the proximal coronary or by extension of the dissection flap into the coronary artery ostium.<sup>251</sup>

Clinically, a dissection-related cardiac malperfusion syndrome may present with ECG changes that are indistinguishable from those of primary myocardial ischemia or infarction, increasing the likelihood of misdiagnosis and inappropriate therapeutic intervention.<sup>252</sup>

#### 8.1.5.3. Heart Failure and Shock

Heart failure is a relatively uncommon complication of AoD, found to occur in approximately 6% of cases.<sup>236</sup> In this setting, heart failure may result from acute aortic insufficiency, acute myocardial ischemia or infarction, or cardiac tamponade. Registry data suggest that patients with acute AoD complicated by heart failure are often atypical in their presentation, frequently leading to a delay in diagnosis.<sup>236</sup> The largest study to evaluate heart failure in acute AoD included 1069 patients from the IRAD database and found that patients with AoD and concomitant heart failure were more likely to present in shock but were less likely to complain of chest pain and that, when chest pain was present, the pain was more often mild and less often abrupt in onset.<sup>236</sup>

#### 8.1.5.4. Pericardial Effusion and Tamponade

Pericardial pathology is a frequent complication of acute Type A AoD and can occur via 2 distinct mechanisms.<sup>37,253–256</sup> Most commonly, transudation of fluid across the thin wall of an adjacent false lumen into the pericardial space leads to a hemodynamically insignificant pericardial effusion,<sup>256</sup> which is present in about one third of patients.<sup>257</sup> Less often, the dissected aorta ruptures directly into the pericardium, leading rapidly to tamponade physiology and hemodynamic compromise.<sup>245,258,259</sup> Cardiac tamponade is diagnosed in 8% to 10% of patients presenting with acute Type A AoD and is an ominous clinical predictor of poor outcomes,<sup>260</sup> as well as the leading cause of mortality in this group.<sup>47,215,231</sup> Consequently, the presence of cardiac tamponade should prompt truly urgent aortic repair.<sup>260</sup>

#### 8.1.6. Syncope

Syncope is a well-recognized dissection-related complaint occurring in approximately 13% of cases<sup>242,261</sup> with multiple potential etiologies, including: 1) cardiac (eg, severe aortic regurgitation, ventricular outflow obstruction, cardiac tamponade), 2) vascular (eg, impaired cerebral blood flow and aortic baroreceptor activation); 3) neurologic (eg, vasovagal in response to pain), and 4) volume-related (eg, false lumen rupture into the pleural space) causes.<sup>240,261–267</sup> Regardless of its etiology, syncope in the setting of AoD increases the risk of near-term adverse events. In a review of 728 cases of acute AoD, patients with a history of syncope were significantly more likely to die than were those without syncope (34%

versus 23%, respectively;  $P=0.01$ ).<sup>242</sup> Additionally, patients who presented with syncope more frequently had associated cardiac tamponade, stroke, decreased consciousness, and evidence of spinal cord ischemia.<sup>242</sup>

### 8.1.7. Neurologic Complications

Acute AoD frequently presents with dissection-related neurologic complications. Pooled data from more than 1300 patients in 13 studies that included both Type A and B dissections found that neurologic symptoms were reported in 17%.<sup>37</sup> Neurologic complications may result from hypotension, malperfusion, distal thromboembolism, or nerve compression.<sup>251,253,254</sup> In a recent study of 102 patients with Type A AoD, 29% had neurologic symptoms on initial presentation<sup>253</sup>; of those with neurologic symptoms, 53% had ischemic stroke (predominantly right hemispheric) and 37% had ischemic neuropathy (described as limb pain with sensory or motor deficit).<sup>253</sup>

Last, although uncommon, acute paraplegia as a result of spinal cord malperfusion has been described as a primary manifestation of thoracic AoD, occurring in 1% to 3% of patients.<sup>215,251,253,254,268,269</sup>

Of clinical note, up to 50% of dissection-related neurologic symptoms may be transient and as many as one-third of patients with neurologic symptoms present without complaints of chest pain, complicating appropriate diagnosis and treatment.<sup>253,255,256,262,269–271</sup>

### 8.1.8. Pulmonary Complications

Pleural effusion, the most common pulmonary complication of acute AoD, is noted in 16% of cases at presentation<sup>37</sup>; whereas large effusions may result from leaking of blood from the aorta into the pleural space, small effusions are typically a nonhemorrhagic exudate believed to be inflammatory in origin.<sup>37,272–275</sup>

Other pulmonary complications of acute AoD include dissection-related compression of the pulmonary artery and development of an aortopulmonary fistula, either of which may present with dyspnea as a prominent symptom.<sup>276–278</sup> Hemoptysis, noted in 1 study in 3% of patients presenting with thoracic AoD, may result from compression of lung parenchyma by an expanding false lumen or via direct aneurysmal rupture into the lung, leading to massive hemoptysis and death.<sup>215,279,280</sup>

### 8.1.9. Gastrointestinal Complications

Mesenteric ischemia is the most common gastrointestinal complication of acute AoD<sup>228</sup> and can result from malperfusion or systemic hypotension. It is the most common cause of death among those with Type B AoD. Mesenteric ischemia is associated with abdominal pain, but pain may be nonspecific and out of proportion to the physical examination of the abdomen, so the cause of pain often goes unrecognized early on. Unfortunately, by the time serum markers of bowel ischemia or infarction turn positive, it is often too late to salvage the bowel or the patient. Therefore, it is essential to be vigilant for mesenteric ischemia in every patient with acute AoD and associated abdominal pain.

Gastrointestinal hemorrhage is a rare but potentially catastrophic complication of acute AoD.<sup>281–283</sup> Dissection-related

gastrointestinal bleeding may present with limited bleeding as a result of mesenteric infarction or as massive hemorrhage secondary to an aortoesophageal fistula or false lumen rupture into proximal small bowel.<sup>281–283</sup> Although rare, dissection-related gastrointestinal hemorrhage should be in the differential of all patients presenting with bleeding and complaints of thoracic or abdominal pain.

### 8.1.10. Blood Pressure and Heart Rate Considerations

Blood pressure abnormalities are common in patients presenting with acute thoracic AoD. About half of patients are hypertensive at presentation, with 71% of Type B patients having a systolic blood pressure greater than 150 mm Hg versus only 36% of Type A patients.<sup>284–287</sup> Conversely, nearly 20% present with either hypotension or shock.<sup>37</sup> Hypotension and shock can result from cardiac tamponade, aortic hemorrhage, severe aortic insufficiency, myocardial ischemia or infarction, true lumen compression by distended false lumen, or an intra-abdominal catastrophe. Of more than 1000 patients with acute AoD, those with hypotension on admission were found more likely to have neurologic complications; myocardial, mesenteric, or limb ischemia; and death.<sup>249</sup>

Accurate systemic blood pressure measurement may be complicated by dissection-related occlusion of aortic branch arteries, resulting in erroneously low blood pressure readings in the affected limb. Accordingly, blood pressures may need to be measured in both arms and, at times, both legs to determine the highest central blood pressure.

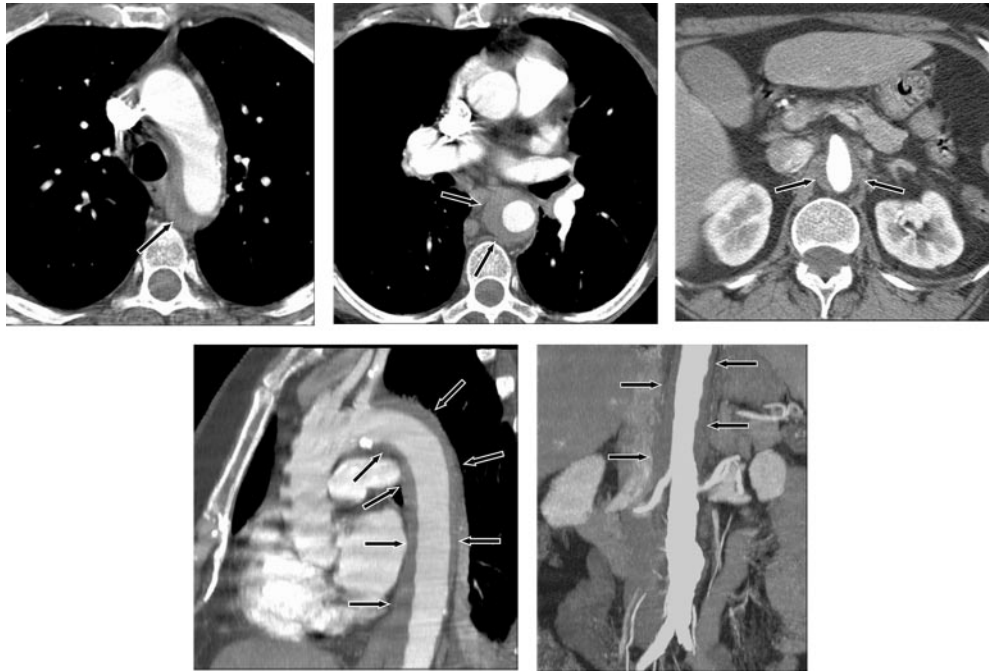
### 8.1.11. Age and Sex Considerations

Acute AoD presentation varies with patient age and sex. In 951 IRAD patients, 7% were younger than 40 years. Compared with patients 40 years of age and older, this group was less likely to have a history of hypertension and significantly more likely to have Marfan syndrome, bicuspid aortic valve, or a history of prior aortic surgery.<sup>223</sup> Clinically, young patients in this study were more likely to describe pain as abrupt in onset but less likely to be hypertensive at presentation (25% versus 45%).<sup>223</sup> In contrast, a separate study of IRAD data evaluating 550 patients with Type A dissection found that among patients more than 70 years of age (32% of total), typical symptoms (abrupt onset of pain) and signs (murmur of aortic regurgitation or pulse deficits) were significantly less common, suggesting that extra vigilance may be required to identify acute AoD in young and elderly patients.<sup>288</sup>

Sex appears to affect the presentation of acute AoD as well. In a study of 1078 patients enrolled in IRAD, 32% were women. Women were older; were less likely to present within 6 hours of symptom onset, to complain of abrupt onset of pain, and to have a pulse deficit; and were more likely to present with either altered mental status or congestive heart failure. Consequently, women were less likely to be diagnosed within 24 hours of symptom onset and had significantly higher in-hospital mortality (30% versus 21%,  $P=0.001$ ) than men.<sup>289</sup>

## 8.2. Intramural Hematoma

Among acute aortic syndromes, acute dissection is the most common, but approximately 10% to 20% of patients<sup>290–292</sup>



**Figure 23.** Intramural hematoma demonstrated as a low-attenuation band of hematoma (arrows) in the aortic wall on CT images. Top left, Axial image at the level of the aortic arch. Top middle, Through the mid thorax. Top right, At the level of the superior mesenteric artery with narrowing of the aortic lumen. Bottom left, Oblique sagittal reformatted image through the thorax (note band artifact evident without the use of ECG gating). Bottom right, Coronal reformatted image through the abdomen demonstrate the length of the hematoma, and an incidental infarenal aortic aneurysm. CT indicates computed tomographic imaging; and ECG, electrocardiogram.

with a clinical picture of dissection exhibit an IMH via imaging without identification of blood flow in a false lumen or an intimal lesion. Some believe IMH arises from hemorrhage of the vasa vasorum located within the medial layer of the aorta,<sup>293,294</sup> whereas others argue that the hematoma arises from microscopic tears in the aortic intima. The resulting hematoma may then propagate in an antegrade or a retrograde manner, producing symptoms that may be impossible to differentiate clinically from those of a classic AoD.<sup>61</sup> IMH has a variable radiologic appearance (Figure 23) according to the area of the aorta involved. In some cases, IMH may be associated with a PAU (see Section 8.2 or 8.3).

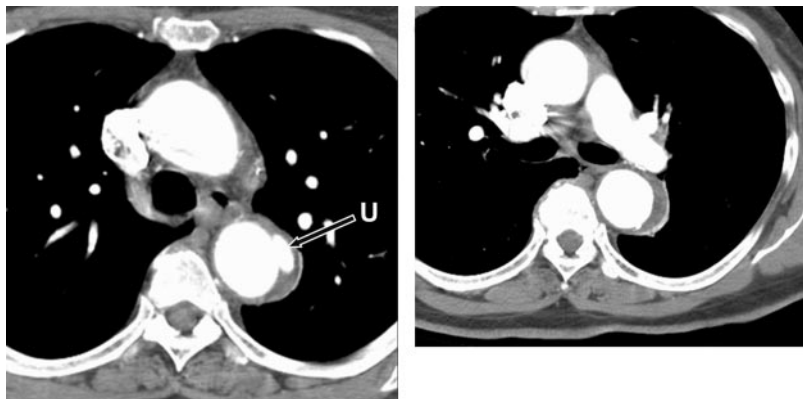
Clinically, IMH most commonly occurs in the descending aorta and in older patients. Pain is characteristic of IMH, whereas malperfusion and pulse deficit are much less likely than with classic AoD.<sup>295,296</sup>

Imaging criteria of IMH are based on the appearance of fresh thrombus in the aortic wall. These include crescentic or circular thickening of the aortic wall with maximal thickness greater than or equal to 7 mm on TEE without intimal flap or tear or longitudinal flow in the false lumen. The thickened wall has a higher tissue density than unenhanced blood on CT and is without enhancement after contrast on the CT/MR.<sup>290,296–298</sup> When the term IMH is used strictly, no intimal defect such as a tear or an ulcer is present. But in practice, the term is used loosely to mean a thrombosed false lumen regardless of a small intimal defect. The distinction is further blurred by the facts that the intimal defect may be subtle and difficult to exclude and that some patients with IMH begin with a CT scan that shows a thrombosed false lumen with no apparent intimal defect and then over the course of 1 or 2

months develop 1 or more distinct ulcerlike communications.<sup>299,300</sup> Because of this overlap in imaging findings, it is difficult and perhaps somewhat arbitrary to base treatment on the appearance of the CT snapshot of the aorta in its disease progression.

The natural history of IMH is variable. The hematoma may entirely resolve (10%),<sup>301</sup> it may convert to a classic dissection, or the aorta may enlarge and potentially rupture. The clinical behavior of IMH varies according to the location and mimics that of classic AoD. IMH involving the ascending aorta has a high, early risk of complication and death with medical treatment alone, and surgery is usually indicated. IMH involving the descending aorta may be treated with blood pressure control, and the use of beta blockers has been shown to improve the long-term survival rate.<sup>296</sup> Conversion of the IMH to a more classic picture of dissection occurs in 3% to 14% of cases involving the descending aorta<sup>297,298,302,303</sup> and in 11% to 88% of cases involving the ascending aorta,<sup>302–305</sup> with that figure increasing with increased length of follow-up. Progressive increase in aortic diameter has been demonstrated by serial imaging studies.<sup>298,306</sup> In 1 study, the mortality after 2 years of patients with acute proximal Type A IMH versus that of patients with classic dissection was not significantly different.<sup>307</sup> Another group found improved actuarial survival rates at 1, 2, and 5 years in patients with IMH versus classic dissection: 90%, 90%, and 90% versus 67%, 66%, and 62%, respectively, for Type A,<sup>304</sup> and 100%, 97%, and 97% versus 83%, 79%, and 79%, respectively, for Type B.<sup>297</sup> Song et al also described increased risk for complications or mortality for patients with IMH involving the ascending aorta when ascending aortic





**Figure 24.** Penetrating atherosclerotic ulcer of the proximal descending thoracic aorta. Axial CT images at the level of the aortopulmonary window (left) and at the level of the left pulmonary artery (right) demonstrate a small penetrating ulcer (long arrow, U) that extends beyond the expected confines of the aortic lumen with adjacent IMH both at the level of the ulcer itself and that extends a few centimeters caudally in the wall of the descending thoracic aorta (short arrows). CT indicates computed tomographic imaging; IMH, intramural hematoma; and U, penetrating ulcer.

diameter is greater than 4.8 cm or IMH thickness is greater than 11 mm.<sup>308</sup>

### 8.3. Penetrating Atherosclerotic Ulcer

PAU refers to an atherosclerotic lesion with ulceration that penetrates the internal elastic lamina and allows hematoma formation within the media of the aortic wall.<sup>309</sup> This lesion sets the stage for development of IMH, AoD, or frank vessel rupture<sup>309</sup> (Figure 24). Anatomically PAUs develop in aortic segments where atherosclerotic changes are most common and therefore are localized to the descending thoracic aorta in over 90% of cases.<sup>310</sup> When viewed tangentially, the classic appearance of the lesion is a mushroom-like outpouching of the aortic lumen with overhanging edges, resembling a gastric ulcer, as depicted on a barium study (Figure 24). The typical patient is elderly (usually over 65 years of age) and has hypertension and diffuse atherosclerosis, who presented with chest or back pain but without signs of aortic regurgitation or malperfusion. Less commonly, patients presented only with signs of distal embolization.<sup>311</sup> Asymptomatic patients may also be found with aortic lesions that are indistinguishable, by imaging criteria, from PAUs.<sup>310,311</sup>

Two entities can mimic PAUs. A branch artery pseudoaneurysm represents a small collection of flowing blood within an otherwise thrombosed aortic false lumen, which is created by an injury to a small branch artery during the propagation of the IMH.<sup>312</sup> These are usually incidental findings, are distinguished from ulcers by the apparent absence of a communication with the aortic lumen by CT, and do not usually require specific treatment. A dissection entry or reentry tear may develop in an area of IMH as detected by several imaging studies over a period of several months.<sup>297,299,300,306</sup>

### 8.4. Pseudoaneurysms of the Thoracic Aorta

Pseudoaneurysms of the thoracic aorta are frequently related to deceleration or torsional trauma to the aorta from motor vehicle accidents, falls, and sports injuries.<sup>3,313–319</sup> Aortic pseudoaneurysms are relatively rare, with posttraumatic pseudoaneurysms having an incidence of 3% to 4% after blunt trauma.<sup>51</sup> Other pseudoaneurysms may occur following aortic surgery, catheter-based interventions, or penetrating trauma. Pseudoaneurysms often have a slim “neck” that leads to the “aneurysm” that corresponds to points of penetration and containment.<sup>320</sup> Aortic infections (mycotic aneurysms)

and penetrating ulcers may also result in pseudoaneurysms (see Section 9.2.2). Penetrating injuries are usually repaired immediately whenever recognized and feasible.<sup>317,318,321</sup>

### 8.5. Traumatic Rupture of the Thoracic Aorta

A UK survey of all motor vehicle accident fatalities found that approximately 20% of patients had an autopsy finding of a ruptured aorta, emphasizing the importance of traumatic rupture of the aorta (TRA). In the United States, there are around 40 000 motor vehicle deaths annually, and it is likely that around 8000 of the victims had TRA. It is estimated that only 9% to 14% of patients with TRA reach a hospital alive and only 2% ultimately survive. In this survey, 29% were involved with frontal impact crashes and 44% were involved with side impact crashes.<sup>318,319</sup>

Parmley and colleagues<sup>318</sup> noted the correlation of high risk of early death and the sites of TRA on the basis of autopsies in 275 deaths from unrelated aortic rupture. In 45%, the tear was at the aortic isthmus; 23%, in the ascending aorta; 13%, in the descending aorta; 8%, in the transverse aorta; 5%, in the abdominal aorta; and 6%, multiple sites.

Examination of the patient usually reveals signs similar to those of coarctation of the aorta with arm blood pressure higher than leg blood pressure, delay between radial versus femoral artery pulsation, and a harsh interscapular murmur.<sup>3</sup> Evidence of polytrauma is, however, common.

The best method for detection of a TRA is debated. A chest x-ray with a nasogastric tube in position has 80% sensitivity for suggesting TRA by showing displacement of the nasogastric tube by the hematoma. However, signs of hemomediastinum are more often false positive than true positive.<sup>40</sup> Even when present, mediastinal blood is less likely to be due to arterial/aortic injury than to less-consequential venous bleeding. A biplane contrast aortogram may fail to detect the tear until the development of a pseudoaneurysm. TEE may be used, but if dilatation has not occurred, the diagnosis may still be in doubt. CT is used but is not absolutely certain to establish the diagnosis. In questionable cases, intravascular ultrasound can also be used<sup>3,322,323</sup> (Figure 8). Realistically, the imaging sequence often depends on the stability of the patient and the need for the diagnosis of concomitant injuries. Sometimes, this may even fail to detect the tear, and the study may have to be repeated at a later date to detect the tear.

## 8.6. Evaluation and Management of Acute Thoracic Aortic Disease

### 8.6.1. Initial Evaluation and Management

#### 8.6.1.1. Recommendations for Estimation of Pretest Risk of Thoracic Aortic Dissection

##### Class I

1. Providers should routinely evaluate any patient presenting with complaints that may represent acute thoracic aortic dissection to establish a pretest risk of disease that can then be used to guide diagnostic decisions. This process should include specific questions about medical history, family history, and pain features as well as a focused examination to identify findings that are associated with aortic dissection, including:
  - a. High-risk conditions and historical features<sup>47,127,223,261</sup> (*Level of Evidence: B*):
    - Marfan syndrome, Loeys-Dietz syndrome, vascular Ehlers-Danlos syndrome, Turner syndrome, or other connective tissue disease.
    - Patients with mutations in genes known to predispose to thoracic aortic aneurysms and dissection, such as *FBNI*, *TGFBR1*, *TGFBR2*, *ACTA2*, and *MYH11*.
    - Family history of aortic dissection or thoracic aortic aneurysm.
    - Known aortic valve disease.
    - Recent aortic manipulation (surgical or catheter-based).
    - Known thoracic aortic aneurysm.
  - b. High-risk chest, back, or abdominal pain features<sup>37,47,215,223,261,264,288</sup> (*Level of Evidence: B*):
    - Pain that is abrupt or instantaneous in onset.
    - Pain that is severe in intensity.
    - Pain that has a ripping, tearing, stabbing, or sharp quality.
  - c. High-risk examination features<sup>37,47,253,257,261,324</sup> (*Level of Evidence: B*):
    - Pulse deficit.
    - Systolic blood pressure limb differential greater than 20 mm Hg.
    - Focal neurologic deficit.
    - Murmur of aortic regurgitation (new).
2. Patients presenting with sudden onset of severe chest, back, and/or abdominal pain, particularly those less than 40 years of age, should be questioned about a history and examined for physical features of Marfan syndrome, Loeys-Dietz syndrome, vascular Ehlers-Danlos syndrome, Turner syndrome, or other connective tissue disorder associated with thoracic aortic disease.<sup>223</sup> (*Level of Evidence: B*)
3. Patients presenting with sudden onset of severe chest, back, and/or abdominal pain should be questioned about a history of aortic pathology in immediate family members as there is a strong familial component to acute thoracic aortic disease.<sup>223</sup> (*Level of Evidence: B*)

4. Patients presenting with sudden onset of severe chest, back, and/or abdominal pain should be questioned about recent aortic manipulation (surgical or catheter-based) or a known history of aortic valvular disease, as these factors predispose to acute aortic dissection. (*Level of Evidence: C*)
5. In patients with suspected or confirmed aortic dissection who have experienced a syncopal episode, a focused examination should be performed to identify associated neurologic injury or the presence of pericardial tamponade (see Section 8.1.6). (*Level of Evidence: C*)
6. All patients presenting with acute neurologic complaints should be questioned about the presence of chest, back, and/or abdominal pain and checked for peripheral pulse deficits as patients with dissection-related neurologic pathology are less likely to report thoracic pain than the typical aortic dissection patient<sup>253</sup> (see Section 8.1.7). (*Level of Evidence: C*)

#### 8.6.1.2. Laboratory Testing

Several plasma markers have been investigated for their utility in the evaluation of acute AoD. Plasma smooth muscle myosin heavy chain protein, D-dimer, and high-sensitivity C-reactive protein have shown diagnostic promise, although a lack of large prospective studies precludes a recommendation regarding their use.<sup>325–328</sup>

Elevation of D-dimer levels occurs with intravascular activation of the coagulation cascade and secondary fibrinolysis and in conditions such as venous thromboembolism, sepsis, disseminated intravascular coagulation, malignancies, recent trauma or surgery, and acute MI and following fibrinolytic therapy. The ACEP has published guidelines regarding the use of certain D-dimer assays to rule out pulmonary embolism in low-risk patients.<sup>329</sup>

Regarding the potential role of plasma D-dimer levels to screen for AoD, significant elevations of D-dimer were seen in all 24 patients with documented acute AoD involving either the ascending or descending thoracic aorta regardless of time from presentation, ranging from 1 to 120 hours.<sup>325</sup> A meta-analysis of 11 studies<sup>330</sup> noted that the pooled sensitivity of D-dimer in 349 patients with documented acute AoD was 94% (95% CI 91% to 96%) with specificity ranging from 40% to 100%. Two patients had limited ascending aortic IMH without intimal flap and had negative D-dimer assays.<sup>331</sup>

Some authors<sup>325,332</sup> recommend that D-dimer assays be performed in all patients where clinical suspicion exists, to help identify those who do not require definitive imaging studies. However, the efficacy and safety of this strategy have not been tested in a large clinical trial, and several caveats should apply. The negative likelihood ratio provided by the most sensitive D-dimer assay is not of sufficient magnitude to provide useful information in high-risk individuals and therefore cannot be used to “rule out” the disease in this group. Clinical scoring systems to identify the true pretest probability for AoD in individual patients have not been developed or validated, thus limiting an accurate determination of the true “posttest” probability associated with a negative D-dimer result. Finally, there are reports of negative D-dimer assays

associated with ascending aortic IMH or a thrombosed false lumen, such that further studies are needed regarding the sensitivity of D-dimer levels to detect the presence of IMH or PAU.<sup>331</sup> Given these issues, the writing committee cannot recommend serum D-dimer screening for all patients being evaluated for AoD.

Where a high level of suspicion for acute AoD exists, laboratory testing aimed at presurgical screening (blood count, serum chemistries, coagulation profiles, and blood type and screen) may reduce preoperative delays.

#### 8.6.1.3. Recommendations for Screening Tests

##### Class I

1. An electrocardiogram should be obtained on all patients who present with symptoms that may represent acute thoracic aortic dissection.
  - a. Given the relative infrequency of dissection-related coronary artery occlusion, the presence of ST-segment elevation suggestive of myocardial infarction should be treated as a primary cardiac event without delay for definitive aortic imaging unless the patient is at high risk for aortic dissection.<sup>37,47,333</sup> (*Level of Evidence: B*)
2. The role of chest x-ray in the evaluation of possible thoracic aortic disease should be directed by the patient's pretest risk of disease as follows:
  - a. Intermediate risk: Chest x-ray should be performed on all intermediate-risk patients, as it may establish a clear alternate diagnosis that will obviate the need for definitive aortic imaging. (*Level of Evidence: C*)
  - b. Low risk: Chest x-ray should be performed on all low-risk patients, as it may either establish an alternative diagnosis or demonstrate findings that are suggestive of thoracic aortic disease, indicating the need for urgent definitive aortic imaging. (*Level of Evidence: C*)
3. Urgent and definitive imaging of the aorta using transesophageal echocardiogram, computed tomographic imaging, or magnetic resonance imaging is recommended to identify or exclude thoracic aortic dissection in patients at high risk for the disease by initial screening.<sup>42–46,67,73</sup> (*Level of Evidence: B*)

##### Class III

1. A negative chest x-ray should not delay definitive aortic imaging in patients determined to be high risk for aortic dissection by initial screening. (*Level of Evidence: C*)

#### 8.6.1.4. Recommendations for Diagnostic Imaging Studies

##### Class I

1. Selection of a specific imaging modality to identify or exclude aortic dissection should be based on patient variables and institutional capabilities, including immediate availability. (*Level of Evidence: C*)

2. If a high clinical suspicion exists for acute aortic dissection but initial aortic imaging is negative, a second imaging study should be obtained.<sup>212</sup> (*Level of Evidence: C*)

#### 8.6.1.5. Recommendations for Initial Management

##### Class I

1. Initial management of thoracic aortic dissection should be directed at decreasing aortic wall stress by controlling heart rate and blood pressure as follows:
  - a. In the absence of contraindications, intravenous beta blockade should be initiated and titrated to a target heart rate of 60 beats per minute or less. (*Level of Evidence: C*)
  - b. In patients with clear contraindications to beta blockade, nondihydropyridine calcium channel-blocking agents should be used as an alternative for rate control. (*Level of Evidence: C*)
  - c. If systolic blood pressures remain greater than 120 mm Hg after adequate heart rate control has been obtained, then angiotensin-converting enzyme inhibitors and/or other vasodilators should be administered intravenously to further reduce blood pressure that maintains adequate end-organ perfusion. (*Level of Evidence: C*)
  - d. Beta blockers should be used cautiously in the setting of acute aortic regurgitation because they will block the compensatory tachycardia.<sup>5</sup> (*Level of Evidence: C*)

##### Class III

1. Vasodilator therapy should not be initiated prior to rate control so as to avoid associated reflex tachycardia that may increase aortic wall stress, leading to propagation or expansion of a thoracic aortic dissection. (*Level of Evidence: C*)

#### 8.6.1.6. Recommendations for Definitive Management

##### Class I

1. Urgent surgical consultation should be obtained for all patients diagnosed with thoracic aortic dissection regardless of the anatomic location (ascending versus descending) as soon as the diagnosis is made or highly suspected. (*Level of Evidence: C*)
2. Acute thoracic aortic dissection involving the ascending aorta should be urgently evaluated for emergent surgical repair because of the high risk of associated life-threatening complications such as rupture.<sup>47</sup> (*Level of Evidence: B*)
3. Acute thoracic aortic dissection involving the descending aorta should be managed medically unless life-threatening complications develop (eg, malperfusion syndrome, progression of dissection, enlarging aneurysm, inability to control blood pressure or symptoms).<sup>285,288,334–337</sup> (*Level of Evidence: B*)

Early identification of acute thoracic dissection is challenging. During the initial evaluation, the correct diagnosis of

AoD has been made in only 15% to 43% of patients initially thought to have the disease.<sup>215,237,252</sup> Factors that may impede accurate diagnosis of AoD include the following:

1. Acute AoD is often believed to be a rare disease (2.9 to 3.5 cases per 100 000 person-years),<sup>215,217</sup> whereas the incidence of acute MI is several orders of magnitude greater (more than 200 cases per 100 000 person-years).<sup>338</sup> Data previously cited in this guideline from UHC suggest that acute AoD is not “rare.” Some common explanations that clinicians give for this underlying belief include the following:
  - a. It is difficult for clinicians to effectively separate patients with AoD from the multitude of other patients who present to emergency departments and primary care physicians with common complaints that are much more often not due to acute AoD.
  - b. Front-line medical providers may have little direct experience with acute AoD and are unlikely to be aware of the subtleties of its presenting signs and symptoms.
  - c. Institutional multidisciplinary pathways developed for other emergencies such as ST-elevation myocardial infarction (STEMI) or acute stroke have not generally existed for acute AoD.
2. In contrast to other more common cardiovascular emergencies, acute AoD may occur in younger patients. Accurate identification of acute AoD; however, requires that clinicians recognize on a routine basis that the disease may present in younger patients. Case reports exist of children as young as 3 years of age presenting with acute AoD.<sup>105</sup>
3. Acute AoD may present with a wide range of unusual manifestations that do not conform with classic “textbook findings.”<sup>339–341</sup>
4. There are no well-studied, rapidly available, and effective screening tests for acute AoD.

### 8.6.2. Evaluation and Management Algorithms

The provided algorithms guide the initial evaluation of patients whose presentations are concerning for AoD and the management of patients in whom the diagnosis of acute thoracic AoD is confirmed. Although clinicians may ultimately choose to deviate from the pathway for patient-specific reasons, the algorithms provide a framework with which to quickly diagnose (Figure 25) and provide early management (Figure 26) of AoD. This decision model is supported by several large studies that indicate a targeted history and physical examination are likely to identify the vast majority of patients who present with acute AoD, suggesting that adequate screening need not be time intensive or technology dependent.<sup>47,215,264</sup> Using a target history and physical examination, patients can be placed into 1 of 3 categories: 1) those with immediately apparent acute AoD requiring emergent surgical evaluation and expedited aortic imaging, 2) those whose presentation is concerning for acute AoD and in the absence of a clear alternative diagnosis require expedited aortic imaging, and 3) those whose clinical presentation is not initially suggestive of acute AoD but may benefit from aortic imaging in the absence of a likely alternative diagnosis at the completion of the initial evaluation.

Several high-risk conditions (Figure 25, T2–1) greatly increase the likelihood that presenting complaints that could be a result of acute AoD.

Pain (Figure 25, T2–2) is the most commonly reported presenting symptom of acute AoD regardless of patient age, sex, or other associated clinical complaint.<sup>37,47,215,223,242,264,289</sup> Pain described as abrupt or instantaneous in onset, that is severe in intensity, or that has a ripping or tearing quality establishes a high pretest probability for AoD.<sup>47,261</sup>

The combination of 2 or more high-risk features (Figure 25, T3) is strongly suggestive of acute AoD.

The presence of a single high-risk feature (ie, high-risk condition, pain, or physical examination) may trigger immediate concern for acute AoD; however, other diagnostic considerations may exist. Pain with high-risk features, although suggestive of acute AoD, may occur as a result of an alternate disease process (Table 12). For patients who are determined to have an intermediate probability of acute AoD on the basis of initial bedside assessment, Figure 25, T4, provides a pathway for further evaluation.

Figure 25, T5, provides a pathway for further evaluation of patients without any high risk features. Delay in diagnosis and increased mortality is common in this group.<sup>241,288,289</sup>

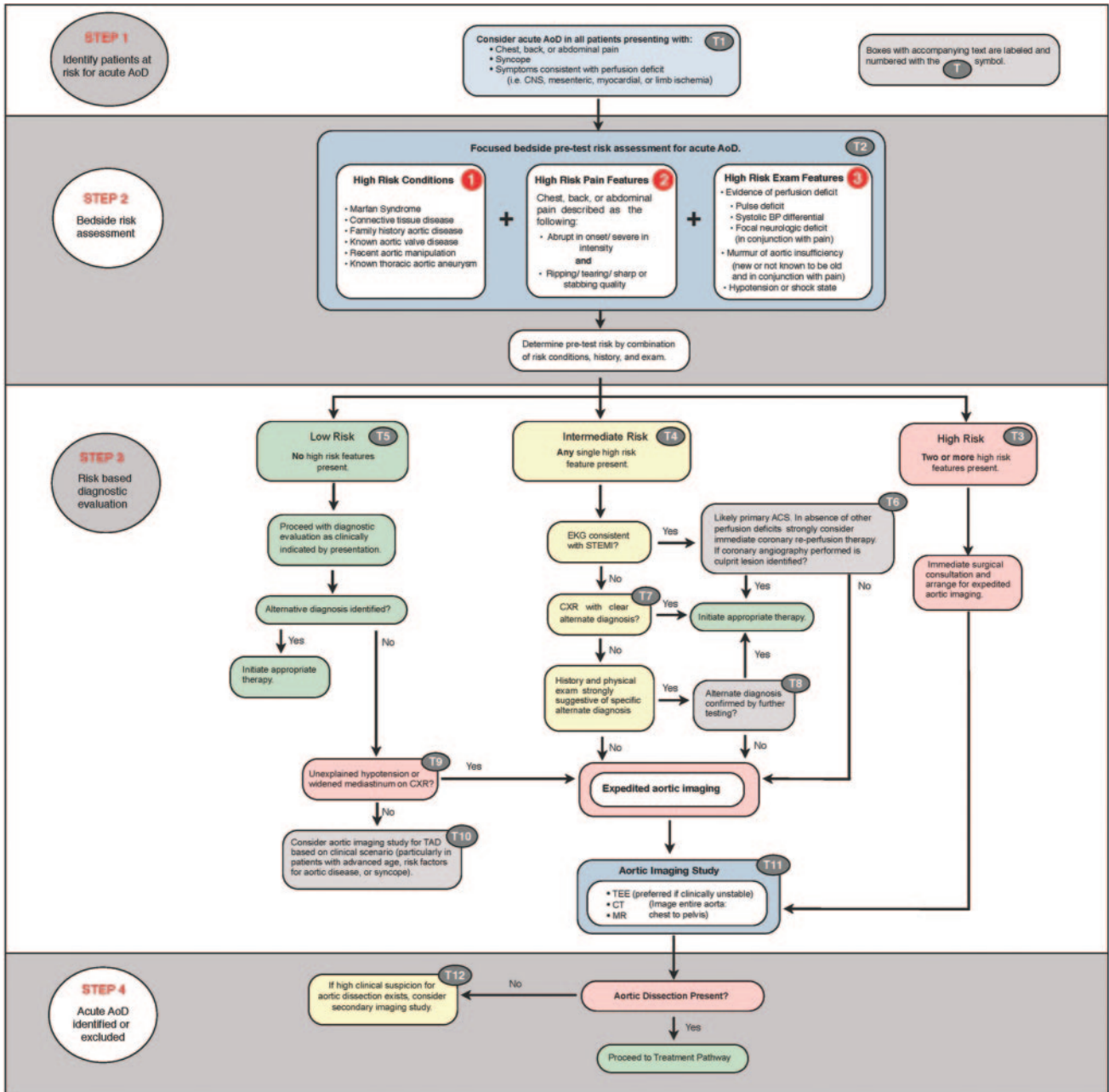
For patients presenting with new ST-segment elevations on the initial ECG and without high-risk AoD features, immediate coronary angiography and reperfusion therapy (ie, thrombolysis or percutaneous coronary intervention) are indicated.<sup>333</sup> However, if coronary angiography is performed and no culprit coronary lesion is identified, then Figure 25, T6, provides a pathway to dedicated aortic imaging. As approximately 40% of chest films in acute AoD lack a widened mediastinum, and as many as 16% are normal, the absence of radiographic abnormalities does not exclude the diagnosis of AoD<sup>37,47</sup> (Figure 25, T7).

Missed or delayed diagnosis of acute AoD is most commonly ascribed to an incorrect working diagnosis of acute coronary syndrome, a condition that may require a prolonged time interval to correctly identify (ie, serial cardiac biomarkers) and whose management with antiplatelet and antithrombin agents may cause harm to the patient with AoD. For patients with an intermediate-risk profile for acute AoD and who do not have diagnostic STEMI but who are being evaluated for a possible acute coronary syndrome, aortic imaging may detect AoD prior to the administration of antiplatelet and antithrombin agents (Figure 25, T8).

Unexplained hypotension is present in approximately 20% of patients with acute AoD.<sup>37,47</sup> Similarly, a widened mediastinum on chest x-ray strongly suggests the need for additional definitive diagnostic aortic imaging, particularly in patients without a clear alternative explanation for their presenting complaint<sup>342</sup> (Figure 25, T9).

Some patients with acute AoD present without any high-risk features, making early diagnosis difficult. If a clear alternative diagnosis is not established after the initial evaluation, then obtaining a diagnostic aortic imaging study, particularly in patients with advanced age (older than 70 years), syncope, focal neurologic deficit, or recent aortic manipulation (surgery or catheter based), should be considered<sup>47,242,253,288,343</sup> (Figure 25, T10).

Multidetector CT, TEE, and MR all provide acceptable diagnostic accuracy for the diagnosis of acute AoD. In patients with hemodynamic instability, requiring close mon-



**Figure 25.** AoD evaluation pathway. ACS indicates acute coronary syndrome; AoD, aortic dissection; BP, blood pressure; CNS, central nervous system; CT, computed tomographic imaging; CXR, chest x-ray; EKG, electrocardiogram; MR, magnetic resonance imaging; STEMI, ST-elevation myocardial infarction; TAD; thoracic aortic disease; and TEE, transesophageal echocardiogram.

iting, bedside TEE is preferred to avoid moving the patient out of the acute care environment (Figure 25, T11).

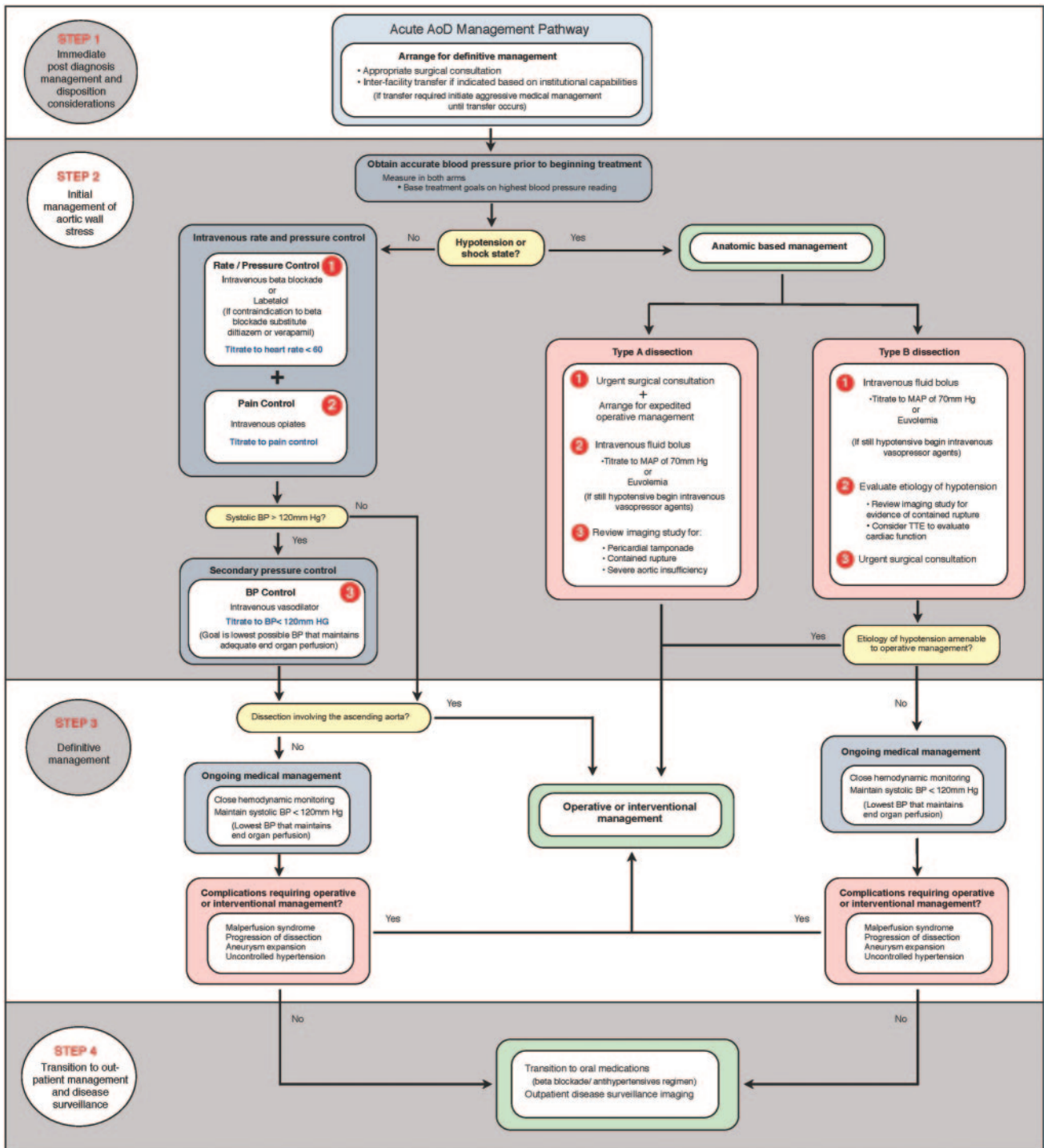
The most recent comparative study with nonhelical CT, 0.5 Tesla MR and TEE showed 100% sensitivity for all modalities, with better specificity of CT (100%) than for TEE and MR.<sup>44</sup> A recent meta-analysis that evaluated the diagnostic accuracy of TEE, helical CT, and MR for suspected AoD found that all 3 imaging techniques provided equally reliable diagnostic values.<sup>46</sup> Accordingly, selection of an imaging modality is influenced by individual patient variables and institutional capabilities.

The diagnosis of acute AoD cannot be excluded definitively based on the results of a single imaging study.

Although TEE, CT, and MR are all highly accurate for the evaluation of acute AoD; false-negative studies can and do occur<sup>47</sup> (Figures 9 and 15). If a high clinical suspicion exists for acute AoD but initial aortic imaging is negative, strongly consider obtaining a second imaging study (Figure 25, T12).

**8.6.3. Initial Management**

Once the diagnosis of AoD or one of its anatomic variants (IMH or PAU) is obtained, initial management is directed at limiting propagation of the false lumen by controlling aortic shear stress while simultaneously determining which patients will benefit from surgical or endovascular repair (Figure 26).



**Figure 26.** Acute AoD management pathway. AoD indicates aortic dissection; BP, blood pressure; MAP, mean arterial pressure; and TTE, transthoracic echocardiogram.

**8.6.3.1. Blood Pressure and Rate Control Therapy**  
 Aortic wall stress is affected by the velocity of ventricular contraction (dP/dt), the rate of ventricular contraction, and blood pressure. Initial medical stabilization using beta blockers controls these 3 parameters by reducing heart rate and blood pressure to the lowest amounts that will still maintain adequate end-organ perfusion.<sup>61</sup> Reasonable initial targets are a heart rate less than 60 bpm and a systolic blood pressure between 100 and 120 mm Hg.<sup>61</sup>

Intravenous propranolol, metoprolol, labetalol, or esmolol is an excellent choice for initial treatment. In patients who have a potential contraindication to beta blockade (eg, those with asthma, congestive heart failure, or chronic obstructive pulmonary disease), esmolol may be a viable option given its extremely short half-life. Use of labetalol, which is both an alpha- and beta-receptor antagonist, offers the advantage of potent heart rate and blood pressure control from a single agent, potentially eliminating the need for a secondary

**Table 12. Differential Diagnosis for High-Risk Pain or Examination Features**

## Chest pain

- Acute myocardial infarction
- Pulmonary embolism
- Spontaneous pneumothorax
- Esophageal rupture

## Abdominal pain

- Renal/biliary colic
- Bowel obstruction/perforation
- Non-dissection-related mesenteric ischemia

## Back pain

- Renal colic
- Musculoskeletal pain
- Intervertebral disk herniation

## Pulse deficit

- Non-dissection-related embolic phenomena
- Non-dissection-related arterial occlusion

## Focal neurologic deficit

- Primary ischemic cerebrovascular accident
- Cauda equina syndrome

vasodilator. In patients who are unable to tolerate beta blockade, nondihydropyridine calcium channel antagonists (verapamil, diltiazem) offer an acceptable, although less-established, alternative.<sup>61</sup> Beta blockers, verapamil, or diltiazem for rate control in patients with significant aortic regurgitation may be problematic because of deleterious effects on reflex tachycardia.

*8.6.3.2. Additional Antihypertensive Therapy*

It is frequently difficult to reduce blood pressure to optimum levels.<sup>285–287,344–346</sup> In 1 study, patients required a median of 4 different antihypertensive drugs.<sup>347</sup> In addition to beta blockade, vasodilators may be required to control blood pressure. Intravenous sodium nitroprusside is the most established agent and offers the advantage of being rapidly titratable.<sup>61</sup> Nicardipine,<sup>348</sup> nitroglycerin, fenoldopam, and various other intravenous antihypertensive agents are appropriate for this situation. Vasodilator therapy without prior beta blockade may cause reflex tachycardia and increased force of ventricular contraction leading to greater aortic wall stress and potentially causing false lumen propagation.<sup>42</sup> Following initial stabilization with intravenous antihypertensives, most patients will require long-term antihypertensive treatment including the use of a beta blocker plus additional classes of agents. Angiotensin-converting enzyme inhibitors or angiotensin receptor blockers may retard aortic dilatation and their use may be indicated as outlined in Section 9.2.1.1.

*8.6.3.3. Pain Control*

Adequate pain control is essential in the setting of acute AoD to decrease sympathetic mediated increases in heart rate and blood pressure. Appropriate use of intravenous opiate anal-

gesia will help augment the effects of rate control and vasodilator agents.

*8.6.3.4. Hypotension*

Medical management options for all forms of dissection-related hypotension are limited. Volume administration titrated to improvement of blood pressure is a reasonable first approach. Vasopressors can be added, if needed, to maintain adequate perfusion but have the potential to cause further false lumen propagation. Inotropic agents are likely to increase the force and rate of ventricular contraction and therefore increase sheer stress on the aortic wall.

Pericardiocentesis for dissection-related hemopericardium has been associated with recurrent pericardial bleeding and associated mortality.<sup>307,349,350</sup> Several articles from the Asian literature suggest that pericardiocentesis may be safe in the setting of acute Type A IMH.<sup>351,352</sup> Other cardiac complications that may result in hypotension include severe dissection-related aortic regurgitation, true lumen obstruction by a compressing false lumen, and acute MI. All require definitive operative management. Hypotension or shock in the setting of AoD may also result from contained rupture of the false lumen into adjacent structures (ie, pleural space or mediastinum), a scenario that also mandates immediate operative intervention.

Ultimately, hypotension or shock in the acute AoD patient suggests the need for immediate operative management. For patients with hemopericardium and cardiac tamponade who cannot survive until surgery, pericardiocentesis can be performed by withdrawing just enough fluid to restore perfusion.

*8.6.3.5. Determining Definitive Management*

In the clinically stable patient, the decision for surgical versus medical management of patients with acute AoD is based primarily on the location of the dissection as described by the Stanford and DeBakey classification systems<sup>61,353</sup> (see Section 8.1.2). A prompt cardiac surgical consultation provides the best management resource, regardless of location of the AoD, as it is impossible to predict which complications may develop or when they may occur.

*8.6.4. Recommendation for Surgical Intervention for Acute Thoracic Aortic Dissection***Class I**

- 1. For patients with ascending thoracic aortic dissection, all of the aneurysmal aorta and the proximal extent of the dissection should be resected. A partially dissected aortic root may be repaired with aortic valve resuspension. Extensive dissection of the aortic root should be treated with aortic root replacement with a composite graft or with a valve sparing root replacement. If a DeBakey Type II dissection is present, the entire dissected aorta should be replaced. (Level of Evidence: C)**

When a Type A AoD involves the aortic root, resuspension of the valve with preservation of the aortic sinuses and excision of the sinuses and resuspension of the valve within a polyester graft are suitable options. If the aortic root is dilated, or if there is extensive dissection and disruption of the

aortic sinuses, replacement with a composite graft is necessary.

#### 8.6.5. Endovascular Interventions

Endovascular stent grafts are not approved for AoD involving the ascending aorta or aortic arch. Endovascular stent grafts used for descending thoracic aortic dissection is discussed in Section 9.2.2.3.1. Indications for either surgical or endovascular interventions are discussed in Section 9.

#### 8.6.6. Principles of Treatment for Intramural Hematoma and Penetrating Atherosclerotic Ulcer

The goals of treatment are to prevent aortic rupture or progression to classic AoD, allow patient stabilization before urgent surgery, and reduce complexity of unavoidable aortic surgery. Aggressive medical treatment usually includes, particularly in symptomatic patients, beta blockers and other antihypertensive therapy. Indications for open or endograft treatment are based on the anatomic features of the lesion, clinical presentation and course, patient comorbidities, and anatomic constraints related to endograft technology. Treatment by endografts or open aortic reconstruction can be discussed in the context of 3 overlapping aortic lesions: intimal defect without IMH, intimal defect with IMH, and IMH without an intimal defect.

##### 8.6.6.1. Intimal Defect Without Intramural Hematoma

These are localized lesions and may involve a limited segment of the aorta. They are often an incidental finding. By imaging criteria, they include uncomplicated aortic ulcers, blebs, and eccentric or saccular aneurysms of the aorta. They are treated as saccular aneurysms based on their maximum diameter and clinical feature.<sup>212,306,354</sup> These lesions can be treated with open reconstruction and are the most suitable of the 3 groups for treatment by endografts, if in the descending thoracic aorta. They involve a limited segment, which can easily be excluded from the circulation, as long as there is an adequate distance from a critical branch artery. When these limited dissections involve the ascending aorta, emergency surgery is indicated as for other types of AoD because rupture or cardiac tamponade can occur.<sup>212,306,354</sup>

##### 8.6.6.2. Intimal Defect With Intramural Hematoma

The intimal defect again presents a target lesion for endovascular treatment in the descending thoracic aorta, but the associated IMH involves a longer segment of aorta than the first category. If the patient becomes asymptomatic in response to aggressive medical treatment, it may be possible to delay endovascular or open reconstruction until the IMH has reabsorbed and organized. (Of note, some writing committee members have observed healing of IMH such that immediate reconstruction was not required but have continued to follow that small number of patients closely.) Two considerations affect the length of aorta bordering the intimal defect, which is to be included in the segment targeted for treatment. Evidence of adjacent atheromatous wall should favor more extensive treatment of the aorta with longer endografts, because radiographic imaging underestimates shallow ulcerated atheromas, and the ulcer typically arises in a bed of atheromatous intima. Treatment with longer endografts provides a safety margin against undertreating the intimal defect.

The second consideration is the extent of associated IMH. The self-expanding endograft may tear through the intimal surface into underlying thrombosed false lumen. When treatment of this lesion in the acute stage is clinically necessary (eg, persisting pain, evidence for expansion or rupture, compromise of critical branches), it is preferable to anchor the endograft in the noninvolved wall above and below the intimal defect.

##### 8.6.6.3. Recommendation for Intramural Hematoma Without Intimal Defect

#### Class IIa

- 1. It is reasonable to treat intramural hematoma similar to aortic dissection in the corresponding segment of the aorta. (Level of Evidence: C)**

As noted earlier, some authors suggest treating IMH as an AoD in the corresponding aortic territory. Others recommend invasive treatment regardless of location or aortic diameter.<sup>354</sup> However, small patient series, incomplete anatomic description of case material, and lack of explicit anatomic or clinical guidelines indicating open or endovascular aortic repair make it difficult to generalize from the literature.

The absence of an intimal defect, which can serve as a target lesion, presents a diagnostic as well as treatment challenge. Intimal tears can be extremely subtle, depending on the size of the intimal tear and the amount of intramedial thrombus, which can sometimes fill the cavity flush with the aortic lumen. The intimal tear may be remote in the aorta despite leaking into the chest. IMH in a normal caliber aorta without an apparent intimal tear precludes limited treatment of a target lesion. There are no data supporting prophylactic implantation of endografts covering the entire descending aorta, yet in unusual circumstances one may be forced to propose such treatment. IMH in an aneurysmal aorta presents a particularly urgent problem, because this complication may be a precursor to aneurysm rupture. Although the literature gives no compelling guidelines for treatment, the writing committee believes that treatment of IMH corresponding to treatment of AoD in the corresponding segment of the aorta is reasonable.

#### 8.7. Treatment for the Management of Traumatic Aortic Rupture

The management of blunt TRA is evolving.<sup>3,318,319,355,356</sup> On the basis of the report by Parmley and colleagues,<sup>318</sup> most surgeons have recommended immediate surgical repair. However, when other serious traumatic injuries are present including head injuries and long bone or pelvic fractures, immediate surgery may not be feasible or may be dangerous. Multiple studies appear to show that if careful blood pressure control is used, many patients can be treated initially conservatively and then undergo operation once their other injuries have been stabilized.<sup>3,321,357–359</sup> In a review by Svensson et al<sup>359</sup> of 44 patients initially treated with careful blood pressure control who subsequently had delayed open surgery, there were no operative deaths. This approach has also been reported as being safe by Pate and colleagues and oth-



ers.<sup>3,321,357,358</sup> Thus, in selected patients at high risk for other injuries and bleeding, delayed repair of traumatic contained rupture of the aorta may be an option.

The open surgical repair of TRA has evolved over time. In a meta-analysis of 596 TRA patients by Svensson et al,<sup>359</sup> the highest mortality rate was noted with cardiopulmonary bypass (16.7%), the rate was less with shunts (11.4%), and the rate was lowest with a simple “clamp and sew” approach (5.8%,  $P < 0.01$ ). There was no difference in the risk of postoperative paralysis. Subsequently, von Oppell and colleagues<sup>360</sup> reviewed 1742 patients and found the risk of death was 18.2% with cardiopulmonary bypass, 11.9% for distal perfusion with atriopulmonary bypass, 12.3% for shunts, and 16% for the “clamp and sew” method. The respective paralysis rates were 2.4%, 1.7%, 11.1%, and 19.2%, respectively. The key factor in open repairs has been to keep the total aorta cross-clamp time to as short a period as possible, especially less than 45 minutes.<sup>3,359,361–364</sup>

The latest evolution in managing TRA is the use of endovascular deployed graft covered stents. Although endovascular stent grafting has not been prospectively studied for this clinical scenario, US Food and Drug Administration–approved devices are being used “off label,” with considerable success reported based on retrospective studies. In a collected series of 284 patients reported in the literature, Lettinga-van de Poll and colleagues reported the procedure-related mortality was 1.5%, 6.7% had endoleaks, and 14.4% had procedure-related complications.<sup>358,365–370</sup> In a multicenter study of 30 patients with 100% implantation success, 6% to 7% of patients died, 1 had a stroke (3.3%), and 1 had partial stent collapse (3.3%).<sup>370</sup> Reporting bias of favorable results may be an issue regarding interpretation of the safety and efficacy of this approach.

The problems with endovascular grafting for TRA have included the need to cover the left subclavian artery; the acute sharp angle of the distal aortic arch, particularly in young patients; and the lack of sufficiently small prostheses for use in young patients. The size and angle problem can result in the “bird beak” deformity, where the proximal edge of the stent is not in contact with the aortic wall and can result in lifting or collapse of the stent<sup>366</sup> (Figure 27). Similarly, when the stent graft is larger than the aortic diameter, enfolding of the stent and collapse can occur. On cross-sectional views, the stent graft has the appearance of a diagrammatic heart.

Over time, it is hoped newer iterations of endografts will be developed that are better able to accommodate the angulation of the distal arch and are smaller. It is unlikely that a prospective randomized study will be performed for this because of the small number of patients who make it to any surgical center and because initial results with endografting of TRA, with exception of the problems listed earlier, have been reasonable. The Expert Opinion Committee of the Society of Thoracic Surgeons and the American Association of Thoracic Surgeons suggested that both acute and chronic ruptures be considered for treatment with endografts. Some measures of caution must be taken because these are young patients who may be subjected to cumulative radiation

exposure with multiple CT scans and because the long-term durability of endovascular stent grafts is not known.<sup>371</sup>

## 9. Thoracic Aortic Aneurysms

Most thoracic aortic aneurysms are caused by degenerative disease resulting in dilatation of the aorta (Figure 28). The incidence of thoracic aortic aneurysms is estimated to be increasing and there are around 10.4 cases per 100 000 person-years.<sup>372</sup>

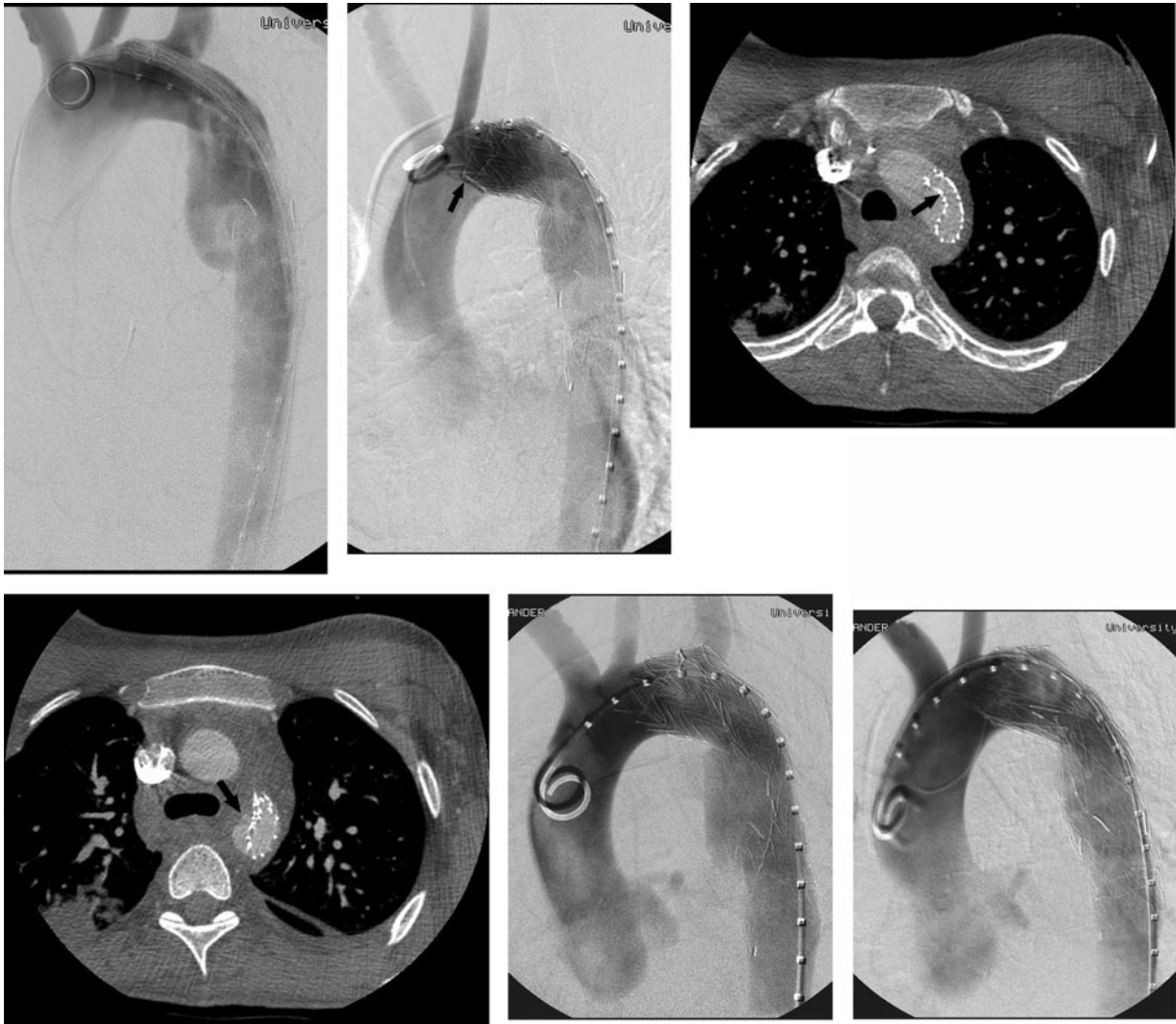Risk factors for development of thoracic aortic aneurysms include hypertension, smoking, and chronic obstructive pulmonary disease. In addition, several genetic syndromes with a predisposition for thoracic aortic aneurysms have been identified and are listed in Section 5. Thoracic aortic aneurysms are also associated with bicuspid aortic valve (see Section 6.1) and other congenital cardiovascular anomalies (see Section 6) and inflammatory diseases (see Section 7). Some thoracic aortic aneurysms are due to an inheritance of a predisposition for the disease, termed familial thoracic aortic aneurysm syndrome (see Section 5.1.6), and still others are idiopathic.

Many patients with a thoracic aortic aneurysm are asymptomatic and diagnosed by chest x-ray or CT scan obtained for other reasons. An aneurysm may cause compressive symptoms on adjacent structures including hoarseness, from left recurrent laryngeal nerve stretching; stridor, from tracheal or bronchial compression; dyspnea, from lung compression; dysphagia, from esophageal compression; and plethora and edema, from superior vena cava compression. Aortic valve regurgitation may develop due to aortic root or ascending aortic dilatation and result in heart failure. Neck and jaw pain may occur with aortic arch aneurysms, whereas back, interscapular, and/or left shoulder pain may occur with descending thoracic aortic aneurysms. Embolization of atherosclerotic debris with end-organ symptoms may occur. Finally, acute syndromes including dissection or rupture without dissection may occur with potentially catastrophic outcomes as described in Section 8.5.

Thoracic aortic aneurysms may involve different segments of the aorta. The ascending thoracic aorta and/or root is most commonly involved, with the descending aorta involved less often. Involvement of the aortic arch occurs in only 10%. The etiology, natural history, and treatments differ somewhat for aneurysms in each location. In Marfan syndrome, aneurysms typically arise in the aortic root, a process often referred to as *annuloaortic ectasia*. Because the leaflets of the aortic valve are suspended within the root, successful repair of the aortic root may require performance of a valve-sparing root repair or, in some cases, a composite aortic graft.

The average rate of expansion of thoracic aortic aneurysms is estimated to be 0.10 to 0.42 cm/y.<sup>373–375</sup> Medical and surgical treatment considerations and selection criteria are noted in Section 9.2.

A leaking or ruptured aneurysm (see Section 9.1.2.1) may also present as chest pain with hypotension due to



**Figure 27.** Beaking of thoracic endoprosthesis. Top left, Baseline thoracic aortography in left anterior oblique projection shows a traumatic pseudoaneurysm several cm distal to the left subclavian artery. Aortic diameter proximal to the left subclavian artery measured 23 mm, and distal to the pseudoaneurysm measured 21 mm. Top middle, Thoracic aortography following deployment of a 23-mm-diameter cuff distally and a 26 mm × 10 cm thoracic endograft proximally. Considerable beaking of the leading edge of the endograft is present (arrow), with lack of conformity of the proximal endograft with the tight inner curve of the aortic arch. The left subclavian artery was covered intentionally to exclude the pseudoaneurysm, which does not opacify. Top right, CT examination of the chest 2 days following implantation of the endografts shows collapse of the leading edge of the endograft (arrow). Bottom left, On a CT slice several centimeters more caudally, the endograft remains collapsed posterolaterally, resulting in revascularization of the pseudoaneurysm (arrow). Bottom middle, Thoracic aortography confirms posterior collapse of the endograft and reopening of the pseudoaneurysm. Bottom right, After placement of a self-expanding z-stent in the proximal endograft and reballoning of the endoprosthesis, the endograft has been reexpanded and the pseudoaneurysm was once again excluded. Although beaking persists, the endograft has remained fully expanded and the pseudoaneurysm has remained excluded for 3 years of follow-up. CT indicates computed tomographic imaging.

hemorrhage into the left or right pleural space or pericardium<sup>376</sup>; an aorto-esophageal fistula may manifest as gastrointestinal hemorrhage.<sup>377</sup> An unusual manifestation reported is a hemoptysis from a ruptured ascending aortic aneurysm eroding into the left lung bronchus.<sup>378</sup>

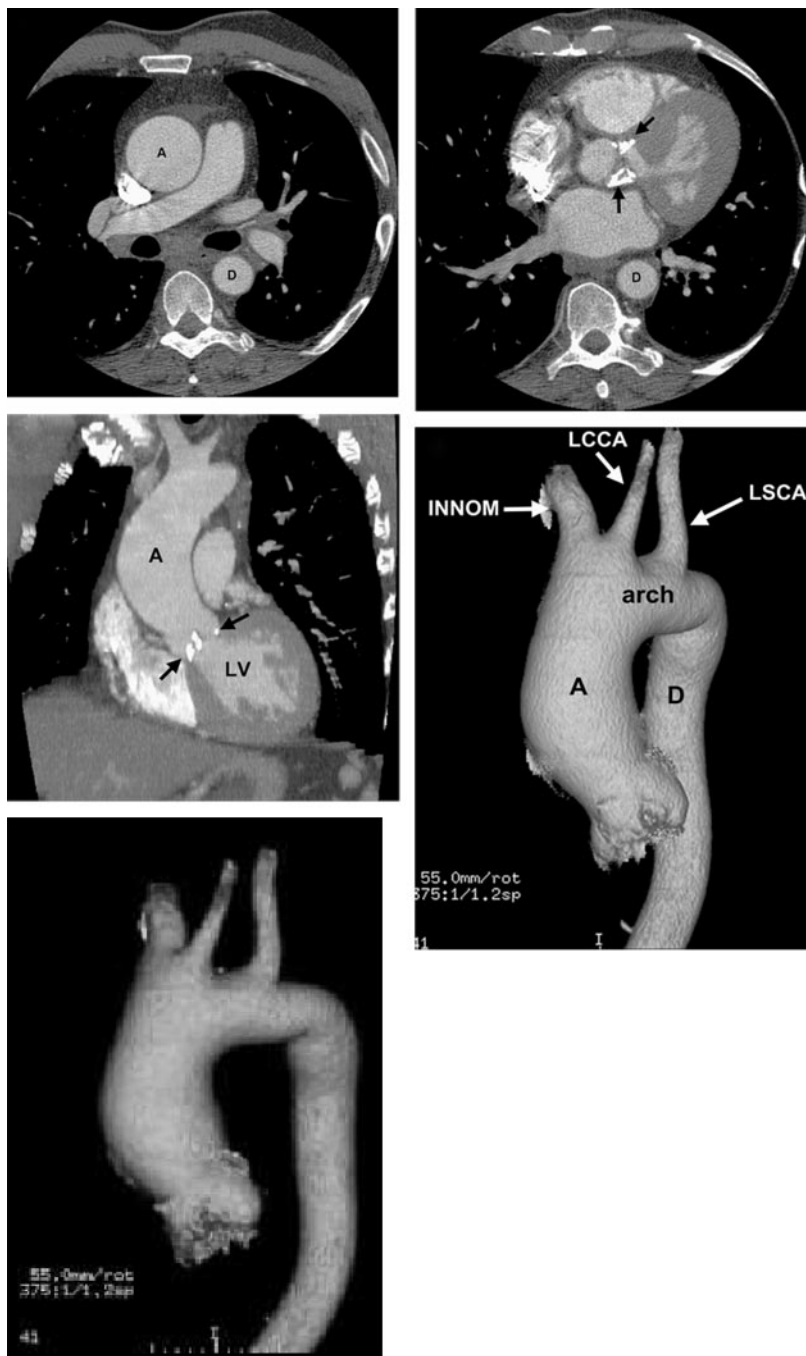
Further anatomic classifications refer to segments of the descending thoracic aorta and thoracoabdominal aorta divided into subsections according to the extent of the disease that is replaced at the time of surgery. These extents have an important influence on the risk of death and complications after surgery or stenting (Figure 29) (see Section 9.2.2.3).

## 9.1. General Approach to the Patient

### 9.1.1. Recommendation for History and Physical Examination for Thoracic Aortic Disease

#### Class I

1. For patients presenting with a history of acute cardiac and noncardiac symptoms associated with a significant likelihood of thoracic aortic disease, the clinician should perform a focused physical examination, including a careful and complete search for arterial perfusion differentials in both upper and lower extremities, evidence of visceral ischemia, focal neurologic defi-



**Figure 28.** Ascending thoracic aortic aneurysm in a patient with calcific aortic stenosis. Top left, Axial CT image demonstrates an enlarged ascending thoracic aorta (A) and normal caliber descending thoracic aorta (D). Top right, Axial CT image demonstrates extensive aortic valve leaflet calcification (arrows). Middle left, Coronal CT image also demonstrates the dilated ascending aorta (A) and aortic valve leaflet calcification (arrows). Middle right, Volume rendered CT image demonstrates the dilated ascending thoracic aorta (A), normal caliber aortic arch and descending thoracic aorta (D) and great vessels with a bovine arch configuration (INN, LCCA, LSCA). Bottom, Volume rendered rotating image of the thoracic aorta can be used to depict the anatomy, particularly the relationship of an aortic abnormality to the great vessels, for surgical planning. The full cine video for the bottom panel is available in the online-only Data Supplement at <http://circ.ahajournals.org/cgi/content/full/CIR.0b013e3181d4739e/DC1>. CT indicates computed tomographic imaging; INN, innominate artery; LCCA, left common carotid artery; LSCA, left subclavian artery; and LV, left ventricle.

**cits, a murmur of aortic regurgitation, bruits, and findings compatible with possible cardiac tamponade.**<sup>339–341</sup> (Level of Evidence: C)

The physical findings of thoracic aortic diseases may be subtle indirect manifestations of uncommon underlying genetically predisposing conditions. In evaluating the evidence base for physical examination of patients with thoracic aortic disease, there are no controlled or blinded experimental research studies that have stratified patients into different treatment categories based on physical findings.

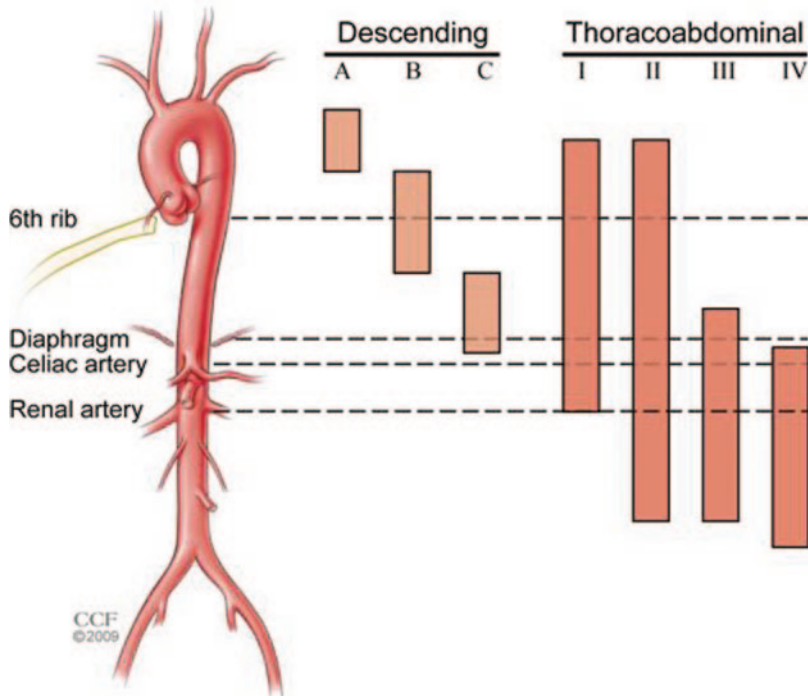
For all patients with thoracic aortic disease, the first and foremost issue is to identify those who are acutely at risk

for catastrophic harm as early as possible. Establishing a set of “triggers” or “red flags” may serve as alerts to either exclude or identify life-threatening thoracic aortic disease.

Given the growing awareness of an extensive variety of diseases associated with nonemergent thoracic aortic disease, it is important to be aware of the many different physical findings associated with extracardiovascular etiologies particularly those of genetic origin (see Section 5).

#### 9.1.1.1. Coronary Artery Disease

The frequency of coexisting CAD varies widely among patient subgroups with thoracic aortic disease as does the



**Figure 29.** Descending aneurysm classification. Descending aneurysms are classified as involving thirds of the descending thoracic aorta and various combinations. A involves the proximal third, B the middle third, and C as the distal third. Thus, an aneurysm involving the proximal two thirds is an AB extent aneurysm. Practically, these groupings can be combined into proximal or distal aneurysm, because these extents influence the risk of paralysis after either open or endovascular repairs. Thoracoabdominal aneurysms are classified according to the Crawford classification: Type I extends from proximal to the sixth rib and extends down to the renal arteries. Type II extends from proximal to the sixth rib and extends to below the renal arteries. Type III extends from distal to the sixth rib but from above the diaphragm into the abdominal aorta. Type IV extends from below the diaphragm and involves the entire visceral aortic segment and most of the abdominal aorta. Juxtarenal and supraaortic aneurysms are excluded.<sup>379–382</sup> Image reprinted with permission from the Cleveland Clinic Foundation.

etiology of the coronary artery abnormalities, if present. Patients with atherosclerotic aneurysms of the descending aorta are at elevated risk for coronary atherosclerosis, particularly if they have multiple atherosclerotic risk factors. While patients with Type A dissection or annuloaortic ectasia may be protected from atherosclerosis,<sup>383</sup> patients with Takayasu arteritis may occasionally have inflammatory coronary involvement with coronary aneurysms (less than 10%).<sup>384,385</sup> Similarly, an occasional patient with GCA may have coronary artery involvement.<sup>386,387</sup> If ascending aortic surgery is being considered, with or without aortic valve surgery, then identification of the coronary anatomy and any underlying CAD is important for planning the best operation.

#### 9.1.1.2. Emboli

Embolization of material thrombus, atheromatous debris, or cholesterol crystals may affect any distal arterial bed (see Section 11.3). Embolization may occur in patients with thoracic aortic aneurysms or atheromas and in those who have undergone angiography, major vessel surgery, or thrombolytic therapy.<sup>388–397</sup> Clinical consequences of such embolization vary considerably, from being completely asymptomatic to presenting with acute multiorgan failure, including progressive renal failure or cutaneous involvement, with a mortality rate as high as 70% to 90%.<sup>398</sup>

#### 9.1.1.3. Associated Renal Ischemia

Renal complications of thoracic aortic disease may be acute, subacute, and chronic.<sup>399</sup> Patients may present with severe abdominal or flank pain, hematuria, fever, nausea, or a combination of these signs and symptoms.<sup>400</sup>

#### 9.1.1.4. Associated Mesenteric Ischemia

Patients with acute intestinal ischemia have severe abdominal pain that is initially out of proportion to physical findings.<sup>401</sup> Hours to days later, peritonitis and sepsis correlate with

intestinal perforation. Findings suggestive of intestinal ischemia as well as specific arterial or venous obstruction require further surgical or vascular specialist evaluation.<sup>402–406</sup>

#### 9.1.1.5. Associated Peripheral Ischemia

Acute limb ischemia results in pain, pallor, paraesthesias, and paralysis.<sup>4</sup> Noninvasive vascular diagnostic testing (eg, ankle- and toe-brachial indices, segmental pressure measurements, pulse volume recordings, duplex ultrasound imaging, and Doppler waveform analysis) may document ischemia with additional use of angiographic imaging when necessary.<sup>407</sup>

### 9.1.2. Differential Diagnosis

#### 9.1.2.1. Symptoms

Symptoms are most commonly related to pain or discomfort. Particularly large thoracic aneurysms may be associated with chest discomfort. Rarely, dysphagia (dysphagia lusoria) or dyspnea is present, usually related to congenital distal arch lesions, such as aberrant right subclavian artery and Kommerell diverticulum or Felson and Palayew Type I or II right-sided aortic arch lesions.<sup>408</sup>

History of fevers may be related to inflammatory disease or mycotic aneurysms. Occasionally, with chronic dissection and leaking aneurysms, the reabsorption of blood may be associated with fever or jaundice.

#### 9.1.2.2. Physical Findings

Most physical findings are not specific for thoracic aortic disease. Other findings may be related to genetic syndromes and connective tissue disorders (see Section 5) or inflammatory diseases (see Section 7). Findings associated with coarctation of the aorta include brachial-femoral pulse delay and murmurs.

**Table 13. Studies of Medical Treatment of Thoracic Aortic Aneurysm**

Treatment	Studies	Results
Beta blockers	Genoni M, Paul M, Jenni R, et al <sup>410</sup>	Retrospective, case-record review of 78 patients with chronic Type B dissection who received medical treatment. 51 of 71 received beta-blocker treatment, 20 of 71 were treated with other antihypertensive drugs. 10 of 51 (20%) of the beta-blocker-treated patients and 9 of 20 (45%) from the other treatment group needed dissection-related surgery ( $P=0.002$ ). The incidence of increasing aortic diameter was 12% (6 of 51) in the beta-blocker group and 40% (8 of 20) in the other treatment group ( $P=0.002$ ).
	Shores J, Berger KR, Murphy EA, et al <sup>88</sup>	Open-label, randomized, control study of propranolol in 70 patients with Marfan syndrome. The treated group received a mean daily propranolol dose of $212 \pm 68$ mg/d. Propranolol therapy slowed aortic root dilation ( $0.023$ vs $0.084$ per year, $P<0.001$ ).
	Ladouceur M, Fermanian C, Lupoglazoff JM, et al <sup>411</sup>	Retrospective evaluation of aortic dilation in children with Marfan syndrome. Aortic dilatation was slowed by $0.2$ mm/y in children treated with beta blockers.
Angiotensin-converting enzyme inhibitors	Ahimastos AA, Aggarwal A, D'Orsa KM, et al <sup>412</sup>	Randomized, double-blind, placebo-controlled trial of 17 patients with Marfan syndrome taking beta-blocker therapy to perindopril or placebo. After 24 weeks of therapy, the perindopril-treated subjects compared with placebo-treated subjects had smaller growth in the ascending aortic diameter during systole ( $1.2$ vs $0.3$ mm/m <sup>2</sup> , $P=0.01$ ) and a significant reduction in ascending aortic diameter during diastole ( $0.4$ vs $-1.2$ mm/m <sup>2</sup> , $P<0.001$ ), respectively.
Angiotensin receptor blockers	Mochizuki S, Dahlof B, Shimizu M, et al <sup>413</sup>	3081 Japanese patients with hypertension, coronary heart disease, heart failure, or a combination were randomly assigned either to open-label valsartan (40 to 160 mg/d) or to other treatment without angiotensin receptor blockers. Patients randomized to valsartan had reduction in composite cardiovascular outcome (OR 0.61, 95% CI 0.47 to 0.79) and reduction in aortic dissection (OR 0.18, 95% CI 0.04 to 0.88). Open-label, randomized.
	Brooke BS, Habashi JP, Judge DP, et al <sup>89</sup>	The clinical response to angiotensin receptor blockers (losartan in 17 patients and irbesartan in 1 patient) were evaluated in pediatric patients with Marfan syndrome with severe aortic root enlargement. The mean ( $\pm$ SD) rate of change in aortic root diameter decreased significantly from $3.54 \pm 2.87$ mm/y during previous medical therapy to $0.46 \pm 0.62$ mm/y during angiotensin receptor blocker therapy ( $P<0.001$ ). The deviation of aortic root enlargement from normal, as expressed by the rate of change in z scores, was reduced by a mean difference of $1.47$ z scores/y (95% CI 0.70 to 2.24, $P<0.001$ ) after the initiation of angiotensin receptor blocker therapy. The sinotubular junction showed a reduced rate of change in diameter during angiotensin receptor blocker therapy ( $P<0.05$ ), whereas the distal ascending aorta was not affected by angiotensin receptor blocker therapy.
Statins	Diehm N, Decker G, Katzen B, et al <sup>414</sup>	A nonrandomized propensity-score-adjusted study of statin use effect on long-term mortality of patients after endovascular repair of AAA (731 patients) or TAA (59 patients) was done. Statin use was associated with decreased long-term mortality in patients with AAA (adjusted HR 0.613, 95% CI 0.379 to 0.993, $P=0.047$ ), but not for patients with TAA (adjusted HR 1.795, 95% CI 0.147 to 21.942; $P=0.647$ ).

AAA indicates abdominal aortic aneurysm; CI, confidence interval; SD, standard deviation; and TAA, thoracic aortic aneurysm.

### 9.1.3. Considerations for Imaging

Because most cases of chronic thoracic aortic disease are asymptomatic and difficult to detect on physical examination, the clinician must have a low threshold for screening for thoracic aortic disease. CT or MR is required to adequately visualize the affected aorta. There has been no cost-benefit analysis of screening in these populations (see Section 18.1).

## 9.2. General Medical Treatment and Risk Factor Management for Patients With Thoracic Aortic Disease

### 9.2.1. Recommendation for Medical Treatment of Patients With Thoracic Aortic Diseases

#### Class I

1. Stringent control of hypertension, lipid profile optimization, smoking cessation, and other atherosclerosis risk-reduction measures should be instituted for patients with small aneurysms not requiring surgery, as well as for patients who are not considered

#### to be surgical or stent graft candidates. (Level of Evidence: C)

The patient's general status should be optimized where possible. Respiratory illness, a common comorbid problem, may be improved by stopping smoking, clearing bronchitis, and exercising regularly with walking. Because other atherosclerotic disease is usually present in patients with thoracic aortic aneurysms or atheroma, risk-reduction measures as outlined in other guidelines are appropriate.<sup>409</sup> Additional medical management rationales are noted in Table 13.

Patients who are not candidates for operative intervention include those whose aneurysms or other aortic pathology do not meet the criteria for surgical intervention and those in whom the criteria are met but who are considered inoperable, most commonly because of coexisting disease. Patients with large aneurysms who are considered inoperable may benefit from stringent control of risk factors (see Section 3.2) to potentially slow the rate of growth and reduce the risk of rupture or dissection. Recommendations for periodic imaging are noted in Section 14.

## 9.2.1.1. Recommendations for Blood Pressure Control

**Class I**

1. **Antihypertensive therapy should be administered to hypertensive patients with thoracic aortic diseases to achieve a goal of less than 140/90 mm Hg (patients without diabetes) or less than 130/80 mm Hg (patients with diabetes or chronic renal disease) to reduce the risk of stroke, myocardial infarction, heart failure, and cardiovascular death.<sup>415–419</sup> (Level of Evidence: B)**
2. **Beta adrenergic–blocking drugs should be administered to all patients with Marfan syndrome and aortic aneurysm to reduce the rate of aortic dilatation unless contraindicated.<sup>88</sup> (Level of Evidence: B)**

**Class IIa**

1. **For patients with thoracic aortic aneurysm, it is reasonable to reduce blood pressure with beta blockers and angiotensin-converting enzyme inhibitors<sup>412</sup> or angiotensin receptor blockers<sup>89,413</sup> to the lowest point patients can tolerate without adverse effects.<sup>88,410,411</sup> (Level of Evidence: B)**
2. **An angiotensin receptor blocker (losartan) is reasonable for patients with Marfan syndrome, to reduce the rate of aortic dilatation unless contraindicated.<sup>89,90</sup> (Level of Evidence: B)**

Treatment of hypertension to reduce end points of MI, stroke, and death is well established with many randomized clinical trials.<sup>420</sup> In the Jikei Heart Study, Japanese patients who received valsartan along with other antihypertensive therapy had a significantly lower rate of cardiovascular morbidity and mortality compared with patients treated without valsartan. Reductions noted in particular included lower incidence of stroke, transient ischemic attack (TIA), angina pectoris, and heart failure. Moreover, pertinent to this guideline, there was a significant reduction in the incidence of AoD in the valsartan-treated patients, which contributed to the reduction in overall cardiovascular morbidity and mortality.<sup>413</sup>

Currently, beta adrenergic blockade serves as the foundation of the medical regimen because of demonstrated inhibition of aneurysm expansion in patients with Marfan syndrome. Shores and colleagues<sup>88</sup> randomized 70 patients with Marfan syndrome to propranolol or placebo in an open-label study demonstrating an attenuated rate of expansion over the 10-year follow-up. Dietz and colleagues<sup>91</sup> demonstrated that angiotensin receptor blocker therapy reduces aneurysm expansion in animal models of Marfan syndrome. This group has also recently demonstrated that angiotensin receptor blocker therapy slowed the rate of progression of progressive aortic root dilatation in a preliminary study of 18 pediatric patients with Marfan syndrome.<sup>89</sup> Both beta blockade and angiotensin II receptor blockade therapy are being further investigated in a randomized trial for patients with Marfan syndrome.<sup>90</sup>

Lifestyle modifications of diet, weight reduction for overweight or obese patients, moderation of alcohol consumption,

and aerobic exercise are standard approaches to treat hypertension,<sup>421</sup> but pharmacological therapy is usually required for patients with thoracic aortic diseases.

## 9.2.1.2. Recommendation for Dyslipidemia

**Class IIa**

1. **Treatment with a statin to achieve a target LDL cholesterol of less than 70 mg/dL is reasonable for patients with a coronary heart disease risk equivalent such as noncoronary atherosclerotic disease, atherosclerotic aortic aneurysm, and coexistent coronary heart disease at high risk for coronary ischemic events.<sup>422–425</sup> (Level of Evidence: A)**

The National Cholesterol Education Program ATP III recommends that patients with noncoronary atherosclerosis be treated like patients with established coronary heart disease.<sup>426</sup> Atherosclerosis in the aorta, like atherosclerosis in any noncoronary vascular bed, markedly increases the risk of MI and stroke. As a result of this high-risk status (greater than 20% event rate in 10 years), the goal for hypolipidemic therapy is an LDL level less than 100 mg/dL. Initial therapy in these patients should be a statin. After the National Cholesterol Education Program ATP III guidelines were released in 2001, the Heart Protection Study reported in 2002 that patients with atherosclerosis and a total cholesterol level greater than 135 mg/dL benefited from the addition of simvastatin 40 mg/d.<sup>427</sup> The RR reductions remained even when LDL started at less than 100 mg/dL. In concert with data from patients with acute coronary syndromes, the more recent ACC/AHA Guidelines for the Management of Patients With Peripheral Arterial Disease also gave a Class IIa recommendation suggesting the use of a statin to achieve a target LDL of less than 70 mg/dL for patients at very high risk of ischemic events is reasonable.<sup>4</sup>

There are experimental data demonstrating a delayed development of atherosclerosis and prevention of aneurysm development by statins.<sup>428–430</sup> However, there are no clinical outcomes data that justify their use acutely or suggest that statins prevent expansion after thoracic aortic aneurysms have developed.

## 9.2.1.3. Recommendation for Smoking Cessation

**Class I**

1. **Smoking cessation and avoidance of exposure to environmental tobacco smoke at work and home are recommended. Follow-up, referral to special programs, and/or pharmacotherapy (including nicotine replacement, bupropion, or varenicline) is useful, as is adopting a stepwise strategy aimed at smoking cessation (the 5 A's are Ask, Advise, Assess, Assist, and Arrange).<sup>431–432b</sup> (Level of Evidence: B)**

There are no randomized or prospective trials that have investigated the effect of smoking cessation on thoracic aortic disease. Patients with thoracic aortic aneurysm who smoke have double the rate of aneurysm expansion.<sup>433</sup> Aneurysm expansion and rupture after Type B dissection are not

affected by cigarette smoking.<sup>434</sup> Smoking cessation reduces the rate of MI and death in patients with noncoronary atherosclerosis.<sup>435</sup> Patients who smoke require close follow-up in conjunction with medical and other support to achieve complete smoking cessation.

### 9.2.2. Surgical and Endovascular Treatment by Location of Disease

#### 9.2.2.1. Ascending Aorta and Aortic Sinuses

##### 9.2.2.1.1. Recommendations for Asymptomatic Patients With Ascending Aortic Aneurysm

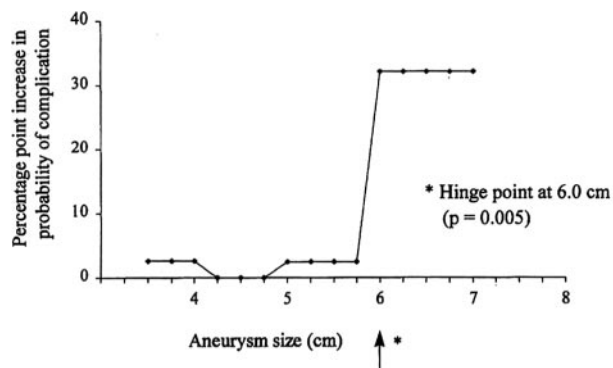
### Class I

1. Asymptomatic patients with degenerative thoracic aneurysm, chronic aortic dissection, intramural hematoma, penetrating atherosclerotic ulcer, mycotic aneurysm, or pseudoaneurysm, who are otherwise suitable candidates and for whom the ascending aorta or aortic sinus diameter is 5.5 cm or greater, should be evaluated for surgical repair.<sup>371</sup> (Level of Evidence: C)
2. Patients with Marfan syndrome or other genetically mediated disorders (vascular Ehlers-Danlos syndrome, Turner syndrome, bicuspid aortic valve, or familial thoracic aortic aneurysm and dissection) should undergo elective operation at smaller diameters (4.0 to 5.0 cm depending on the condition; see Section 5) to avoid acute dissection or rupture.<sup>81,114,143,371,436–439</sup> (Level of Evidence: C)
3. Patients with a growth rate of more than 0.5 cm/y in an aorta that is less than 5.5 cm in diameter should be considered for operation. (Level of Evidence: C)
4. Patients undergoing aortic valve repair or replacement and who have an ascending aorta or aortic root of greater than 4.5 cm should be considered for concomitant repair of the aortic root or replacement of the ascending aorta. (Level of Evidence: C)

### Class IIa

1. Elective aortic replacement is reasonable for patients with Marfan syndrome, other genetic diseases, or bicuspid aortic valves, when the ratio of maximal ascending or aortic root area ( $\pi r^2$ ) in cm<sup>2</sup> divided by the patient's height in meters exceeds 10.<sup>16,143</sup> (Level of Evidence: C)
2. It is reasonable for patients with Loeys-Dietz syndrome or a confirmed *TGFBR1* or *TGFBR2* mutation to undergo aortic repair when the aortic diameter reaches 4.2 cm or greater by transesophageal echocardiogram (internal diameter) or 4.4 to 4.6 cm or greater by computed tomographic imaging and/or magnetic resonance imaging (external diameter).<sup>78</sup> (Level of Evidence: C)

Aortic diameter is a major criterion for recommending elective operation in asymptomatic patients with aneurysm of the thoracic and thoracoabdominal aorta. This assumes that the risk of operation is low (less than 5%). Currently, aortic diameter perpendicular to the axis of flow as measured by CT is the dimension most often used to determine the size of the enlarged



Estimated effect of ascending aortic aneurysm size on risk of complication.

**Figure 30.** Effect of aortic aneurysms diameter on risk of complication. For thoracic aortic aneurysms of all etiologies. Adapted from Elefteriades et al.<sup>437</sup>

aorta. This recommendation is based on the observation that the risk of an adverse event (rupture, dissection, death) exceeds the risk of elective operation when the maximum diameter exceeds 5.5 to 6.0 cm<sup>374,436,437,440</sup> (Figure 30). Formulas that incorporate height and aortic cross-sectional area have been developed to establish thresholds for operation in shorter patients but are less widely used.<sup>16,143</sup>

The morphology and histopathology of thoracic aortic enlargements affect the natural history of aortic diseases, including the risk of rupture or dissection, and thus can influence the decision to intervene (Figures 31 and 32). Fusiform aneurysms are most common and behave in a relatively predictable manner. Aortic dimension can thus be used as an indication for operation. Saccular aneurysms occur less frequently and may be associated with a greater risk of rupture. Many of these are actually pseudoaneurysms, which can develop after previous trauma or aortic surgery, or with PAUs, and which result in focal disruption or weakening of the layers of the aorta.

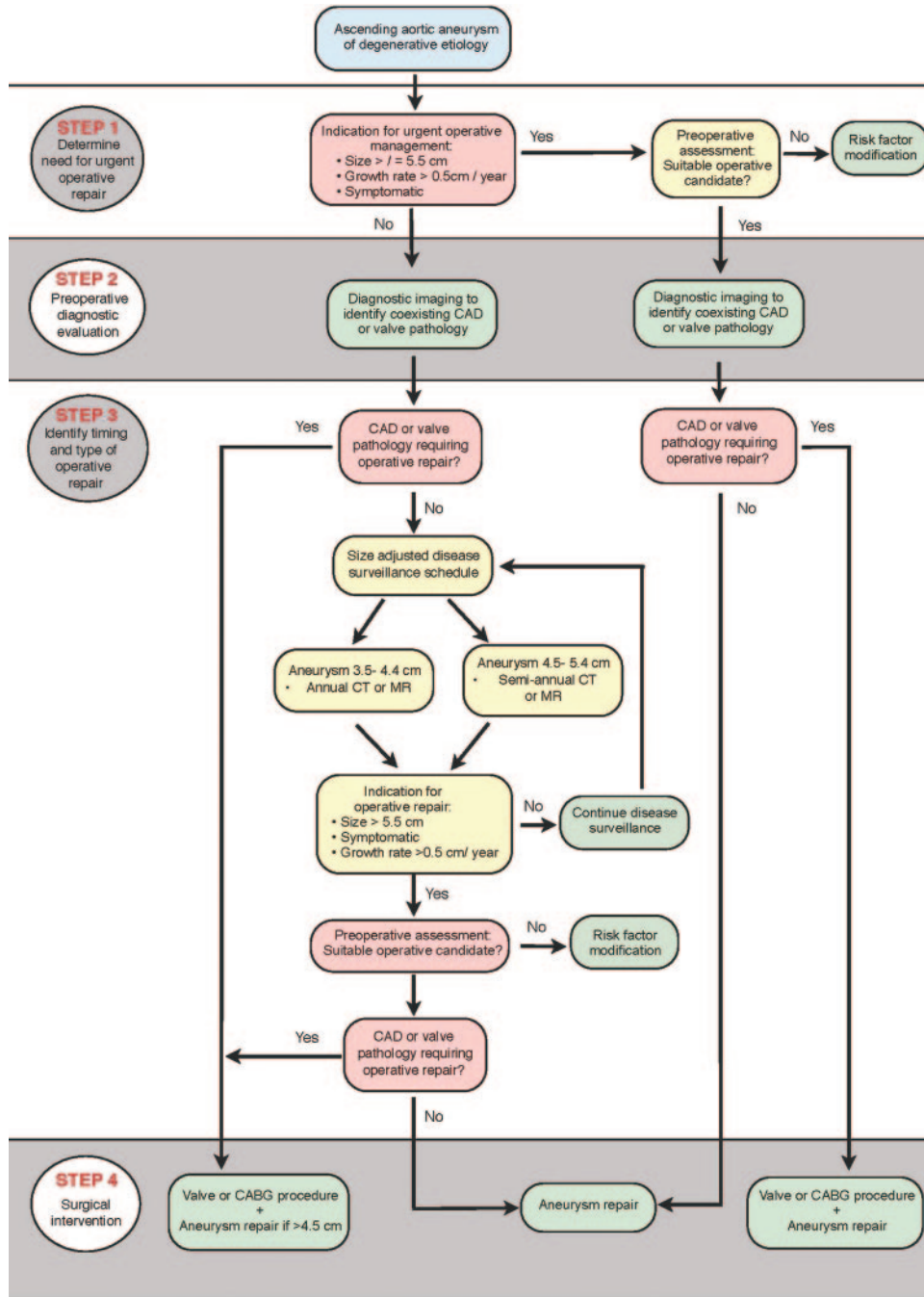
Patients with substantial dilatation of the aortic sinuses may develop asymptomatic aortic regurgitation as a result of loss of coaptation of the otherwise normal aortic valve cusps. Patients with associated bicuspid aortic valve disease may have asymptomatic stenosis or regurgitation of the valve. In these patients, the valvular disease may be an indication for operative intervention.<sup>5</sup>

#### 9.2.2.1.2. Recommendation for Symptomatic Patients With Thoracic Aortic Aneurysm

### Class I

1. Patients with symptoms suggestive of expansion of a thoracic aneurysm should be evaluated for prompt surgical intervention unless life expectancy from comorbid conditions is limited or quality of life is substantially impaired. (Level of Evidence: C)

Symptoms associated with thoracic aneurysms usually develop later in the course of enlargement of the aorta and most commonly result from impingement of the aneurysm on adjacent structures. Aneurysms of the ascending aorta and aortic sinuses may result in symptoms related to the



**Figure 31.** Ascending aortic aneurysm of degenerative etiology. CABG indicates coronary artery bypass graft surgery; CAD, coronary artery disease; CT, computed tomographic imaging; and MR, magnetic resonance imaging.

aortic regurgitation that develops as a result of the progressive aortic enlargement. Chest or back pain in the presence of an enlarged thoracic aorta is a predictor of aortic rupture.<sup>336,441</sup> Patients who develop an acute Type A AoD commonly present with severe chest or back pain.

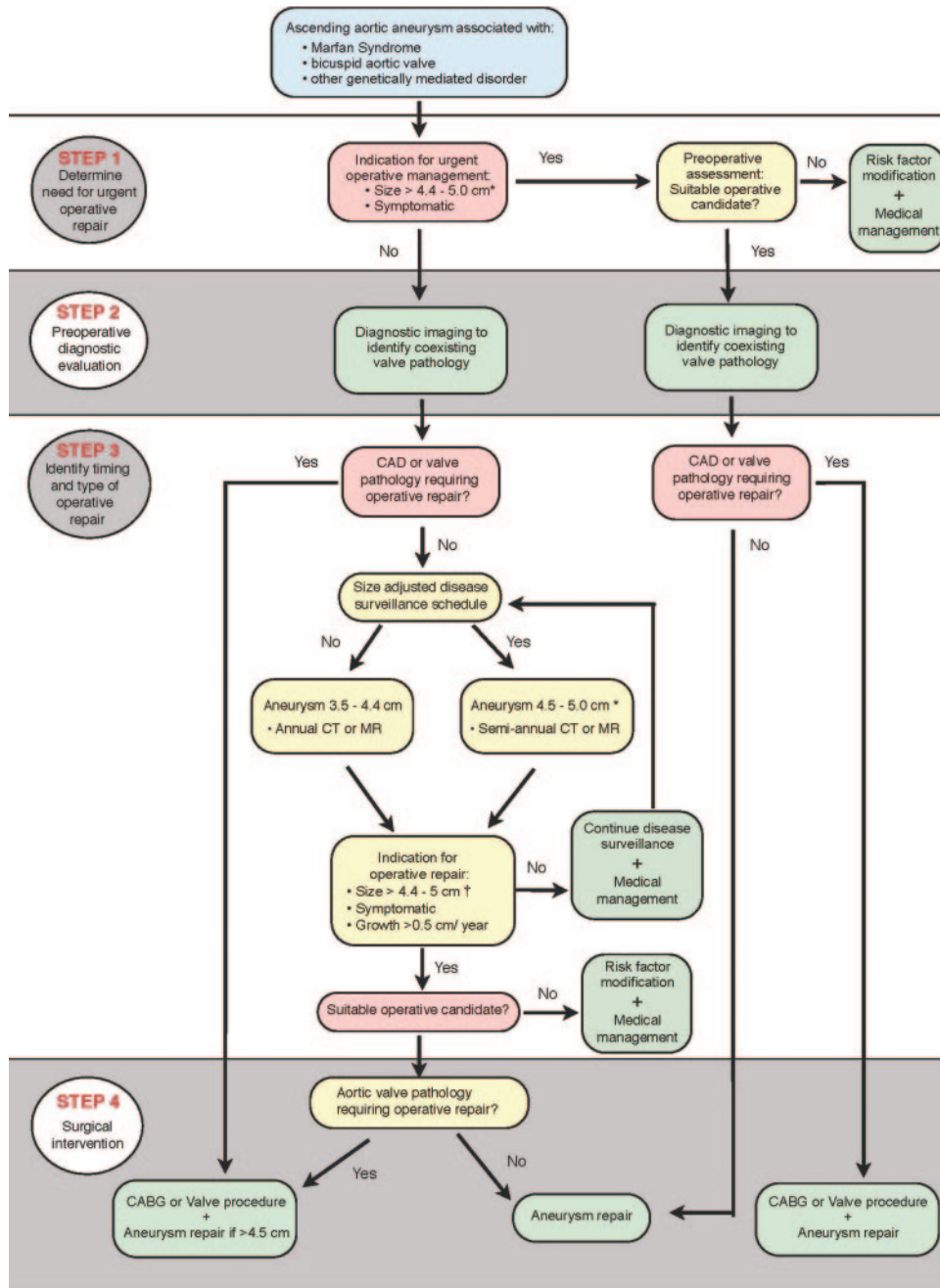
**9.2.2.1.3. Endovascular Grafting for Ascending Aortic Aneurysm.** At the time of this writing, endovascular stent grafts have not been approved by the US Food and Drug Administration for treatment of aneurysms or other conditions of the ascending aorta.

**9.2.2.1.4. Recommendations for Open Surgery for Ascending Aortic Aneurysm**

**Class I**

- 1. Separate valve and ascending aortic replacement are recommended in patients without significant aortic root dilatation, in elderly patients, or in young patients with minimal dilatation who have aortic valve disease. (Level of Evidence: C)**
- 2. Patients with Marfan, Loeys-Dietz, and Ehlers-Danlos syndromes and other patients with dilatation**





**Figure 32.** Ascending aortic aneurysms associated with genetic disorder. \*Depends on specific genetic condition. †See Recommendations for Asymptomatic Patients With Ascending Aortic Aneurysm (Section 9.2.2.1.1) and Recommendations for Bicuspid Aortic Valve and Associated Congenital Variants in Adults (Section 6.1). CABG indicates coronary artery bypass graft surgery; CAD, coronary artery disease; CT, computed tomographic imaging; and MR, magnetic resonance imaging.

**of the aortic root and sinuses of Valsalva should undergo excision of the sinuses in combination with a modified David reimplantation operation if technically feasible or, if not, root replacement with valved graft conduit.**<sup>134,164,442–444</sup> (Level of Evidence: B)

**Ascending Aortic Aneurysms:** The extent of aortic resection and the need for ancillary procedures are determined by preoperative testing and intraoperative findings. Ancillary procedures that may be performed concurrently include coronary artery bypass graft surgery, valve replacement or

repair, repair of cardiac septal defects, closure of vascular fistulas, and ablative therapy for arrhythmias.

For patients with isolated aneurysms confined to the ascending aorta, resection and graft replacement is the most commonly performed and recommended procedure. Alternatively, reduction aortoplasty with or without external reinforcement has only been performed in very limited circumstances.<sup>445,446</sup>

For patients with aortic valve stenosis who require valve replacement, the choice of valve substitute is determined by age of the patient, presence of comorbid disease, risk of

complications related to anticoagulation and reoperation, and life expectancy.<sup>139</sup>

For patients with aortic regurgitation associated with a bicuspid aortic valve, repair of the aortic valve with or without root remodeling or tailoring of the sinotubular junction is preferable if the valve is not severely fibrotic or calcified.<sup>99,140</sup> For patients with a dilated aortic root, particularly those with stenotic bicuspid valves, composite valve grafts containing either mechanical or biological valves are implanted.

Ascending aneurysms larger than 4.5 to 5.0 cm require repair or tube graft replacement when aortic valve repair or replacement is the primary indication for operation.<sup>5</sup> In elderly patients, ascending aortic aortoplasty when the aortic diameter does not exceed 5.0 cm may be an acceptable alternative.

**Aortic Valve and Root:** In patients with aortic valve regurgitation and root dilatation, aortic valve repair and root-sparing procedure may be the primary procedure. In patients with Marfan syndrome or with tricuspid aortic valve regurgitation, a modification of the David reimplantation operation may be considered.<sup>94,95,97–99,447</sup> Composite valve grafts with either biological or mechanical valves are an alternative option, particularly for valvular stenosis.<sup>99,140,441,448</sup>

#### 9.2.2.2. Recommendations for Aortic Arch Aneurysms

### Class IIa

1. For thoracic aortic aneurysms also involving the proximal aortic arch, partial arch replacement together with ascending aorta repair using right subclavian/axillary artery inflow and hypothermic circulatory arrest is reasonable.<sup>222,449,450</sup> (*Level of Evidence: B*)
2. Replacement of the entire aortic arch is reasonable for acute dissection when the arch is aneurysmal or there is extensive aortic arch destruction and leakage.<sup>222,450</sup> (*Level of Evidence: B*)
3. Replacement of the entire aortic arch is reasonable for aneurysms of the entire arch, for chronic dissection when the arch is enlarged, and for distal arch aneurysms that also involve the proximal descending thoracic aorta, usually with the elephant trunk procedure.<sup>451–453</sup> (*Level of Evidence: B*)
4. For patients with low operative risk in whom an isolated degenerative or atherosclerotic aneurysm of the aortic arch is present, operative treatment is reasonable for asymptomatic patients when the diameter of the arch exceeds 5.5 cm.<sup>374</sup> (*Level of Evidence: B*)
5. For patients with isolated aortic arch aneurysms less than 4.0 cm in diameter, it is reasonable to reimagine using computed tomographic imaging or magnetic resonance imaging, at 12-month intervals, to detect enlargement of the aneurysm. (*Level of Evidence: C*)
6. For patients with isolated aortic arch aneurysms 4.0 cm or greater in diameter, it is reasonable to reimagine using computed tomographic imaging or magnetic resonance imaging, at 6-month intervals,

### to detect enlargement of the aneurysm. (*Level of Evidence: C*)

Aneurysms of the aortic arch are commonly associated with aneurysmal disease or dissection of the ascending aorta or the adjacent descending thoracic aorta, and the indications for operative intervention in these patients are those for the adjacent aortic segment. This relates to the need for hypothermic cardiopulmonary bypass and an interval of hypothermic circulatory arrest, and to higher operative mortality and stroke rates than those observed following operation for isolated aneurysms of the ascending or descending thoracic aorta.<sup>451–459</sup> As with ascending aneurysms, a growth rate of more than 0.5 cm/y in the absence of symptoms could be considered an indication for operation.

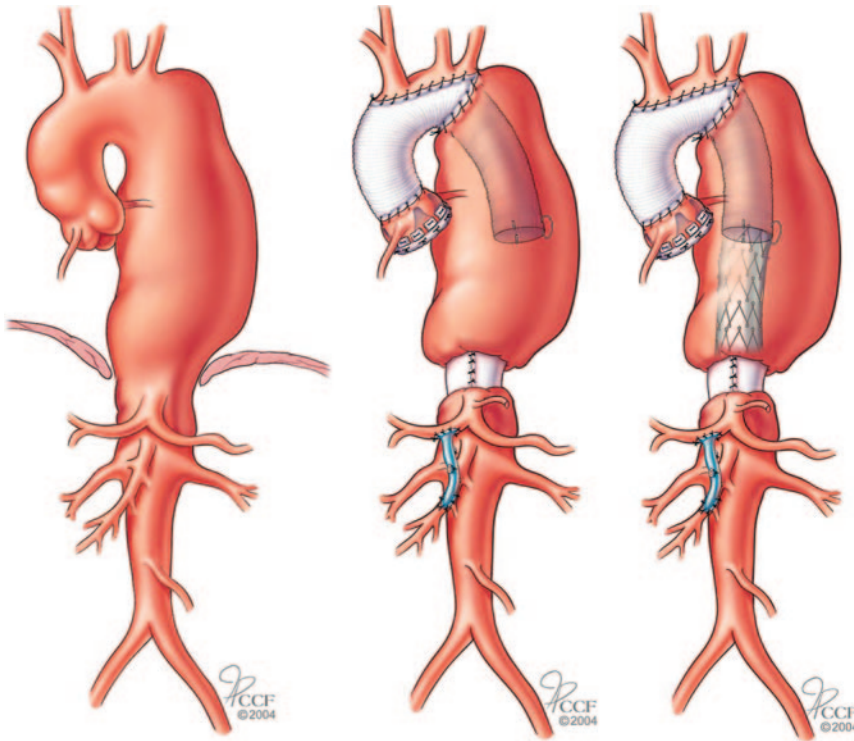
Symptoms associated with aortic arch aneurysms such as hoarseness resulting from stretching of the left recurrent laryngeal nerve, dysphagia, dyspnea, and chest or back pain are indications for operative intervention for patients with arch aneurysms unless life expectancy is quite limited. Suitability for operative intervention involves similar risk assessment to that for aneurysm or other disorders of the ascending aorta and aortic root.

The innominate, left carotid, and left subclavian arteries may require separate grafting. For short periods of circulatory arrest, the use of retrograde or antegrade brain perfusion has not conclusively been shown to add further brain protection; however, use of the subclavian or axillary artery bypass with a side graft reduces the risk of stroke.<sup>449</sup>

**9.2.2.2.1. Open Surgery.** At present, endovascular stent grafts have not been approved by the US Food and Drug Administration for treatment of aneurysms or other conditions of the aortic arch. For patients with large aneurysms who are not candidates for conventional open operation, experience is accumulating with operative procedures that involve translocation of the brachiocephalic arteries from the aortic arch using branch grafts from the proximal ascending aorta, and placement of an endovascular graft into the distal ascending aorta, the entire aortic arch, and a segment of the adjacent descending thoracic aorta.<sup>371,460,461</sup>

Cardiopulmonary bypass with some degree of hypothermia is required for operations that require replacement of the aortic arch. Brain protection can be achieved by profound hypothermia alone, direct antegrade perfusion of 1 or more of the brachiocephalic arteries, or retrograde perfusion using cold oxygenated blood that is infused into the superior vena cava during the arrest period<sup>211,449,462–467</sup> (see Section 14.5.1). The aortic arch is replaced with a synthetic graft. The brachiocephalic arteries are attached to the graft using a patch of the aorta which contains the origins of the 3 vessels or separately using a graft that contains 3 branches. The proximal and distal ends of the aortic graft are attached to normal segments of ascending and descending thoracic aorta.

An “elephant trunk” procedure has been used to reconstruct the arch and then provide a Dacron graft landing zone for endovascular stent graft treatment of descending thoracic aortic aneurysms (Figure 33).



**Figure 33.** Elephant trunk procedure. Left, Preoperative disease. Middle, Stage I with replacement of the ascending aorta and arch with a Dacron graft with the distal graft sutured circumferentially to the aorta distal to the left subclavian artery and the free end of the graft (“elephant trunk”) within the descending aneurysm. Right, Completion of the procedure using an endovascular stent graft attached proximally to the “elephant trunk” and the distal end secured to a Dacron graft cuff. Images reprinted with permission from the Cleveland Clinic Foundation.

### 9.2.2.3. Descending Thoracic Aorta and Thoracoabdominal Aorta

#### 9.2.2.3.1. Recommendations for Descending Thoracic Aorta and Thoracoabdominal Aortic Aneurysms

##### Class I

1. For patients with chronic dissection, particularly if associated with a connective tissue disorder, but without significant comorbid disease, and a descending thoracic aortic diameter exceeding 5.5 cm, open repair is recommended.<sup>371,382,468</sup> (Level of Evidence: B)
2. For patients with degenerative or traumatic aneurysms of the descending thoracic aorta exceeding 5.5 cm, saccular aneurysms, or postoperative pseudoaneurysms, endovascular stent grafting should be strongly considered when feasible.<sup>371,469</sup> (Level of Evidence: B)
3. For patients with thoracoabdominal aneurysms, in whom endovascular stent graft options are limited and surgical morbidity is elevated, elective surgery is recommended if the aortic diameter exceeds 6.0 cm, or less if a connective tissue disorder such as Marfan or Loays-Dietz syndrome is present.<sup>371</sup> (Level of Evidence: C)
4. For patients with thoracoabdominal aneurysms and with end-organ ischemia or significant stenosis from atherosclerotic visceral artery disease, an additional revascularization procedure is recommended.<sup>470</sup> (Level of Evidence: B)

At the time of publication of this document, 3 endovascular stent grafts have been approved by the US Food and Drug Administration only for aneurysms involving the descending

thoracic aorta. Although the feasibility and safety of endovascular stent grafting of the descending aorta have been demonstrated for other pathologic conditions including acute and chronic Type B AoD, IMH, PAU, acute traumatic aortic transection, and pseudoaneurysms, these conditions are currently considered “off label.”

There are no published randomized trials that compare the outcomes of endovascular stent grafting with conventional open operation or nonoperative management. Thus, recommendations for use are based principally on observational studies and nonrandomized comparisons of cohorts of patients.

**9.2.2.3.2. Endovascular Versus Open Surgical Approach.** The potential advantages of endovascular grafting over open operation include the absence of a thoracotomy incision and the need for partial or total extracorporeal circulatory support and clamping of the aorta, as well as lower hospital morbidity rates and shorter length of hospital stay.

Endovascular grafting may be of particular value in patients with significant comorbid conditions (older age, substantial cardiac, pulmonary and renal dysfunction) who would be considered poor or noncandidates for open surgery. Patients who are not considered candidates for open surgery but who have undergone endovascular grafting have substantially poorer long-term outcomes than patients who are reasonable candidates for open operation and are treated with endografts.<sup>471</sup> Furthermore, intervention (endovascular stent graft or open surgical graft replacement) for a descending aneurysm has real risks of mortality and morbidity, including the risk of spinal cord ischemic injury. All physicians should work collaboratively among specialties during the initial decision-making steps to determine via consensus whether a particular

patient's pathology, risk factors, and projected natural history if treated medically justify an intervention on the descending thoracic aorta, either a stent graft or an open procedure.

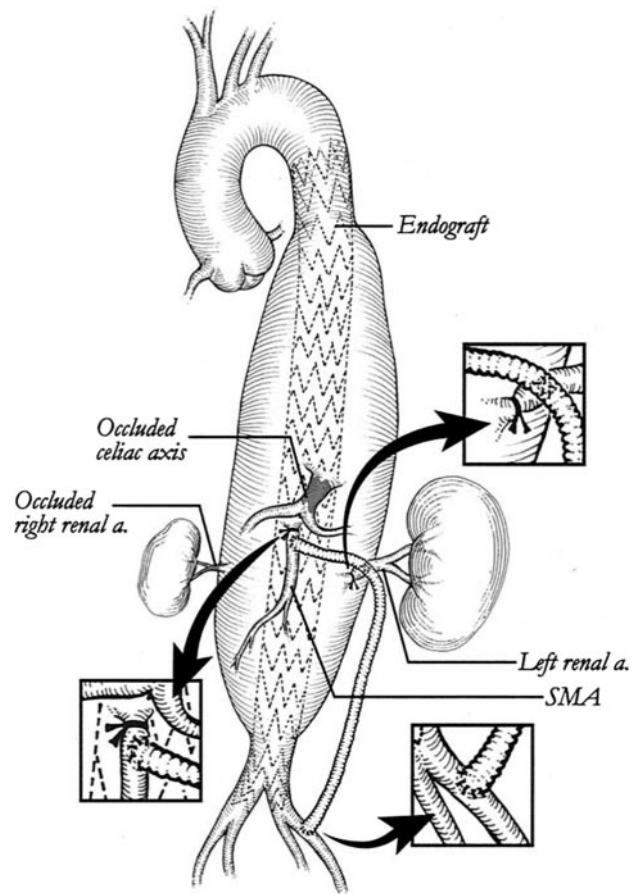
There are no data that conclusively demonstrate that the prevalence of spinal cord ischemic injury (lower extremity paralysis or paresis) is less for endovascular approaches than for open surgical repair. Similarly, there are no firm data to indicate that overall costs of medical care are lower with endovascular procedures. Although the costs of the initial hospitalization may be lower because of reduced operative time and a shorter length of stay, these benefits may be negated by the cost of the devices, the need for subsequent interventions, and the cost and dissatisfaction of repeated imaging studies, which are necessary in the postoperative period.<sup>472,473</sup>

Some patients are not suitable candidates for endovascular grafting procedures. Absence of suitable "landing zones" above and below the aneurysm (usually 2 to 3 cm of normal diameter aorta without circumferential thrombus) is a contraindication. A width of the aorta at the landing zones that exceeds the recommended width for the largest available endovascular grafts (generally 10% to 15% larger than the width of the aorta) is also a contraindication.

Lack of vascular access sites to insert the relatively large-bore sheaths that are necessary for deployment of the grafts is also a contraindication. Severe atherosclerosis and intraluminal thrombus of the aorta may increase the risk of embolic stroke during manipulation of guidewires and catheters and represents a relative contraindication.<sup>474</sup>

**9.2.2.3.3. End-Organ Preservation During Thoracic Endograft Implantation.** Because aneurysmal disease can involve any portion of the aorta, organ preservation during repair of either aneurysmal disease or dissection is an important part of the implant procedure. Aneurysms involving the aortic arch pose a significant risk to cerebral and upper extremity blood flow with endovascular repair. The need to cover either the left common carotid or the innominate artery to treat arch aneurysmal disease is infrequent. Intentional coverage of the left subclavian artery is more common, occurring in approximately 50% of thoracic endograft implants. Most patients tolerate coverage of the left subclavian artery without upper extremity ischemia,<sup>475–478</sup> but recently several groups have suggested that these patients may be at higher risk of perioperative stroke and spinal cord ischemic injury.<sup>479–481</sup> In the Talent VALOR trial, the need for intentional preimplant left subclavian artery bypass was only 5.2%.<sup>482</sup> To minimize the risk associated with intentional coverage of the left subclavian artery, it is recommended that the patency of the contralateral right subclavian and vertebral arteries be determined preoperatively by CT, MR, or invasive angiography. Additionally, verification that the vertebral arteries communicate at the basilar artery by either transcranial Doppler or angiography is also recommended. If these steps are taken to ensure that the contralateral posterior circulation is intact, the need to perform a left subclavian artery bypass postoperatively to prevent symptomatic arm claudication or vertebral basilar insufficiency is infrequent.

Spinal cord ischemia leading to paralysis is one of the serious potential complications of the thoracic endograft



**Figure 34.** Schema of TAA treated with initial left iliac artery-to-left renal artery-to-superior mesenteric artery bypass graft and subsequent placement of a thoracoabdominal endograft. Proximal superior mesenteric artery and left renal arteries were ligated. SMA indicates superior mesenteric artery; and TAA, thoracoabdominal aneurysm. Adapted from Flye et al.<sup>489</sup>

procedure. Intercostal arteries are intentionally covered by the endograft. There is evidence that the risk of spinal cord ischemia may be greater when treatment involves coverage of most of the descending thoracic aorta (eg, from left subclavian to celiac artery).<sup>483</sup> Additionally, patients who have had previous repair of abdominal aneurysm (either open or endovascular) are at increased risk for spinal cord ischemia and paraplegia.<sup>484</sup> In 1 study, the risk of spinal cord ischemia was 10% to 12% in patients with previous abdominal aneurysm repairs and 2% in patients who did not have previous abdominal aneurysm repairs.<sup>485</sup> In circumstances where it is necessary to cover most of the descending thoracic aorta or if the patient has had a previous abdominal aneurysm repair, cerebrospinal fluid (CSF) pressure monitoring and drainage are an important strategy to minimize the risk of paraplegia.<sup>486</sup>

Treatment of TAAs with an endograft may require intentional coverage of the celiac and/or superior mesenteric arteries to achieve a seal at the distal attachment site. In these instances, a superior mesenteric-to-celiac artery bypass graft or an aorta-to-superior mesenteric and/or celiac artery bypass graft has been used as a first-stage debranching procedure before proceeding with the endograft implant (Figure 34). However, risk of the debranching operation may be no lower

than conventional open repair, and therefore these operative approaches are performed selectively.<sup>487</sup> Fenestrated grafts are in development and are undergoing clinical trials. Roselli et al<sup>488</sup> published initial results in the first 73 patients undergoing in situ endovascular repair of extensive TAAs using a branch endograft with promising results in a high-risk population. With careful attention to preservation of blood flow to the mesenteric vessels, the incidence of mesenteric ischemia with endograft implants is approximately 3%.<sup>482</sup> Most instances of mesenteric ischemia are the result of emboli rather than malperfusion owing to coverage or occlusion of a mesenteric vessel.

AoDs pose a complex situation for intestinal, renal, or lower extremity perfusion, as the branches of the aorta in the abdominal cavity may be perfused from either the true or false lumen. Often, both the true and false lumens are patent and some of the visceral, renal, or lower extremity vessels are fed by one channel and the remainder by the other. Thus, the operator must consider how blood flow reaches vital organs in the abdominal cavity before considering treatment of an AoD with an endograft. In most cases, where descending thoracic dissections are treated with an endograft, the important treatment principle is to cover the proximal entry tear obliterating the false lumen. However, if the false lumen supplies blood flow to the visceral vessels, blood flow to these organs may be compromised after endograft implantation. Stenting of the vessels at risk from the true lumen or establishing flow communication between true and false lumen more distally with a fenestration procedure may prevent such compromise. In cases of acute Type B AoD treated with endografts, coverage of the proximal entry site into the false lumen may result in healing of the tear downstream with restoration of blood flow from the true lumen without the need for adjunctive fenestration procedures.<sup>490</sup>

**9.2.2.3.4. Periprocedural Complications of Endograft Procedures.** The acute complications of thoracic endograft procedures are related to problems with access and with device implantation. Vascular access is a substantial issue with thoracic endograft procedures. The sheath required to deploy endovascular grafts is size 20 French or greater and can be up to size 25 French. Many patients have femoral arteries that are too small to accommodate such large sheaths. Use of the iliac artery or the aorta for access is required in approximately 15% of the patients. Infection at the access site is not an infrequent complication. Bleeding complications are less frequent. Average blood loss in the Talent VALOR trial was 371 mL, and the need for transfusion in the STARZ TX2 clinical trial (study results on the Zenith TX2 Endovascular Graft for the Thoracic Aortic Aneurysms) was 3%.<sup>469,482</sup> Thromboemboli to mesenteric, renal, or lower extremity vessels can also occur.<sup>491</sup>

Major adverse events related to the device occur in 10% to 12% of patients in the initial 30-day perioperative period. Stroke was observed in 2.5% of the patients in the STARZ TX2 clinical trial<sup>469</sup> and 3.6% in the Talent VALOR trial.<sup>482</sup> It has been reported to be as high as 8% in other studies.<sup>474,492</sup> Most strokes occur as a result of atheroemboli from the

**Table 14. Classification of Endoleaks**

Type	Cause of Perigraft Flow	Sequelae and Treatment Strategy
I	Inadequate seal at proximal and/or distal graft attachment site	Systemic arterial pressure transmitted to the aneurysm sac, leading to expansion and rupture. Should be repaired when diagnosed.
II	Retrograde aortic branch arterial blood flow into aneurysm sac	May spontaneously thrombose. If aneurysm is stable or shrinking, observe. If aneurysm is expanding, embolic occlusion of branch artery indicated but often difficult.
III	Structural failure of endograft (eg, stent graft fractures, holes in fabric, junctional separations)	Systemic arterial pressure transmitted to the aneurysm sac, leading to expansion and rupture. Should be repaired when diagnosed.
IV	Stent graft fabric porosity	Noted at time of implantation and usually resolved with reversal of anticoagulation.
V	Expansion of aneurysm without demonstrable endoleak, also called "endotension"	Reline the endograft with a second endograft.

Adapted from Veith et al.<sup>494</sup>

transverse aortic arch with manipulation of the guidewires and device in the arch vessels.<sup>474</sup> Paraplegia varied from 1.3% in the STARZ TX2 clinical trial to 1.5% in the Talent VALOR trial to 3% in the TAG trial.<sup>469,482,493</sup>

Cardiac complications, principally MI, occur rarely (2% to 4%).<sup>469,482</sup> Cardiac tamponade or rupture is rare and may be caused by either the stiff guidewires that are required to deliver the devices or excessive afterload created by the balloons that are inflated to produce a seal of the graft to the aortic wall. Ventricular tachycardia or ventricular fibrillation has been reported.<sup>469</sup> Pulmonary complications include postoperative pneumonias, which occur in less than 5% of patients. Acute renal failure requiring dialysis is also uncommon, reported to occur in 1.3% of patients in the Talent VALOR trial.<sup>482</sup> Device implant infection is exceedingly rare and has been observed mainly in situations where the device was implanted in an infected medium emergently (ie, mycotic aneurysms or aortoenteric fistulae).<sup>482</sup>

Endoleak is defined as the persistence of blood flow outside the lumen of the endoluminal graft but within the aneurysm sac, based on imaging. Endoleaks are classified based on the source of blood flow (Table 14).

Perforation or dissection of the aorta at the implantation site is infrequent but usually reported with stent systems that have uncovered or bare proximal attachment stents.<sup>495–499</sup> Involution or infolding of the endografts may occur and has been most frequently reported with grafts applied to a relatively small aorta where oversizing can be substantial, especially in trauma cases.<sup>366,500,501</sup> Infoldings can also occur when there is inadequate conformity of the device to the aortic wall in a region of marked curvature or "beaking" (see Figure 27). This leads to collapse of the endograft, gross endoleak, and the potential for acute occlusion of flow to the descending thoracic aorta. It can be prevented (or managed

after it occurs) with implantation of a reinforcing stainless steel stent at the proximal leading edge of the implant.<sup>500</sup>

Late complications of thoracic aortic endografting include endoleaks, continued aneurysm growth, metal fatigue and stent fracture and kinking, detachment, migration, perforation, and infection of the implanted device. Endoleaks occur in 10% to 20% of patients.<sup>482</sup> The frequency is greatest in the first month following implantation and declines over the ensuing 5 years.<sup>502</sup> The most frequent type of endoleak is Type IA, or proximal attachment site failure (see Section 8.6).<sup>469,482,503–505</sup> Migration occurs infrequently—at 1-year follow-up in 0.4% of cases in the TAG clinical trial and 3.9% of cases in the Talent VALOR trial.<sup>469,482,506</sup>

Late perforations of the aorta by the endograft can occur and are common with the use of oversized grafts and/or grafts with bare or uncovered stents.<sup>507,508</sup> Most late device complications such as endoleak and migration are treatable with implantation of graft extensions. The overall need for repeat interventions to maintain endograft integrity is 6% to 7%, most commonly in the form of implantation of an extension cuff. Conversions to open operation are rarely needed (1% to 2%).<sup>476,480,505,509,510</sup> Late complications (9 to 24 months) include stent fractures, which are often asymptomatic.<sup>511</sup> There are case reports of fractures leading to endograft dysfunction, endoleak, migration, and/or embolization.<sup>512</sup> Endograft infection, usually as a result of an ongoing systemic infection, or as a result of infected structures adjacent to the graft,<sup>513,514</sup> is uncommon, but when it occurs, it is very difficult to eradicate without explantation of the device and, without explantation, can lead to aortic rupture.<sup>515</sup>

The experience with the use of endografts for the treatment of acute descending AoD is limited. A meta-analysis of 609 published cases suggests that when endografts are used, mortality is slightly higher (5.3%) and late conversions to open procedures are more frequent (2.5%) than data reported for treatment of aneurysms. The risk of major complications including stroke, paraplegia, and aneurysm rupture appears to be similar in both conditions.<sup>516</sup> A complication unique to endograft treatment of acute Type B dissections is conversion of the dissection to a retrograde Type A dissection, creating a surgical emergency.<sup>480,517</sup> Until and unless this life-threatening complication is understood and eliminated, endograft treatment of acute Type B dissections should be undertaken at institutions with a team qualified to perform open aortic surgery.

In the absence of Level A or Level B evidence regarding the relative efficacy of open and endovascular procedures for treatment of descending aortic aneurysms, no firm recommendations can be made regarding the optimal method of treatment. Among comparable patients treated with either open or endovascular procedures, the midterm results can be anticipated to be equivalent. The early mortality advantage of endovascular procedures may be lost during follow-up such as that seen with endovascular treatment of AAAs.<sup>518,519</sup> The long-term durability of endovascular stent grafts is uncertain; currently, available grafts may have a durability of no more

**Table 15. Summary of Society of Thoracic Surgeons Recommendations for Thoracic Stent Graft Insertion**

Entity/Subgroup	Classification	Level of Evidence
Penetrating ulcer/intramural hematoma		
Asymptomatic	III	C
Symptomatic	IIa	C
Acute traumatic	I	B
Chronic traumatic	IIa	C
Acute Type B dissection		
Ischemia	I	A
No ischemia	IIb	C
Subacute dissection	IIb	B
Chronic dissection	IIb	B
Degenerative descending		
>5.5 cm, comorbidity	IIa	B
>5.5 cm, no comorbidity	IIb	C
<5.5 cm	III	C
Arch		
Reasonable open risk	III	A
Severe comorbidity	IIb	C
Thoracoabdominal/severe comorbidity	IIb	C

Reprinted from Svensson et al.<sup>371</sup>

than 10 years. Younger patient age may be a relative contraindication to endografting.

There are no data to indicate that endovascular stent grafting should be performed in patients with asymptomatic descending aortic aneurysms that are less than 5.5 cm in diameter, because the risk of operation (approximately 5%) exceeds the risk of rupture or dissection<sup>371</sup> (Table 15). Undoubtedly, as new iterations of devices are introduced, these guidelines will change.

**9.2.2.3.5. Open Surgical.** Diseases of the aorta that require extensive thoracoabdominal surgical or interventional approaches fall into 3 large groups: 1) degenerative aneurysms, 2) AoD resulting in subsequent aneurysms or visceral ischemia, and 3) occlusive disease of the visceral arteries. Selection of patients for repair is based on symptoms, risk of death from rupture, and end-organ ischemia, provided associated comorbidity does not prevent surgical repair. In patients with lower chest or upper abdominal pain, CT or MR is performed to determine if the patient has a contained rupture, leak, or an aneurysm impinging on surrounding structures that may be causing pain. The perioperative risk of death is approximately 80% with emergency surgery; a few patients will recover without a major complication limiting quality of life, and few will be long-term survivors because of comorbid disease. In patients with pain from compression of surrounding structures, if comorbid disease is not a factor, results are considerably better with a 10% to 20% risk of death. In patients undergoing elective surgery, the risk of death is 3% to 10%, depending on the extent of repair.

The extent of repair for TAA is classified by the Crawford types: Type I is a repair that extends from the proximal

descending aorta above T6 to the renal arteries; Type II, the highest risk group, extends from the proximal descending aorta above T6 to below the renal arteries; Type III extends from the distal descending aorta below T6 to below the diaphragm for variable extents; and Type IV extends from the diaphragm and involves most of the abdominal aorta. This classification correlates with the risk of paralysis, renal failure, and death.

Open surgical repair of TAA improved over the past 15 years, particularly on preventing postoperative paralysis. Historically, one of the most serious complications was paralysis, either paraparesis or paraplegia, caused by spinal cord injury whose risk is for Type I TAA repair, 15%; for Type II, 30%; Type III, 7%; and for Type IV, 4%.<sup>381</sup> Current risk of paralysis is 3% to 5%, depending somewhat on the extent of repair.<sup>381,382,520–526</sup>

The risk of renal failure may be reduced by preoperative day admission, fluid hydration starting the day before surgery, and the addition of bicarbonate to the hydration regimen and hypothermia protection during the operative procedure.

**9.2.2.3.6. End-Organ Preservation During Open Thoracoabdominal Repairs.** For thoracoabdominal aortic repairs done in combination with proximal repairs of the aortic arch, the key vital end organs to protect are the heart and brain. Flooding the field with CO<sub>2</sub> appears to be beneficial.<sup>527,528</sup> When the aortic arch requires repair, hypothermic circulatory arrest is usually required. Protection of the brain involves ensuring that calcium plaques or atheromata are not disturbed to prevent brain embolization. The temperature and where it is best measured, at which circulatory arrest is commenced, are debated but most large series have recommended circulatory arrest at a temperature below 20°C.<sup>211</sup>

Perfusion of the celiac artery or superior mesenteric artery does not appear to be needed to protect the abdominal organs in most patients where moderate hypothermia (30° to 32°C) is used. Protection of the left lung during left thoracotomy repairs is important to avoid lacerations and bleeding into the parenchyma. Deflation of the left lung may be of benefit. However, disruption of the visceral pleura with attendant complications of bleeding and air leak may be unavoidable, particularly if adhesions are present due to prior surgery or inflammatory changes.

**9.2.2.3.7. Aortic Dissection With Malperfusion.** Renal, mesenteric, lower extremity, or cord malperfusion accompanies up to one third of acute AoD and roughly doubles mortality.<sup>248,529,530</sup> In the case of Type A AoD with malperfusion, there is controversy over whether patient outcomes are improved by first repairing the aorta and then treating persistent malperfusion<sup>531</sup> or by first correcting the malperfusion and then repairing the aorta.<sup>247,532</sup> The general consensus is to first repair the aorta, because this will correct malperfusion in most patients. In the case of Type B AoD, there is a general consensus that medical management should be supplemented by open or endovascular intervention when there is evidence for renal, mesenteric, lower extremity, or cord malperfusion.<sup>248,490,533</sup>

## 10. Special Considerations in Pregnant Patients With Aortic Disease

### 10.1. Effects of Pregnancy on the Aorta

Physiologic effects of pregnancy may have a profound effect not only on aortic stress but potentially on arterial ultrastructure as well. The pregnant state is characterized by increases in maternal blood volume, heart rate, blood pressure, stroke volume, and cardiac output.<sup>534,535</sup> Taken together, the combined effects lead to greater arterial wall tension as well as intimal shear forces. These changes begin in the first and second trimesters but are most notable in the third trimester and peripartum period. Whether arterial wall weakening itself occurs during pregnancy remains controversial. Arterial dissection and/or rupture may occur with the highest incidence in the third trimester (approximately 50%) and peripartum period (33%). In one of the few prospective studies of pregnant patients with Marfan syndrome, 4.4% of carefully monitored patients developed aortic dissection.<sup>534</sup> In unmonitored patients, the risk is likely higher.

### 10.2. Epidemiology of Chronic and Acute Aortic Conditions in Pregnancy

Marfan syndrome, Ehlers-Danlos syndrome, and other non-Marfan aortic disease may manifest during pregnancy. Although clearly rare, it has been estimated that half of AoD and/or ruptures in women younger than 40 years of age have been associated with pregnancy.<sup>536</sup> Most dissections occur in the ascending aorta, although dissection or rupture of virtually any artery in the body has been described. In addition, pregnancy-related expansion of the sinotubular junction may lead to aortic valve insufficiency.

### 10.3. Counseling and Management of Chronic Aortic Diseases in Pregnancy

#### 10.3.1. Recommendations for Counseling and Management of Chronic Aortic Diseases in Pregnancy

##### Class I

1. **Women with Marfan syndrome and aortic dilatation, as well as patients without Marfan syndrome who have known aortic disease, should be counseled about the risk of aortic dissection as well as the heritable nature of the disease prior to pregnancy.**<sup>74,91</sup> (*Level of Evidence: C*)
2. **For pregnant women with known thoracic aortic dilatation or a familial or genetic predisposition for aortic dissection, strict blood pressure control, specifically to prevent Stage II hypertension, is recommended.** (*Level of Evidence: C*)
3. **For all pregnant women with known aortic root or ascending aortic dilatation, monthly or bimonthly echocardiographic measurements of the ascending aortic dimensions are recommended to detect aortic expansion until birth.** (*Level of Evidence: C*)
4. **For imaging of pregnant women with aortic arch, descending, or abdominal aortic dilatation, magnetic resonance imaging (without gadolinium) is recommended over computed tomographic imaging to avoid exposing both the mother and fetus to ionizing radiation. Transesophageal echocardiogram is an**

option for imaging of the thoracic aorta. (Level of Evidence: C)

5. Pregnant women with aortic aneurysms should be delivered where cardiothoracic surgery is available. (Level of Evidence: C)

#### Class IIa

1. Fetal delivery via cesarean section is reasonable for patients with significant aortic enlargement, dissection, or severe aortic valve regurgitation.<sup>91</sup> (Level of Evidence: C)

#### Class IIb

1. If progressive aortic dilatation and/or advancing aortic valve regurgitation are documented, prophylactic surgery may be considered.<sup>537</sup> (Level of Evidence: C)

In this regard, risk of major aortic complications during pregnancy appears to be low when the aortic root diameter is less than 4.0 cm.<sup>538</sup> Such individuals may have one or more successful pregnancies. For patients with an aortic diameter greater than 4.0 cm and Marfan syndrome, half will have come to prophylactic surgery during pregnancy, will have a rupture, or will have life-threatening growth. Optimal preventive therapy in the pregnant woman with known aortic disease includes use of beta blockers to control heart rate and reduce shear stresses, particularly in the third trimester and peripartum period. Both angiotensin-converting enzyme inhibitors and angiotensin receptor blockers are contraindicated during pregnancy.

#### 10.4. Evaluation and Management of Acute Aortic Syndromes During Pregnancy

Pregnant women with Marfan syndrome, bicuspid aortic valve and ascending aneurysms, Ehlers-Danlos syndrome, and non-Marfan familial thoracic aortic aneurysm and dissection may present with acute aortic syndromes at any point during the pregnancy but are particularly prone to do so in the last trimester, during delivery, or in the early postpartum period. Such women may have no knowledge of their underlying aortic condition until presentation with their acute aortic problem.

Obviously, acute AoD poses a huge risk for both the mother and the unborn child. Optimal treatment parallels that of nonpregnant women but with the added complication of when and how to deliver the child. Optimal care includes involvement with a high-risk maternal-fetal team along with an aortic specialty team capable of medical, percutaneous, and surgical aortic treatment. For Type A AoD occurring during the first or second trimester, urgent surgical repair with aggressive fetal monitoring is preferred. Fetal loss during hypothermia and cardiopulmonary bypass is common. When dissection complicates the third trimester, urgent cesarean section followed by aortic repair appears to offer the best chance for survival for the unborn child and the mother. For acute arch or Type B AoD, medical therapy is preferred unless percutaneous stent grafting or open surgery is man-

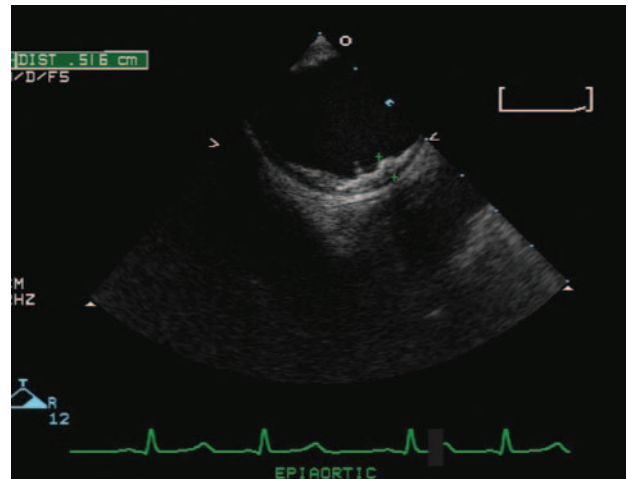


Figure 35. Ultrasound image of aortic atheroma.

dated by malperfusion, aortic rupture, or subacute aortic leaking.<sup>539</sup>

### 11. Aortic Arch and Thoracic Aortic Atheroma and Atheroembolic Disease

#### 11.1. Recommendations for Aortic Arch and Thoracic Aortic Atheroma and Atheroembolic Disease

##### Class IIa

1. Treatment with a statin is a reasonable option for patients with aortic arch atheroma to reduce the risk of stroke.<sup>540</sup> (Level of Evidence: C)

##### Class IIb

1. Oral anticoagulation therapy with warfarin (INR 2.0 to 3.0) or antiplatelet therapy may be considered in stroke patients with aortic arch atheroma 4.0 mm or greater to prevent recurrent stroke. (Level of Evidence: C)

#### 11.2. Clinical Description

Aortic arch atheroma is a risk factor for ischemic stroke based on autopsy,<sup>541,542</sup> TEE,<sup>543–548</sup> and intraoperative ultrasonographic studies<sup>549</sup> (Figure 35). In particular, plaques 4 mm or greater in thickness proximal to the origin of the left subclavian artery are associated with stroke and constitute one third of patients with otherwise unexplained stroke.<sup>542</sup> These patients, even on antiplatelet therapy, carry a risk of recurrent ischemic stroke as high as 11% at 1 year, and the risk of a new vascular event (ischemic stroke, MI, peripheral event, and vascular death) is 20%, 36%, and 50% at 1, 2, and 3 years, respectively.<sup>550</sup> The RR of new ischemic stroke was 3.8 (95% CI 1.8 to 7.8,  $P \leq 0.002$ ), and that of new vascular events was 3.5 (95% CI 2.1 to 5.9,  $P \leq 0.001$ ), independent of carotid stenosis, atrial fibrillation, peripheral artery disease, or other risk factors.<sup>550</sup> Other studies showed that aortic arch plaques were independent predictors of recurrent strokes, MI and vascular death.<sup>551–553</sup> Patients with noncalcified plaques were at higher risk for recurrent vascular events.<sup>554</sup>



Regarding the natural history of aortic arch atheroma, Sen et al<sup>555</sup> noted progression in 29% and regression (defined as an increase or decrease in plaque thickness by 1 grade or greater, respectively) in 9%. Montgomery et al<sup>556</sup> reported 30 patients with moderate-to-severe aortic plaque noted on initial bi/multiplanar TEE as part of a workup for cardiac or an embolic event. Over a mean of 1 year, progression was reported in 23% and regression in 10%. Pistavos et al<sup>557</sup> used monoplanar TEE in 16 patients with familial hypercholesterolemia taking pravastatin to show progression in 19% and regression in 38% over 2 years. Geraci and Weinberger,<sup>558</sup> using supraclavicular B-mode ultrasonography of the proximal aortic arch in 89 patients evaluated for transient neurologic symptom, noted a progression rate of 19% and a regression rate of 18% over a mean of 7.7 months (range 3 to 18 months). Sen et al<sup>559</sup> confirmed that in patients with stroke/TIA, aortic arch atheroma progression over 12 months is associated with more vascular events.

### 11.3. Risk Factors

Risk factors for the development of aortic atheroma include age, sex, heredity, hypertension, diabetes mellitus, hyperlipidemia, sedentary lifestyle, smoking, and endothelial dysfunction. Other factors include elevated levels of inflammatory markers (ie, serum C-reactive protein), homocysteine, or lipoprotein.<sup>560,561</sup> Risk factors for embolic complications include inflammation, shear forces of hypertension, plaque hemorrhage aneurysm formation, and iatrogenic manipulation. The likelihood of embolization is also increased with complex aortic plaque, defined as plaque that contains mobile thrombi or ulcerations or is 4 mm or greater in thickness.<sup>562</sup> Plaques with a larger lipid core, a predominance of macrophages, a thin fibrous cap, and a lack of calcification are more "vulnerable" to disruption or rupture. Calcified plaques are more stable and less likely to result in embolic syndromes.<sup>562,564–565</sup>

### 11.4. Diagnosis

Methods of imaging the aortic arch to detect and/or measure plaque include:

**Transesophageal Echocardiography.** TEE can provide information of plaque mobility, ulceration, and composition,<sup>566</sup> as well as details on the anatomic relationship of the plaque to the origin of the great vessels<sup>69</sup> with excellent interobserver and intraobserver reliability.<sup>567</sup> Limitations of TEE in patients with stroke include the need for conscious sedation, patient cooperation for swallowing the probe, and risk of structural damage.<sup>566</sup> A small portion of the ascending aorta is masked by the tracheal air column near the origin of the innominate artery, with an estimated 2% of plaques being missed.<sup>568</sup> Multiplanar probes may reduce tracheal shadowing seen with monoplanar and biplanar probes.<sup>569</sup>

**Transthoracic Echocardiography.** TTE can usually image the aortic root and proximal ascending aorta but cannot adequately assess aortic arch plaque.<sup>570,571</sup>

**Epi-aortic Ultrasonography.** Epi-aortic imaging is useful to detect aortic arch plaque in the operative setting when the

transducer may be placed directly over the aortic arch. The information may be used to select operative techniques such as off-pump coronary artery bypass grafting to avoid cannulation or cross-clamping of the aorta and reduce risk of perioperative strokes.<sup>572,573</sup>

**Contrast Aortography.** The risk of invasive angiography and the need for contrast injection and radiation make contrast aortography less useful to assess aortic arch plaque in patients with stroke.<sup>574</sup>

**Magnetic Resonance Imaging.** MR has been validated against TEE for detection and measurement of aortic arch plaque (80% overall agreement).<sup>568,575</sup> It has limited use in patients who are obese, have metallic implants, or are claustrophobic. Contrast MR angiography underestimates the plaque thickness but can identify morphologic features including calcification, fibrocellular tissue, lipid, thrombus, and features used to detect plaque stability and may be used to monitor aortic arch plaque progression and regression.<sup>572</sup>

**Computed Tomography.** CT can reliably detect and measure protruding aortic arch plaques<sup>568,576</sup> and is the test of choice for detecting vascular calcification. Nonenhanced dual-helical CT may underestimate the amount of noncalcified plaque and mobile thrombus that presumably is at high risk for embolization.<sup>568</sup> In conjunction with positron emission tomography it can be used to localize fluorodeoxyglucose uptake by the plaque, identifying active plaques and unstable plaques,<sup>577</sup> but its clinical utility has yet to be established.

### 11.5. Treatment

There is no definitive therapeutic regimen for this high-risk patient group because no randomized trial has been completed.

#### 11.5.1. Anticoagulation Versus Antiplatelet Therapy

Mobile aortic atheroma have been noted to disappear during anticoagulant therapy<sup>546</sup> or with the use of a thrombolytic agent.<sup>578</sup> However, there is concern about the use of warfarin in patients with aortic atheroma because of the theoretical risk of plaque hemorrhage resulting in atheroemboli syndrome (ie, blue toes, renal failure, intestinal infarction).<sup>579</sup> Anticoagulation has been associated with worsening,<sup>580,581</sup> as well as improvement of an aortic thrombus on anticoagulation in a patient with the atheroemboli syndrome.<sup>582</sup> Cholesterol emboli have been documented on skin, muscle, and renal biopsy samples in patients with aortic arch atheroma seen on TEE.<sup>553,583</sup> However, the risk of clinical atheroemboli syndrome during warfarin therapy in such patients appears to be low (only 1 episode in 134 patients according to the SPAF [Stroke Prevention in Atrial Fibrillation] trial).<sup>562</sup>

Three reports shed light on the potential benefit of warfarin in patients with aortic arch atheroma. The first described 31 patients with mobile lesions in the aorta on TEE<sup>585</sup> where a higher incidence of vascular events was seen in patients who were not treated with warfarin compared with those treated with warfarin (at the discretion of the referring physicians) (45% versus 5%). In the SPAF randomized trial of patients

with “high-risk” nonvalvular atrial fibrillation, the risk of stroke at 1 year in 134 patients with complex aortic plaque was found to be reduced from 15.8% (11 events) in those treated with fixed low-dose warfarin plus aspirin (INR 1.2 to 1.5) to only 4% (3 events) in those treated with adjusted-dose warfarin (INR 2.0 to 3.0), a 75% RR reduction ( $P=0.02$ ) for patients with atheromas who received “therapeutic range” anticoagulation.<sup>562</sup> A third observational study reported on 129 patients with aortic arch atheroma on TEE performed to look for a source of cerebral or peripheral embolization.<sup>586</sup> Treatment with oral anticoagulation, aspirin, or ticlopidine was not randomly assigned. There was a significant reduction in the number of embolic events in patients with plaques greater than or equal to 4 mm who received oral anticoagulants (0 events in 27 patients versus 5 events in 23 patients treated with antiplatelet agents) (OR 0.06, 95% CI 0.003 to 1.2,  $P=0.016$ ). For patients with mobile lesions, there was a significant reduction in mortality while on anticoagulants, although the trend toward fewer embolic events did not reach statistical significance in this group.

These 3 reports suggest that warfarin is not harmful in patients with aortic arch atheroma and may reduce stroke rates. However, these studies are not randomized trials of treatment for patients with atheromas, and the numbers are relatively small. The current ARCH (Aortic Arch Related Cerebral Hazard) trial is an open-label trial where patients with aortic arch atheroma (4 mm or greater) and nondisabling stroke are being assigned to oral anticoagulation (target INR 2.0 to 3.0) versus aspirin (75 mg/d) plus clopidogrel (75 mg/d) and followed longitudinally for recurrence of vascular events.

### 11.5.2. Lipid-Lowering Agent

There are no randomized trials to support specific lipid-lowering drug therapy for a patient with stroke caused by atheroembolism. However, 2 randomized studies of low-dose and higher-dose statin in patients with aortic and/or carotid plaques showed significant regression in plaque seen on MR, which in 1 study was related to LDL cholesterol level but not statin dosage<sup>587</sup> and, in the other study, was related to both LDL lowering and the statin dosage.<sup>588</sup> It seems likely that statin therapy decreases the risk of stroke. Mechanisms for this effect may involve pleiotropic effects of statins, including plaque regression, plaque stabilization, decreased inflammation, and inhibitory effects on the coagulation cascade at different levels.

No randomized trial on the use of statins in patients with severe aortic plaque has been published. However, in an observational study of 519 patients with severe aortic plaque on TEE,<sup>540</sup> statin use was associated with an RR reduction for ischemic stroke of 59%. Statins have reduced both primary and secondary stroke in a variety of patient populations.<sup>589,590</sup> Hence, a majority of patients with stroke and TIA with identified aortic plaque already have other stronger indications for statin therapy.<sup>409</sup> Recommendations for statins are noted for other manifestations of atherosclerotic diseases<sup>409</sup> (see Section 9.2.1.2). Clinical trials are needed to determine

the effects of statins in patients with severe aortic atheroma and risk of atheroembolism.

### 11.5.3. Surgical and Interventional Approaches

Aortic arch endarterectomy has been attempted for patients with thromboembolism originating from aortic arch atheroma. Although successful in a handful of case reports, this procedure resulted in a relatively high rate (34.9% with endarterectomy versus 11.6% without endarterectomy) of perioperative stroke and mortality when it was performed to limit stroke during cardiac surgical procedures requiring cardiopulmonary bypass (coronary bypass surgery and valve surgery).<sup>545</sup> Covered stents offer the potential advantage of shielding severely diseased aortic segments to prevent further embolization. However, periprocedural embolization may occur during diagnosis or interventional endovascular manipulations. There is insufficient evidence to recommend prophylactic endarterectomy or aortic arch stenting for purposes of stroke prevention.

## 12. Porcelain Aorta

Vascular calcification occurs in the media and represents a central component of atherogenesis, typically signaling longstanding inflammation. The amount of calcification directly associates with the extent of atherosclerosis, and the presence of aortic calcium predicts the presence of coronary heart disease.<sup>443</sup>

With severe atherosclerosis of the aorta, calcification may be severe and diffuse, causing an eggshell appearance seen on chest x-ray or CT.<sup>444</sup> Also termed “porcelain aorta,” this finding is usually noted during operation for coronary heart or valvular heart disease at the time of surgery. The calcification interferes significantly with cannulation of the aorta, cross-clamping, and placement of coronary bypass grafts, increasing the risk of stroke and distal embolism significantly (Figure 36).

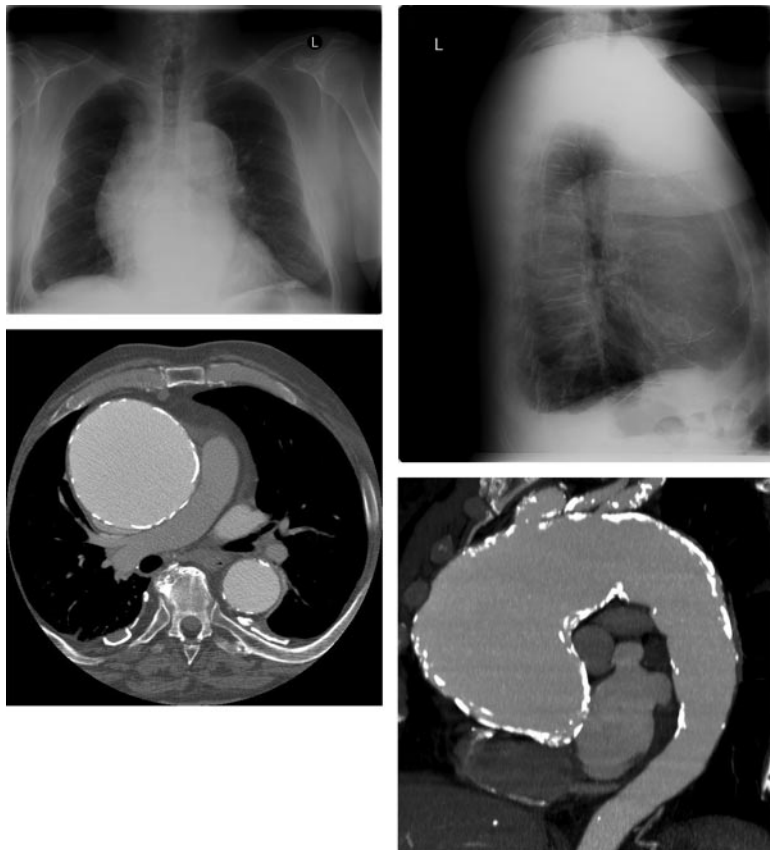
In these patients, direct manipulation of the aorta may result in an unreparable aortic injury and/or distal embolization. Surgeons have used several techniques to reduce adverse neurologic events in these patients: internal aortic balloon occlusion (as apposed to aortic cross-clamping), a “no-touch” technique to avoid the ascending aorta, alternate locations for cannulation or coronary bypass graft anastomoses, replacement of the ascending aorta, and intra-aortic filtration of atherosclerotic debris.<sup>591–599</sup>

## 13. Tumors of the Thoracic Aorta

Neoplasms of the thoracic aorta are usually secondary and related to contiguous spread of adjacent primary malignancies, particularly lung and adjacent primary malignancies, or subsequent metastases, particularly lung and esophagus.<sup>600–603</sup>

Primary neoplasms of the thoracic aorta are rare. A review of the literature between 1873 and 2002 collated a total of 53 thoracic and 10 thoracoabdominal tumors with most lesions protruding into the aortic lumen<sup>604</sup> (Table 16).

Metastatic disease is often demonstrated at the time of diagnosis of primary aortic neoplasms, so that constitutional symptoms of malaise, fatigue, weight loss, and nausea may be



**Figure 36.** Porcelain aorta. Top left and right, PA and lateral chest x-ray show an anterior mediastinal mass with curvilinear calcifications most likely representing the wall of an ascending aortic aneurysm. Bottom left, CT scan slice at the level of the right pulmonary artery confirms a 10-cm aneurysm of the ascending aorta with dense mural calcifications. Bottom right, A maximum intensity projection in the oblique sagittal plane better demonstrates the fusiform aneurysm beginning at the sinotubular ridge and extending into the aortic arch. Dense mural calcification extends into the proximal descending aorta. CT indicates computed tomographic imaging; and PA, posteroanterior.

the presenting complaints. Other presentations can include distal arterial embolization (with histopathologic examination showing neoplasm or identified by imaging techniques during a search for an embolic source).<sup>604–606</sup> AoD may originate in the area of the neoplasm or the aortic occlusion.<sup>607</sup> Resection and reconstruction of the segment of aorta containing the

neoplasm have been described, but because most patients present with metastatic disease, overall prognosis is poor.<sup>608</sup>

**Table 16. Neoplasms of the Thoracic Aorta (Collective Review Incidence)**

Histology	Thoracic Aorta (N=53)	Thoracoabdominal Aorta (N=10)
Sarcoma	15	1
Malignant fibrous histiocytoma	11	1
Angiosarcoma	5	0
Leiomyosarcoma	6	2
Fibrosarcoma	4	0
Myxoma	3	1
Fibromyxosarcoma	1	1
Hemangiopericytoma	2	0
Hemangioendothelioma	2	0
Malignant endothelioma	2	0
Aortic intimal sarcoma	0	2
Myxosarcoma	0	1
Endotheliosarcoma	1	0
Fibromyxoma	0	1
Fibroxanthosarcoma	1	0

Adapted from Oldenburg et al.<sup>604</sup>

## 14. Perioperative Care for Open Surgical and Endovascular Thoracic Aortic Repairs

### 14.1. Recommendations for Preoperative Evaluation

#### Class I

1. In preparation for surgery, imaging studies adequate to establish the extent of disease and the potential limits of the planned procedure are recommended. (*Level of Evidence: C*)
2. Patients with thoracic aortic disease requiring a surgical or catheter-based intervention who have symptoms or other findings of myocardial ischemia should undergo additional studies to determine the presence of significant coronary artery disease. (*Level of Evidence: C*)
3. Patients with unstable coronary syndromes and significant coronary artery disease should undergo revascularization prior to or at the time of thoracic aortic surgery or endovascular intervention with percutaneous coronary intervention or concomitant coronary artery bypass graft surgery. (*Level of Evidence: C*)

#### Class IIa

1. Additional testing is reasonable to quantitate the patient's comorbid states and develop a risk profile.

These may include pulmonary function tests, cardiac catheterization, aortography, 24-hour Holter monitoring, noninvasive carotid artery screening, brain imaging, echocardiography, and neurocognitive testing. (*Level of Evidence: C*)

2. For patients who are to undergo surgery for ascending or arch aortic disease, and who have clinically stable, but significant (flow limiting), coronary artery disease, it is reasonable to perform concomitant coronary artery bypass graft surgery. (*Level of Evidence: C*)

### Class IIb

1. For patients who are to undergo surgery or endovascular intervention for descending thoracic aortic disease, and who have clinically stable, but significant (flow limiting), coronary artery disease, the benefits of coronary revascularization are not well established.<sup>609–611</sup> (*Level of Evidence: B*)

Preoperative evaluation usually includes imaging studies necessary to establish the extent of disease, the limits of the planned procedure, and the clinical risks attendant to the procedure. When the writing committee was polled regarding the extent of usual preoperative laboratory testing, a variety of approaches emerged. In some centers, extensive testing includes pulmonary function tests (particularly for smokers and those with Marfan syndrome), Holter monitoring, and carotid duplex scans. In some centers, brain imaging and neurocognitive testing are performed in patients with aortic arch disease for whom arch repair or replacement requiring a period of deep hypothermic circulatory arrest or low pump flow is planned.<sup>463</sup> Other centers obtain fewer preoperative tests and individualize such testing as cardiac catheterization, 24-hour Holter monitoring, brain imaging, and neurocognitive studies for patients to establish baseline states and risk.

In many centers, where the diagnosis of acute AoD is either made or highly suspected, patients are immediately taken to surgery, and TEE is performed in the operating room to either establish or confirm the diagnosis. Most of the writing committee believes that the delay to obtain coronary angiography was potentially dangerous unless patients had a history of coronary artery bypass graft surgery or a high likelihood of coexisting CAD.

Most patients undergoing elective aortic root and ascending aortic surgery can be admitted the day of surgery. However, some of the writing committee members routinely admit patients the day before surgery primarily for fluid hydration (using 5% dextrose/0.5 normal saline with additional potassium and sodium bicarbonate at 100 to 120 mL/h), particularly those who are to have extensive open surgery for arch, descending thoracic, or thoracoabdominal aortic disease. Preoperative use of acetylcysteine (600 mg by mouth at night and in the morning, or 500 mg in 500 mL of normal saline solution over 3 hours before CT or surgery) has also been described.<sup>612,613</sup> However, the effectiveness of these strategies has not been tested in a clinical trial. Placement of thoracic epidural catheters for postoperative analgesia or lumbar spinal drains for CSF drainage is performed on the day prior to surgery in some centers. Despite lack of evi-

dence, there is concern that neuraxial hemorrhage is more likely if blood returns through the placement needle on the day of surgery.

#### 14.1.1. Preoperative Risk Assessment

MI, low cardiac output, respiratory failure, renal failure, and stroke are the principal causes of mortality and morbidity after operations on the thoracic aorta, and preoperative assessment of these organ systems prior to elective operation is essential,<sup>381,441,614–617</sup> especially in patients with a history of MI, angina pectoris, or symptoms of heart failure and those older than 40 years. Patients with valvular heart disease are evaluated with echocardiography and cardiac catheterization.

Elderly patients with thoracic aortic disease are likely to have coexisting CAD. The benefits of prior or concomitant coronary revascularization are controversial. Several studies suggested that prior coronary bypass graft surgery was of benefit to patients undergoing major vascular surgery to reduce cardiovascular mortality.<sup>618–622</sup>

More recent clinical trials comparing outcomes of patients with stable CAD treated with optimal medical therapy versus revascularization have not shown any significant reductions in cardiovascular events associated with revascularization strategies.<sup>609–611</sup> Major thoracic aortic surgery falls into the highest-risk group for cardiac morbidity and mortality,<sup>623</sup> prompting some writing committee members to aggressively screen for and treat coexisting CAD, but the effectiveness of such a strategy in patients with stable CAD has not been clearly established. For patients with unstable CAD, left main stenosis, or 3-vessel disease, revascularization is generally warranted prior to or concomitant with the thoracic aortic procedure. The use of drug-eluting stents for single- or double-vessel disease may be problematic because required antiplatelet therapies may significantly raise the risk of bleeding with the thoracic aortic procedure and withholding antiplatelet therapies clearly increases the risk of stent thrombosis.

History of smoking and presence of chronic pulmonary disease are important predictors of postoperative respiratory complications and are frequently present in patients with thoracic aortic disease.<sup>624</sup> Pulmonary function tests and arterial blood-gas analyses help to risk-stratify patients with chronic pulmonary disease. If reversible restrictive disease or excessive sputum production is present, antibiotics and bronchodilators should be administered. Cessation of smoking is advisable.

Preoperative renal dysfunction is the most important predictor of acute renal failure after operations on the thoracic aorta.<sup>617,625,626</sup> Preoperative hydration and avoidance of hypotension, low cardiac output, and hypovolemia in the perioperative period may reduce the prevalence of this complication.

To minimize the risk of stroke or reversible ischemic neurologic deficits and to determine the potential magnitude of risk, duplex imaging of the carotid arteries and angiography of the brachiocephalic arteries is often performed preoperatively particularly in patients with a history of stroke, TIA, or other risk factors for cerebrovascular disease.<sup>627</sup> However, the efficacy of treatment of significant carotid stenosis prior

to endovascular or open surgery for thoracic aortic disease has not been evaluated in a randomized clinical trial.

Although older age is a risk factor for increased early and late death after operations on the thoracic aorta,<sup>382,441,617,625,627–630</sup> operations can be carried out successfully with satisfactory outcomes in appropriately selected older patients. Emergency operation for aortic rupture or acute dissection is associated with a higher risk of early death after operation compared with elective operation.<sup>47</sup>

## 14.2. Recommendations for Choice of Anesthetic and Monitoring Techniques

### Class I

1. **The choice of anesthetic techniques and agents and patient monitoring techniques should be tailored to individual patient needs to facilitate surgical and perfusion techniques and the monitoring of hemodynamics and organ function. (Level of Evidence: C)**

### Class IIa

1. **Transesophageal echocardiography is reasonable in all open surgical repairs of the thoracic aorta, unless there are specific contraindications to its use. Transesophageal echocardiography is reasonable in endovascular thoracic aortic procedures for monitoring, procedural guidance, and/or endovascular graft leak detection.<sup>631–633</sup> (Level of Evidence: B)**
2. **Motor or somatosensory evoked potential monitoring can be useful when the data will help to guide therapy. It is reasonable to base the decision to use neurophysiologic monitoring on individual patient needs, institutional resources, the urgency of the procedure, and the surgical and perfusion techniques to be employed in the open or endovascular thoracic aortic repair.<sup>634,635</sup> (Level of Evidence: B)**

### Class III

1. **Regional anesthetic techniques are not recommended in patients at risk of neuraxial hematoma formation due to thienopyridine antiplatelet therapy, low-molecular-weight heparins, or clinically significant anticoagulation.<sup>636</sup> (Level of Evidence: C)**
2. **Routinely changing double-lumen endotracheal (endobronchial) tubes to single-lumen tubes at the end of surgical procedures complicated by significant upper airway edema or hemorrhage is not recommended. (Level of Evidence: C)**

Choice of anesthetic technique is dependent on the planned surgical interventions and the patient's comorbid conditions. For placement of endovascular aortic stent grafts, different anesthetic (local, regional, general) techniques have been described, although adequate comparative studies are lacking.<sup>637–643</sup> Percutaneous placement of catheters with a limited incision may be tolerated with local anesthesia and sedation. Extensive inguinal dissection or the construction of a femoro-femoral bypass may favor either regional or general anesthesia. If surgical dissection is extended into the retroperitoneum, a higher level of regional anesthesia or general

anesthesia is required. If the patient is undergoing local anesthesia or regional anesthesia, adequate intravenous sedation is necessary because of agitation secondary to restlessness and pain from lying in one position for a prolonged period of time.

Retrospective studies indicate that patients having local versus regional or general anesthesia for endovascular stent grafts tend to have lower use of vasoactive agents and lower fluid requirements, shorter intensive care and hospital stays,<sup>642</sup> earlier ambulation and gastrointestinal function,<sup>637</sup> and lower incidence of respiratory and renal complications.<sup>643</sup> In a large multicenter retrospective study of 5557 patients undergoing endovascular aortic repairs,<sup>644</sup> 69% received general anesthesia, 25% received regional anesthesia, and 6% received local anesthesia. The incidence of cardiac complications were significantly lower in both the local or regional anesthesia group compared with general anesthesia (1.0% versus 2.9% versus 3.7%), and the incidence of sepsis was significantly lower in the regional anesthesia group compared with general anesthesia (0.2% versus 1.0%). Selection bias and complexity of disease likely affect these results.

#### 14.2.1. Temperature Monitoring

At most centers, temperature is monitored in at least 2 locations that estimate the brain/core (eg, blood, esophageal, tympanic membrane, nasopharynx) temperature and the visceral (eg, bladder or rectal) temperature.<sup>645</sup>

#### 14.2.2. Hemodynamic Monitoring

Invasive arterial pressure monitoring is required in 1 or more sites depending on the surgical plan for cannulation and perfusion, particularly for thoracoabdominal aortic repairs. Arterial pressure is universally monitored proximal to aortic cross-clamping sites, but there is institutional variability in the monitoring of distal arterial (aortic) pressure, even when distal aortic perfusion is performed.

Central venous cannulation allows measurement of cardiac filling pressures, providing a route for vasoactive drug and fluid administration. Femoral venous catheterization is discouraged by current central line-associated bloodstream infection prevention guidelines, but the literature does not address the subject in thoracoabdominal surgery.<sup>646,647</sup> Nevertheless, many experienced centers use short-term catheterization of the femoral vein for volume management during surgery.

Pulmonary artery catheterization is performed routinely in many institutions for thoracic aortic surgery. The literature does not specifically address the subject of thoracic aortic surgery, but the general perioperative literature does not support the use of pulmonary artery catheterization.<sup>631</sup>

#### 14.2.3. Transesophageal Echocardiography

TEE is safe<sup>648</sup> and is used to confirm the preoperative diagnoses and detect pericardial or pleural effusions, aortic regurgitation, the extent of dissection, the location of intimal tears, the size and integrity of aneurysms, and the presence of appropriate flow in the true lumen upon commencement of cardiopulmonary bypass. Current American Society of Anesthesiologists and the Society of Cardiovascular Anesthesiologists guidelines for TEE include the following<sup>631</sup>:

**Category I** Indications (supported by the strongest evidence or expert opinion):

- Preoperative use in unstable patients with suspected thoracic aortic aneurysms, dissection, or disruptions that need to be evaluated quickly.
- Intraoperative assessment of aortic valve function in repair of AoDs with possible aortic valve involvement.

**Category II** Indications (supported by weaker evidence or expert opinion):

- Preoperative assessment of patients with suspected thoracic AoDs, aneurysms, or disruption.
- Intraoperative use during repair of thoracic AoDs without suspected aortic valve involvement.

#### 14.2.4. Transesophageal Echocardiography for Endovascular Repairs of the Descending Thoracic Aorta

TEE can provide views of the aorta and location of guidewires and endografts prior to deployment in relation to the normal and diseased thoracic aorta.<sup>649,650</sup> TEE has distinct advantages over angiography by providing exact vessel and lesion sizing and localization and can also be used to estimate endograft size and location. Although not imaged in all patients, large intercostal arteries have been imaged, thus avoiding inadvertent obstruction by the aortic stent graft. After stent graft placement, the presence or absence of endoleaks can be determined by TEE with a high degree of sensitivity and specificity particularly compared with contrast angiography.<sup>632,633,650</sup> Finally, because most of these patients have severe concomitant cardiac disease, perioperative TEE allows dynamic assessments of cardiac function.

Intravascular ultrasound is used for endovascular procedures to visualize precise localization of branch arteries and for measurement of aortic and branch artery sizes. Plaques, tears, and saccular aneurysms can also be very accurately demonstrated.

### 14.3. Airway Management for Descending Thoracic Aortic Repairs

A double-lumen endotracheal tube or various types of endobronchial blockers facilitate surgical exposure.<sup>651</sup> For extensive surgery of the left thorax, single-lung ventilation provides better surgical exposure, reduces the need for pulmonary retraction, may decrease the severity of iatrogenic pulmonary contusion, and protects the right lung from contamination by blood and secretions. A large descending thoracic aortic aneurysm may compress or distort the left main bronchus such that left-sided endobronchial tubes must be used with caution. If a right-sided double-lumen endotracheal tube is placed, endoscopic confirmation of tube position (to ensure right upper lobe ventilation) is necessary. Forceful endobronchial tube placement has been associated with thoracic aortic aneurysm rupture. Therefore, using a different tube or lung isolation method may be required when severe airway distortion is encountered.

At the end of surgery, some centers have advocated changing a double-lumen endotracheal tube to a single-lumen tube to facilitate pulmonary toilet and to avoid the complica-

tions associated with tube malposition in the intensive care unit. The decision to change the double-lumen endotracheal tube to a single-lumen tube should be made after carefully evaluating the extent of airway edema, as these procedures are associated with significant facial and laryngeal edema. Advanced airway management devices, such as tube exchanges and video laryngoscopy, may be of benefit; however, there is no literature addressing this subject.

### 14.4. Recommendation for Transfusion Management and Anticoagulation in Thoracic Aortic Surgery

#### Class IIa

1. **An algorithmic approach to transfusion, antifibrinolytic, and anticoagulation management is reasonable to use in both open and endovascular thoracic aortic repairs during the perioperative period. Institutional variations in coagulation testing capability and availability of transfusion products and other prothrombotic and antithrombotic agents are important considerations in defining such an approach.**<sup>652</sup> (*Level of Evidence: C*)

Thoracic aortic surgery is associated with hemorrhage from several interrelated causes, including extensive surgical dissection, arterial and venous bleeding, hypothermia, cardiopulmonary bypass, fibrinolysis, dilution or consumption of coagulation factors, thrombocytopenia, poor platelet function, heparin and other anticoagulants, preoperative antithrombotic therapy, and other congenital and acquired coagulopathies. The extensive blood product and fluid requirements of open thoracic aortic surgical repairs may exceed the total blood volume of the patient in the most complicated cases. Clinical practice guidelines for perioperative blood transfusion and blood conservation in cardiac surgery have been published by the STS and the SCA.<sup>652</sup>

These guidelines do not specifically address open or endovascular descending thoracic aortic repairs, but the writing committee supports treatment strategies provided by these guidelines.

Coagulopathies in open descending thoracic aortic and thoracoabdominal repairs mirror many of the abnormalities seen in cardiac and thoracic aortic procedures requiring cardiopulmonary bypass. Illig and colleagues<sup>653</sup> reported significantly decreased euglobulin clot lysis times, elevated tissue plasminogen activator levels, elevated tissue plasminogen activator-to-plasminogen activator inhibitor-1 ratios, and reduced alpha 2-antiplasmin levels within 20 minutes after supraceliac cross-clamping, compared with infrarenal occlusion, consistent with a primary fibrinolytic state. Visceral ischemia may be the condition that initiates fibrinolysis. During supraceliac occlusion, fibrinolysis was attenuated when superior mesenteric artery perfusion was maintained via a shunt.<sup>654</sup> Peripheral ischemia may also result in fibrinolysis. Within 30 minutes of the onset of acute peripheral ischemia (with infrarenal aortic occlusion) fibrinolytic activity increased, as demonstrated by an increase in tissue-type plasminogen activity and a decrease in plasminogen activator

inhibitor activity. This increase in tissue-type plasminogen activity resulted from release of stores from ischemic vascular tissues.<sup>655</sup> Endotoxemia during aortic occlusion may also be associated with fibrinolysis.<sup>656</sup>

To counteract fibrinolysis, the use of lysine analogs epsilon-aminocaproic acid and tranexamic acid has been reported in cardiac surgery. The epsilon-aminocaproic acid loading or bolus dose ranged from 75 to 150 mg/kg, with additional dosing from 12.5 to 30 mg/kg/h infused over varying time periods. For tranexamic acid, loading or bolus dose, ranged from 2.5 to 100 mg/kg, with additional dosing from 0.25 to 4.0 mg/kg/h delivered over 1 to 12 hours.<sup>657</sup> In a study of 21 adult cardiac surgical patients, the tranexamic acid dosing regimen of 10 mg/kg initial dose, followed by an infusion of 1 mg/kg/h resulted in adequate plasma concentrations defined by in vitro studies to prevent fibrinolysis, with relatively stable drug levels throughout cardiopulmonary bypass.<sup>658</sup> Antifibrinolytic therapy for thoracoabdominal aortic surgery with distal perfusion was not associated with decreased bleeding or transfusion in a retrospective cohort of 72 patients.<sup>659</sup> The strong evidence derived from other cardiac surgical studies has led to very common use of antifibrinolytic therapy in thoracic aortic surgery, despite the absence of specific evidence in this surgical subset.

## 14.5. Organ Protection

### 14.5.1. Recommendations for Brain Protection During Ascending Aortic and Transverse Aortic Arch Surgery

#### Class I

1. **A brain protection strategy to prevent stroke and preserve cognitive function should be a key element of the surgical, anesthetic, and perfusion techniques used to accomplish repairs of the ascending aorta and transverse aortic arch.**<sup>660–666</sup> (*Level of Evidence: B*)

#### Class IIa

1. **Deep hypothermic circulatory arrest, selective antegrade brain perfusion, and retrograde brain perfusion are techniques that alone or in combination are reasonable to minimize brain injury during surgical repairs of the ascending aorta and transverse aortic arch. Institutional experience is an important factor in selecting these techniques.**<sup>211,615,667–688</sup> (*Level of Evidence: B*)

#### Class III

1. **Perioperative brain hyperthermia is not recommended in repairs of the ascending aortic and transverse aortic arch as it is probably injurious to the brain.**<sup>689–691</sup> (*Level of Evidence: B*)

A brain protection strategy is an essential component of the operative technique for open surgical repairs of the ascending aorta and/or the aortic arch. Moderate or profound hypothermia with periods of circulatory arrest and/or selective antegrade brain perfusion and/or retrograde brain perfusion are the common strategies for achieving brain protection. The

experience and outcomes of the operating surgeon and the institution are important considerations in selecting a brain protection strategy.

Achieving brain hypothermia is nearly universally performed using extracorporeal circulation, with temperatures ranging from 12° to 30°C. Retrograde (via jugular vein) brain perfusion is usually performed at a perfusion pressure of 20 to 40 mm Hg at a mildly or profoundly hypothermic temperature. Antegrade brain perfusion is usually performed at a perfusion pressure of 50 to 80 mm Hg and may be instituted by direct cannulation of the brachiocephalic arteries, side-graft anastomosis to the axillary artery, or direct cannulation of a portion of graft material that was anastomosed to the brachiocephalic arteries during a period of hypothermic circulatory arrest. The rewarming of a patient following completion of the repair of the thoracic aorta is usually performed at a measured rate so as not to induce brain hyperthermia.

The reviewed literature describes an evolution of brain protection techniques over the past 2 to 3 decades. Deep hypothermic circulatory arrest emerged as the first technique, but as a sole method of brain protection, it was limited by increasing rates of neurologic morbidity, other adverse outcomes, and mortality as the period of arrest exceeded 25 to 45 minutes.<sup>671,692</sup> Deep hypothermic arrest without perfusion adjuncts has been successful, especially when arrest intervals are less than 40 minutes.<sup>693</sup> Subsequently, various combinations of retrograde brain perfusion and selective antegrade brain perfusion were developed to extend the “safe period” of interruption of full extracorporeal circulation. Monitoring of brain function and metabolic suppression by electroencephalography, evoked potentials, bispectral index, noninvasive cerebral oximetry, and jugular bulb oxyhemoglobin saturation are additional means used to guide the onset of extracorporeal circulation interruption for repairing the distal ascending aorta and/or aortic arch. Some centers use barbiturates, calcium channel blockers, or steroids for added protection, but no prospective randomized trials have been performed to test the efficacy of pharmacological agents.<sup>211,459</sup>

There is controversy regarding the ability of retrograde brain perfusion to support brain metabolic function and to improve neurologic outcomes, including transient postoperative neurologic dysfunction, stroke rates, and mortality.<sup>661,671,673–675,694–699</sup> However, this technique can maintain brain hypothermia<sup>700</sup> and has been associated with improved outcomes in the centers where it is used as a primary neuroprotection strategy.

Selective antegrade brain perfusion may be provided by direct cannulation of 1 or more of the brachiocephalic arteries, which permits brain perfusion with minimal periods of interruption. If unilateral cannulation is performed, success may depend on patency of the circle of Willis. Alternatively, unilateral direct or side-graft cannulation of the (usually right) axillary artery permits extracorporeal circulation and cooling without manipulation of the diseased thoracic aorta. This same cannula can then be used for delivering antegrade brain perfusion immediately after the section of aorta from which the brachiocephalic arteries originate is sutured to the

graft or immediately after the brachiocephalic vessels are individually anastomosed to a trifurcated graft. The time required to complete these maneuvers requires a relatively shorter period of hypothermic circulatory arrest compared with complete reconstruction of the aortic arch.<sup>681,683,701–704</sup> Bilateral brachiocephalic artery cannulation has also been reported.<sup>705</sup> The literature is insufficient to determine whether unilateral or bilateral perfusion or complete avoidance of circulatory arrest is associated with improved outcomes. A retrospective analysis by Svensson et al<sup>449</sup> suggested that axillary artery perfusion via a prosthetic side-graft was associated with improved outcomes compared with femoral arterial cannulation.

Finally, direct cannulation of the aortic replacement graft may be used to institute antegrade brain perfusion following a period of circulatory arrest. The variability of techniques among surgical centers makes direct comparison difficult; however, most studies with some type of antegrade arterial brain perfusion report outcomes that are comparable to or better than those using hypothermic circulatory arrest alone or retrograde brain perfusion.<sup>660,662,666,685,686,706,707</sup> Furthermore, selective antegrade brain perfusion may reduce the period of brain ischemia and permit less profound hypothermia, which may be associated with good clinical outcomes.<sup>676,687,708–712</sup>

Our ability to create evidence-based guidelines from the literature is particularly difficult in the case of brain protection. Changes in surgical technique, perfusion technology, anesthetic and intensive care management, coagulation management, prosthetic graft materials, and the experience of the reporting centers and lack of randomized clinical trials are confounding factors.

#### **14.5.2. Recommendations for Spinal Cord Protection During Descending Aortic Open Surgical and Endovascular Repairs**

##### **Class I**

- 1. Cerebrospinal fluid drainage is recommended as a spinal cord protective strategy in open and endovascular thoracic aortic repair for patients at high risk of spinal cord ischemic injury.**<sup>522,523,713</sup> (*Level of Evidence: B*)

##### **Class IIa**

- 1. Spinal cord perfusion pressure optimization using techniques, such as proximal aortic pressure maintenance and distal aortic perfusion, is reasonable as an integral part of the surgical, anesthetic, and perfusion strategy in open and endovascular thoracic aortic repair patients at high risk of spinal cord ischemic injury. Institutional experience is an important factor in selecting these techniques.**<sup>380,382,714,715</sup> (*Level of Evidence: B*)
- 2. Moderate systemic hypothermia is reasonable for protection of the spinal cord during open repairs of the descending thoracic aorta.**<sup>525</sup> (*Level of Evidence: B*)

##### **Class IIb**

- 1. Adjunctive techniques to increase the tolerance of the spinal cord to impaired perfusion may be considered**

**during open and endovascular thoracic aortic repair for patients at high risk of spinal cord injury. These include distal perfusion, epidural irrigation with hypothermic solutions, high-dose systemic glucocorticoids, osmotic diuresis with mannitol, intrathecal papaverine, and cellular metabolic suppression with anesthetic agents.**<sup>520,715–717</sup> (*Level of Evidence: B*)

- 2. Neurophysiological monitoring of the spinal cord (somatosensory evoked potentials or motor evoked potentials) may be considered as a strategy to detect spinal cord ischemia and to guide reimplantation of intercostal arteries and/or hemodynamic optimization to prevent or treat spinal cord ischemia.**<sup>483,634,718,719</sup> (*Level of Evidence: B*)

Paraparesis and paraplegia are perhaps the most feared complications following repair of the descending thoracic aorta. Although rates as high as 23% have previously been reported, the current incidence is probably somewhere around 2% to 6%.<sup>483,521,634,718,720</sup> In any specific patient, however, the likelihood of neurological complications depends highly on individual anatomy, on whether the aorta is dissected or aneurysmal, and on whether the pathology is acute, chronic, or both.

Risk factors for perioperative spinal cord injury include emergency surgery, dissection, extensive disease, prolonged aortic cross-clamp time, aortic rupture, level of aortic cross-clamp, patient age, prior abdominal aortic surgery, and, in particular, hypogastric artery exclusion,<sup>143,144,721</sup> as well as a history of renal dysfunction. The risk of paraplegia or paraparesis is minimal if the aortic cross-clamp time is less than 15 minutes.<sup>722</sup> Svensson et al<sup>381</sup> reported a 20% risk of neurological injury if aortic cross-clamp time was greater than 60 minutes and less than 10% if aortic cross-clamp time was less than 30 minutes. Although paraplegia or paraparesis has been reported with aortic cross-clamp times of less than 20 minutes,<sup>723</sup> others have concluded that aortic cross-clamp times greater than 40 minutes did not result in increases in adverse spinal cord outcome, if distal perfusion was used.<sup>382</sup> One study of patients undergoing open or endovascular repair of descending thoracic or thoracoabdominal aortic aneurysms demonstrated a higher risk of spinal cord injury related to the extent of aorta treated but no difference between the operative approaches.<sup>724</sup>

Another option for spinal cord protection is deep hypothermic circulatory arrest.<sup>630</sup> This has been a useful technique for complex descending thoracic or thoracoabdominal aortic repairs performed via a left thoracotomy approach.

##### **14.5.2.1. Monitoring of Spinal Cord Function in Descending Thoracic Aortic Repairs**

In general, the comparatively low current incidence of neurologic complications is attributable to the routine use of multimodal neurophysiologic monitoring such as somatosensory evoked potentials (SSEP) and motor evoked potentials (MEP) in conjunction with neuroprotective strategies noted later.<sup>526</sup> Although these neuroprotective strategies continue to evolve and may differ slightly in their implementation from center to center, monitoring of evoked potentials during these cases has become common because it provides the surgeon and anesthesiologist the opportunity to promptly intervene if



alterations in monitored potentials indicate neurologic compromise is occurring.<sup>524,526,719,725,726</sup>

SSEPs are cerebral cortical electrical potentials recorded with scalp electrodes during electrical stimulation of the posterior tibial or peroneal nerves of the lower extremities, conducted via the lateral and posterior columns of the spinal cord.<sup>727</sup> Because SSEP monitoring is less sensitive to anesthetic drugs and paralytic agents may be used, its use is less complex than MEP monitoring. SSEP monitoring is limited because it is only dependent on the integrity of the lateral and posterior columns. The anterior motor column is more likely to be affected by ischemic injury during aortic reconstruction. It is thus possible to sustain an isolated perioperative anterior column injury without changes in SSEPs. In 1 study, SSEP monitoring influenced the surgical strategy in 17 of 63 patients (27%) undergoing descending aortic reconstruction.<sup>719</sup> Corrective interventions included partial cardiopulmonary bypass initiated in 1 patient with traumatic aortic rupture; reimplantation of critical intercostal, lumbar, or sacral arteries in 11 patients; suture closure of profusely back-bleeding intercostal arteries in 1 patient; hastening the proximal suture line in 1 patient; distal clamp repositioning to a more proximal position in 1 patient; and proximal clamp repositioning in 2 patients with left carotid ischemia. The authors reported no cases of unexplained SSEP abnormalities. New immediate paraplegia was observed in 1 patient with sustained SSEP absence, and 2 patients presented with delayed paraplegia despite normal inoperative SSEP.

In contrast, MEPs are performed by stimulating the motor cortex (by either high-voltage short-duration electrical stimulus or magnetic induction)<sup>728</sup> and recording at the level of the spinal cord, peripheral nerves, or muscles.<sup>524,526,725–727</sup> Neurogenic MEPs are responses recorded at the peripheral nerves, whereas myogenic MEPs are large biphasic responses recorded over the muscle belly. Because the amplitude of the response is proportional to the number of motor neurons being stimulated, these evoked potentials are very sensitive to neuromuscular blocking and anesthetic agents.<sup>729–738</sup>

Monitoring of SSEPs alone has not been demonstrated to improve outcomes in patients undergoing TAA repair. SSEP monitoring is associated with delayed ischemia detection compared with transcranial MEPs,<sup>739</sup> as well as high rates of both false-negative and false-positive results.<sup>635,739</sup> Lyon et al<sup>740</sup> reported a significantly higher voltage threshold for the generation of a 50 microV amplitude signal at the end of the procedure compared with the beginning of the procedure (“anesthetic fade”). This increased voltage threshold was directly proportional to the length of anesthetic exposure. Recognition of this phenomenon is important to avoid false-positive MEP interpretation.

To demonstrate the greater sensitivity of MEP than SSEP monitoring, Dong et al<sup>634</sup> reported their experience with 56 patients undergoing descending aortic reconstruction. All patients were monitored with both MEPs and SSEPs. Sixteen patients (29%) had MEP evidence of perioperative spinal cord ischemia compared with 4 patients (7%) with SSEP changes. These changes were reversed in 13 patients with either segmental artery reimplantation or optimization of hemodynamics. Although one

of these 13 patients awoke with immediate paraplegia, the remaining 3 patients awoke paraplegic. All 3 patients had normal perioperative SSEPs.

#### 14.5.2.2. Maintenance of Spinal Cord Arterial Pressure

Proximal hypertension may increase the contribution of the vertebral artery–derived blood flow to the spinal cord as well as collateral flow. Other methods of maintaining arterial flow to the spinal cord include the aggressive reimplantation of major intercostal arteries into the aortic graft.<sup>715</sup> Griep et al<sup>742</sup> emphasized the importance of prompt ligation of non-implanted intercostal arteries to avoid “steal” from bleeding during periods of ischemia to this collateral bed.<sup>741</sup> Intrathecal papaverine has also been described as a method of inducing spinal cord arterial dilation, and thus increasing spinal cord blood flow.

The literature is unclear with respect to the benefits of distal perfusion alone on spinal cord protection because the technique is not used in isolation. Several studies support the concept that distal perfusion combined with CSF drainage is beneficial.<sup>380,382,468,714</sup> The minimum desirable distal arterial pressure is 60 mm Hg to ensure adequate spinal cord blood flow, whereas maximal proximal mean arterial pressure should be about 90 to 100 mm Hg.<sup>743</sup>

#### 14.5.2.3. Cerebrospinal Fluid Pressure and Drainage

Application of a cross-clamp to the proximal descending aorta not only creates a major hemodynamic load on the heart but also causes an acute elevation in CSF pressure.<sup>744</sup> Surgical retraction of the aortic arch may also produce significant increases in CSF pressures.<sup>745</sup> When CSF pressure exceeds spinal venous pressure, a “critical closing pressure” is achieved, and the veins collapse independent of inflow pressure. The spinal cord perfusion pressure is therefore the difference between spinal arterial pressure and CSF pressure.

Coselli et al<sup>522</sup> randomized 145 patients undergoing thoracoabdominal aortic repair with or without CSF drainage. Nine patients (13.0%) in the control group developed paraplegia or paraparesis. In contrast, only 2 patients in the CSF drainage group (2.6%) had deficits develop ( $P=0.03$ ). No patients with CSF drainage had immediate paraplegia. A meta-analysis by Khan and Stansby<sup>713</sup> and the retrospective analysis by Safi and colleagues<sup>523</sup> also concluded that CSF drainage was advantageous in reducing the risk of spinal cord injury in open TAA repairs.

Possible complications of CSF drainage include headache, spinal or epidural hematoma formation or inflammatory reaction, meningitis, and persistent CSF leaks. Subdural hematoma has been reported after thoracic aortic repair with spinal fluid drainage.<sup>746</sup> Introduction of blood into the subarachnoid space may result in vasospasm and decreases in spinal blood flow.<sup>747</sup> Decreases in CSF pressure may occur with phlebotomy, and aggressive use of hyperosmotic agents and hyperventilation may be as effective as spinal drainage in maintaining spinal cord perfusion pressure.<sup>748,749</sup> In a single-center report of 162 patients with CSF drains, 6 patients (3.7%) had catheter-related complications: temporary abducens nerve palsy, 1 patient; retained catheter fragments, 2 patients; retained catheter fragments and meningitis, 1 pa-

tient; isolated meningitis, 1 patient; and spinal headache, 1 patient. There were no neuraxial hemorrhagic complications in this series.<sup>750</sup>

#### 14.5.2.4. Hypothermia

Mild hypothermia may provide significant neuronal protection by mechanisms such as reducing excitatory neurotransmitter release, decreasing free oxygen radical production, decreasing postischemic edema, and stabilizing central nervous system blood flow.<sup>751,752</sup> Hypothermia occurs via passive cooling in a cold operating room with a major incision in addition to cooling blankets and unwarmed intravenous fluids. If an extracorporeal circuit is used, a heat exchanger permits warming or cooling of the body temperature. A temperature of 32°C is usually well tolerated by patients not undergoing full cardiopulmonary bypass. Moderate systemic hypothermia has been associated with improved outcomes following TAA surgery.<sup>525</sup> Arrhythmias, such as atrial fibrillation and even ventricular fibrillation, can occur if hypothermia is too severe.

Epidural infusion of cooled saline may be used to induce regional hypothermia. Although this technique was associated with substantial increases in CSF pressure, a significant reduction in postoperative neurologic deficits was noted.<sup>520,716</sup> A new, self-contained catheter for topical cooling of the spinal cord without infusion into the CSF or CSF pressure rise has been shown in the laboratory to provide topical spinal cord hypothermia, while systemic normothermia is maintained; clinical trials are being organized.<sup>753</sup>

Postischemic hyperemia occurs in the spinal cord.<sup>754</sup> The magnitude of this hyperemia has been demonstrated to be proportional to the incidence of paraplegia. Possible mechanisms for the increased neurologic injury associated with vascular hyperemia include edema formation with the development of a compartment syndrome and subsequently decreased spinal cord perfusion and increased oxygen delivery that may result in greater free oxygen radical species generation.

#### 14.5.2.5. Glucocorticoids and Mannitol

Administration of methylprednisolone (30 mg/kg) before and after aortic occlusion may result in better spinal cord protection.<sup>717</sup> The mechanism of this protection is unclear, but it may be related to decreased spinal cord edema and improved free oxygen radical scavenging. Similarly, mannitol (0.25 to 1.0 g/kg) has been used to modulate the extent of ischemic spinal cord injury. Mannitol is hypothesized to act in similar fashion to methylprednisolone.<sup>715</sup>

### 14.5.3. Recommendations for Renal Protection During Descending Aortic Open Surgical and Endovascular Repairs

#### Class IIb

1. Preoperative hydration and intraoperative mannitol administration may be reasonable strategies for preservation of renal function in open repairs of the descending aorta. (Level of Evidence: C)
2. During thoracoabdominal or descending aortic repairs with exposure of the renal arteries, renal protection by

either cold crystalloid or blood perfusion may be considered.<sup>626,755,756</sup> (Level of Evidence: B)

#### Class III

1. Furosemide, mannitol, or dopamine should not be given solely for the purpose of renal protection in descending aortic repairs.<sup>757,758</sup> (Level of Evidence: B)

In a cohort of 475 patients who underwent descending thoracic aortic repair, 25% developed acute postoperative renal failure, whereas 8% required hemodialysis.<sup>759</sup> Risk factors that are associated with postoperative renal failure after descending thoracic aortic repair include age greater than 50 years, preexisting renal dysfunction, duration of renal ischemia, administration of greater than 5 units or either packed red cells or salvaged washed autologous blood, hemodynamic instability, and diffuse atherosclerosis.<sup>626,759</sup>

There is controversy regarding the protective nature of distal perfusion during aortic occlusion.<sup>626,759</sup> Godet et al<sup>759</sup> observed a decrease in the incidence of renal failure with the use of distal aortic perfusion. Others have observed increases in renal failure with distal perfusion.<sup>626</sup> Selective renal artery perfusion during descending thoracic aortic repair may result in uninterrupted urine production throughout the procedure and may decrease the incidence of renal failure postoperatively.<sup>755</sup>

Pharmacological agents, including mannitol,<sup>760,761</sup> furosemide,<sup>758</sup> or dopamine,<sup>757,761–764</sup> have not been demonstrated to provide renal protection during descending thoracic aortic repair.

### 14.6. Complications of Open Surgical Approaches

**Myocardial infarction (1% to 5%):** This is an uncommon complication but it is associated with CAD or dissection of the coronary artery ostia.<sup>228–234,250,441</sup>

**Heart failure (1% to 5%):** Myocardial protection difficulties and ventricular distention from either aortic valve regurgitation or high right-sided pressures are often factors.<sup>765</sup>

**Infections (1% to 5% superficial, less than 1% deep):** Intraoperative contamination or inadequate or improperly timed antibiotic coverage, obesity, immunosuppression, pulmonary disease, or suboptimal glucose control may be a factor.<sup>766</sup>

**Stroke (2% to 8% permanent):** As noted earlier, brain protection is important in preventing the complication of stroke. The causes are either embolic or ischemic. Patients who on preoperative MR have evidence of ischemic changes and/or reduced neurocognitive function, who are elderly, or who have a history of stroke are at increased risk of a perioperative stroke.<sup>76,99,139,211,449,453,466,767</sup>

**Neurocognitive deficit:** The exact incidence of deficits has not been studied much after circulatory arrest; however, in 1 prospective randomized study, using 51 neurocognitive tests, at 2 to 3 weeks after surgery, 9% of patients had new deficits, and by 6 months, all new deficits had resolved. Patients with preoperative deficits were proved to have further deterioration; indeed, 38% of patients had preoperative deficits.<sup>211,466</sup>

**Reoperation for bleeding (1% to 6%):** Reoperation for bleeding is dependent on the extent of surgery, length of cardiopulmonary bypass, reoperative status, underlying dis-

order, and surgical technique. Obtaining hemostasis prior to coming off cardiopulmonary bypass and correcting all blood coagulation defects are paramount.<sup>765,766</sup>

**Respiratory failure (5% to 15%):** Preoperative pulmonary function testing helps to warn the surgeon about potential postoperative respiratory problems. Sometimes operative technique can be adapted to lessen the risks—for example, shortening pump time and avoiding overtransfusion. Left diaphragmatic incisions and trauma may add to postoperative pulmonary dysfunction. In patients with more than 7 kg of increased weight after surgery, delaying extubation until excess fluid has been eliminated by diuresis is worthwhile. White cell filtration and plasmapheresis on pump may be useful but have not been tested in randomized trials.

**Ventricular arrhythmias (1% to 5%):** Ventricular tachycardia or ventricular fibrillation was a common complication after composite valve graft insertion a decade ago, with reports of 19% to 21% risk. Some of these events were related to undiagnosed myocardial ischemia from coronary button reattachment problems, which are usually apparent during operation or shortly thereafter. Inadequate myocardial protection may also lead to both ventricular arrhythmias and low cardiac output. The increasing use of amiodarone, optimization of potassium and magnesium levels, and better methods of myocardial protection including blood cardioplegia may have reduced this risk. Twenty-four-hour Holter monitoring studies may reveal underlying pathology, such as ischemic changes or prolonged QT interval, particularly in patients with Marfan syndrome, that needs to be addressed.

**Paralysis:** The most feared complication after these types of operations is lower limb paralysis and neurogenic bladder. This occurs in 2% to 4% of descending thoracic aortic repairs and in 3% to 10% of thoracoabdominal aortic repairs.<sup>382,526,724,768–773</sup> Most lesions predominantly involve motor function because the anterior motor nerve cells of the spinal cord are most likely to be involved. The protective measures were discussed earlier. Two thirds of patients with paraparesis will recover, and about half with paraplegia will recover to the point of walking again. Prevention of postoperative hypotension in the intensive care unit and continued CSF drainage for longer than 40 hours is deemed by most authors to be beneficial in reducing the incidence of paraparesis.<sup>380,522,523,525,713</sup>

**Hoarseness:** The incidence of hoarseness is related to whether the arch needs to be clamped and whether the proximal descending aorta at the left subclavian artery needs to be transected. Transection at this level is recommended to avoid damage to the esophagus and to prevent the formation of late aorto-esophageal fistulae. This, however, may result in damage to the recurrent laryngeal nerve as it wraps around the aorta and ligamentum arteriosum, resulting in left vocal cord paralysis. This can usually be improved by vocal cord injection with either gel or collagen.

#### 14.7. Mortality Risk for Thoracic Aortic Surgery

Expected results for risk of death are summarized next.

**Composite valve graft (1% to 5%):** With modern techniques, death after elective repair is unusual.<sup>76,98,99,448</sup> Addi-

tional comorbid states and the need for emergency operation are associated with increased risk.<sup>765</sup>

**Separate aortic valve replacement with ascending aorta repair (1% to 5%)<sup>448,628</sup>:** Comorbid conditions such as advanced age and concomitant coronary bypass graft surgery, as well as emergency operation, are associated with increased risk.<sup>76,99,448,765,774,775</sup>

**Valve-sparing aortic root reconstruction (less than 1% to 1.5%):** These patients are mostly young and otherwise healthy, and thus excellent results are expected compared with other aortic operations. Indeed, in 1 series of over 200 modified David reimplantations, there were no operative deaths.<sup>99</sup> Late 10-year freedom from reoperation is better than 92% for reimplantation procedures but lower for root remodeling procedures.<sup>76,95,98,99,448,776</sup>

**Bicuspid aortic valve and ascending aorta repair (1.5%):** In a large series of over 2000 patients with bicuspid aortic valve surgery, the operative risk of death (1.5%) for patients who had both a bicuspid valve procedure and ascending aortic repair (n=200) was no different than the risk for those who underwent only a bicuspid valve procedure. For patients with Marfan syndrome or connective tissue disorders or bicuspid aortic valves, the long-term prognosis is excellent and reaches an average survival of 70 years.<sup>76,99</sup> Late 10-year risk of reoperation is not as low as for tricuspid aortic valve repair but still is only 9% for bicuspid aortic valve repairs.

**Acute AoD (3.5% to 10% in experienced centers, but higher overall):** The risk of death after surgical repair of acute AoD is strongly influenced by associated stroke, mesenteric ischemia, renal failure, and myocardial ischemia.<sup>337,375,765,777</sup>

**Total arch replacement:** A 2% to 6% risk of death and a 2% to 7% risk of stroke have been reported for these extensive and high-risk procedures. Emergency operation mortality and stroke rates are higher (15% and 14%, respectively).<sup>778</sup> Careful brain and myocardial protection, correction of coagulopathies, and improved operative techniques, including the use of elephant trunk procedure, have led to improved outcomes.<sup>680,779</sup>

**Reoperations:** The risk factors for reoperations are comorbid disease and extent of surgery with results varying between 2% to 6% for the risk of death.<sup>464</sup>

**Descending aortic replacement:** The risk of death with current techniques is 2% to 5% and the risk of paralysis is less than 3% for elective surgical repairs.<sup>382</sup>

**Thoracoabdominal repairs:** The risk of death is strongly influenced by the urgency of surgery, comorbid disease, and extent of repair. Thus, Crawford Type I thoracoabdominal repairs have a risk of death of approximately 5%, but this is doubled to approximately 10% for Type II repairs. The results depicted earlier represent the work performed in high-volume centers and may not reflect results of all institutions at which such surgery is performed.<sup>381,525,768,773,780,781</sup>

The late risk of death after aortic repair is strongly influenced by age and comorbid disease. Furthermore, aortic atherosclerosis disease is a marker for more extensive atherosclerosis. For patients undergoing degenerative and AoD repairs, usually at an average age of the lower 70s, 5-year survival rates of only 60% have been reported for ascending repairs, arch repairs, descending repairs, thoracoabdominal

repairs, and infrarenal repairs.<sup>3,381</sup> Thus, it is initially important to identify and to treat all comorbid disease, particularly CAD, which is the most common cause of late deaths in this population.<sup>381</sup> In patients undergoing elective root-sparing procedures or bicuspid valve procedures, the 5- and 10-year survival rates are considerably improved—better than 80% to 90% 10-year survival rates can be expected.<sup>76,139</sup> Sadly, even young patients with AoD have a dismal 5-year survival rate of 50% after surgery due to residual events related to unresected dissected aorta. This stresses the importance of treating young patients with elective surgery, with a less than 1% risk of death, if they have aortic root dilatation.<sup>75,76</sup>

Repair of TAAs is one of the most extensive and highest-risk operations done in patients. Hence, selection of patients for repair and workup for surgery needs to be diligently performed. Furthermore, the cited results are from reports of single-center experiences and therefore representative of centers of excellence in the treatment of aortic disease. Data from “real world” experiences have demonstrated nearly double the morbidity and mortality rates, especially for high-risk indications like acute aortic dissection and thoraco-abdominal aortic aneurysms, suggesting that high-risk patients may have better outcomes in centers specializing in the treatment of thoracic aortic diseases.<sup>782,783</sup>

## 14.8. Postprocedural Care

### 14.8.1. Postoperative Risk Factor Management

The recognition and treatment of thoracic aortic disease provide the opportunity to engage the patient in long-term cardiovascular risk factor management. Conditions such as aortic atherosclerosis and aortic aneurysm are recognized as high-risk states by the National Cholesterol Education Program, Adult Treatment Panel III and require maximal intensity therapy.<sup>784</sup> In these patients, the risk of a fatal or nonfatal MI is higher than the risk of amputation or aortic rupture. The risk factors with clinical trial evidence of benefit include hypertension, dyslipidemia, and cigarette smoking (see Section 9.2.1).

### 14.8.2. Recommendations for Surveillance of Thoracic Aortic Disease or Previously Repaired Patients

#### Class IIa

1. **Computed tomographic imaging or magnetic resonance imaging of the thoracic aorta is reasonable after a Type A or B aortic dissection or after prophylactic repair of the aortic root/ascending aorta.**<sup>74</sup> (*Level of Evidence: C*)
2. **Computed tomographic imaging or magnetic resonance imaging of the aorta is reasonable at 1, 3, 6, and 12 months postdissection and, if stable, annually thereafter so that any threatening enlargement can be detected in a timely fashion.** (*Level of Evidence: C*)
3. **When following patients with imaging, utilization of the same modality at the same institution is reasonable, so that similar images of matching anatomic segments can be compared side by side.** (*Level of Evidence: C*)
4. **If a thoracic aortic aneurysm is only moderate in size and remains relatively stable over time, magnetic**

**Table 17. Suggested Follow-Up of Aortic Pathologies After Repair or Treatment**

Pathology	Interval	Study
Acute dissection	Before discharge, 1 mo, 6 mo, yearly	CT or MR, chest plus abdomen TTE
Chronic dissection	Before discharge, 1 y, 2 to 3 y	CT or MR, chest plus abdomen TTE
Aortic root repair	Before discharge, yearly	TTE
AVR plus ascending	Before discharge, yearly	TTE
Aortic arch	Before discharge, 1 y, 2 to 3 y	CT or MR, chest plus abdomen
Thoracic aortic stent	Before discharge, 1 mo, 2 mo, 6 mo, yearly Or 30 days*	CXR, CT, chest plus abdomen
Acute IMH/PAU	Before discharge, 1 mo, 3 mo, 6 mo, yearly	CT or MR, chest plus abdomen

\*US Food and Drug Administration stent graft studies usually required before discharge or at 30-day CT scan to detect endovascular leaks. If there is concern about a leak, a pre-discharge study is recommended; however, the risk of renal injury should be borne in mind. All patients should be receiving beta blockers after surgery or medically managed aortic dissection, if tolerated. Adapted from Erbel et al.<sup>539</sup>

AVR indicates aortic valve replacement; CT, computed tomographic imaging; CXR, chest x-ray; IMH, intramural hematoma; MR, magnetic resonance imaging; PAU, penetrating atherosclerotic ulcer; and TTE, transthoracic echocardiography.

**resonance imaging instead of computed tomographic imaging is reasonable to minimize the patient’s radiation exposure.** (*Level of Evidence: C*)

5. **Surveillance imaging similar to classic aortic dissection is reasonable in patients with intramural hematoma.** (*Level of Evidence: C*)

The mean rate of growth for all thoracic aortic aneurysms is approximately 1 mm/y, but that growth rate increases with increasing aneurysm diameter. Growth rates tend to be faster for aneurysms involving the descending versus the ascending aorta, for dissected versus nondissected aortas, for those with Marfan syndrome versus those without,<sup>375</sup> and for those with bicuspid versus those with tricuspid aortic valves.<sup>785</sup> The frequency of surveillance imaging is not clear as there are no data to accurately dictate surveillance intervals. It seems prudent to obtain an initial follow-up imaging study before discharge; at 1, 3, 6, and 12 months postoperatively; and then annually after a thoracic aortic aneurysm is first detected. Assuming the aneurysm is stable in size on the first follow-up study, repeat imaging can reasonably be repeated on an annual basis. For relatively small aneurysms that are stable from year to year on annual imaging, the writing committee believes that an imaging frequency of every 2 to 3 years, especially in older patients, is currently reasonable (Table 17).

The writing committee believes that the anatomical detail provided by CT may be better than that for MR in many instances. However, for surveillance of stable and moderate thoracic aortic aneurysms, MR provides adequate information and avoids the potential problems associated with repeated radiation exposure of CT angiography.

Dissected aortas also tend to dilate progressively over time.<sup>375,786</sup> Therefore, those with a Type B AoD managed medically or those with a Type A AoD with a persistent distal dissection following ascending aortic repair must also undergo periodic surveillance imaging to monitor the affected aorta for further dilatation. When the dissected aorta is relatively stable in size, annual surveillance imaging is usually sufficient. The most proximal portion of the descending thoracic aorta, just beyond the ostium of the left subclavian artery, is most prone to both early and late dilatation. If this segment expands to 6.0 cm or greater or if there is rapid growth, intervention or an open repair may become necessary. Predictors of progressive dilatation or rupture of a dissected aorta include complete patency of the false lumen<sup>787</sup> and a large false lumen size.<sup>788</sup> Those with chronic AoD are also at risk for a second acute dissection arising from the chronic dissection itself or de novo from undissected aorta.

Those with IMH are also at risk of late complications, including conversion to a classic AoD and progressive aortic dilatation. Conversely, in other cases there may be progressive reabsorption of the IMH, and in time the radiographic appearance of the thoracic aorta normalizes. While this is a more favorable outcome, such patients remain at increased risk of late complications as the apparently healed aorta is prone to the development of “ulcer-like projections and saccular aneurysm,” which are associated with an increased risk of late aneurysm formation and rupture.<sup>297</sup> Other factors that predict adverse events are age greater than 70 years,<sup>297</sup> a maximum aortic diameter of 40 mm or greater, and a maximum aortic wall thickness of 10 mm or greater.<sup>298</sup> The natural history of PAUs remains poorly defined. Certainly those who present with symptoms of an acute aortic syndrome are likely to have increased risk of aortic rupture, whereas those without symptoms whose ulcers are discovered incidentally are more likely to have a chronic or slowly growing ulcer. Those with uncomplicated ulcers are often treated medically with antihypertensive medications and close monitoring with serial imaging studies, similar to the management of a patient with a distal AoD.<sup>789</sup>

## 15. Nursing Care and Patient/Family Education

### 15.1. Nursing Care of Medically Managed Patients

Nursing care for patients with thoracic aortic disease requires education to ensure that both patient and family understand the disease process, the importance of therapy including control of hypertension and other risk factors,<sup>790,791</sup> and the need for continued follow-up, including surveillance imaging. Because some aortic diseases are hereditary, follow-up might also include family member screening and counseling.<sup>792</sup> For patients with acute aortic syndromes, immediate control of hypertension and pain, as well as repeated assessments of symptoms and hemodynamic status, are key elements.<sup>345</sup>

Patients transported from smaller hospitals to larger ones are often alone, without the immediate support of their families, and will be dependent on nursing personnel for

**Table 18. Topics of Discussion for Preoperative Instruction and Informed Consent**

---

Clarification of the intervention or surgical procedure
Length of the intervention or surgical procedure
Potential complications
Endovascular leak
Stroke
Paralysis
Respiratory dysfunction/failure
Renal dysfunction/failure
Myocardial infarction (especially if known coronary disease)
Preoperative preparation for elective procedures
Smoking cessation
Antiplatelet or anticoagulation adjustment
Preoperative testing and instructions for obtaining tests
Chlorhexidine showers or other skin preparation
Intensive care stay and environment
What to expect: monitoring, staffing ratios, equipment
Length of stay
Visiting restrictions if any
Intravascular access
Central venous lines
Arterial lines
Ventilator support and weaning
Lumbar drains
Other lines and tubes
Pain management
Transitional care unit transfer
What to expect: monitoring, staffing ratios
Length of stay
Activity progression
Sternal and other activity/lifestyle precautions
Durable power of attorney for health care

---

emotional support and reassurance, as well as clinical and spiritual care. Family members need to have their questions answered honestly and in a way they can understand, to be notified of any changes in the patient's condition, and to have access to their loved one(s).<sup>793</sup>

### 15.2. Preprocedural Nursing Care

Nurses play a key role in answering questions that remain after initial explanations by physicians. Table 18 outlines topics that should be discussed as part of informed consent prior to an endovascular or open surgical procedure.

### 15.3. Postprocedural Nursing Care

Patients with a lower acuity level after thoracic aortic procedures, including endovascular repair, are often admitted to a postanesthesia care unit for initial recovery and then to an intensive care unit that can provide frequent monitoring of vital signs, peripheral pulses, urine output, and neurological status including lower extremity motor strength and sensation. Assessment of the skin in the extremities and lower torso

**Table 19. Lower Extremity Motor Function Assessment Scale**

0=No movement
1=Flicker of movement
2=Able to bend knee to move leg
3=Unable to perform straight leg raise against gravity, but better leg movement
4=Normal movement with expected later or demonstrated ambulation

Note: A score of  $\geq 3$  may be an indication for a neurological evaluation.  
Adapted from Svensson et al.<sup>781</sup>

is performed to look for cyanotic discoloration and skin temperature changes, which may be signs of embolization.<sup>794</sup> Embolization to cerebral vessels is another potential risk of these procedures, so frequent monitoring of mentation, level of consciousness, vision, speech, motor strength, and sensory function in the extremities is required. Thromboemboli to mesenteric, renal, and peripheral vascular beds may lead to complaints of abdominal pain or the presence of bloody diarrhea or vomiting. Flank pain with changes in urine output might indicate potential renal infarction from thromboemboli.

The initial postprocedural management focuses on blood pressure control. Hypertension can result in stent migration and bleeding from aortic suture lines. Hypotension can be equally problematic with the potential to impair renal function and spinal cord perfusion pressure. Hypotension presents a risk to spinal cord perfusion pressure and requires treatment with fluids or vasopressors. The risk of inadequate spinal cord perfusion is spinal cord ischemia, dysfunction, and potential paraplegia. Any decrease in lower extremity function must be reported to the physician team immediately as it could represent the onset of early and potentially reversible paralysis. A typical assessment consists of asking patients to demonstrate motor strength holding their extended, straight legs off the bed one at a time for at least 5 seconds,<sup>781</sup> with repeated assessments performed frequently for the first hours and days after an endovascular or open procedure. An objective scale that can be useful is outlined in Table 19. CSF drains are used for many patients undergoing endovascular and surgical procedures, and the nursing care is critically important (see Section 14.4).

Any new back or chest pain warrants further investigation to rule out the possibility of myocardial ischemia or infarction as well as a potential endoleak. New-onset pain of this nature requires notification of the physician team for further evaluation.

A phenomenon associated with stent graft placement is postimplantation syndrome, which can occur within 24 hours of placement of the graft. It is characterized by fever, leukocytosis, and occasionally thrombocytopenia. The symptoms, which usually resolve within 1 week, are managed with analgesics and anti-inflammatory agents.<sup>794</sup> Heparin-induced thrombocytopenia can be another source for thromboembolic events and may require treatment.

Routine assessment of the cannulation site used to deploy the graft is necessary. Large sheaths are used to deliver stents and can traumatize and occlude the femoral or iliac artery. The postoperative period presents an optimal opportunity to

assess and manage cardiovascular risk factors and to educate the patient and family on the benefits of risk-reduction measures. The AHA/ACC Guidelines for Secondary Prevention for Patients With Coronary and Other Atherosclerotic Vascular Disease<sup>409</sup> outlines guides to risk factor assessment, patient education, and possible interventions (see the online-only Data Supplement).

Patient and family preparation for discharge includes emphasis of the importance of medication compliance, incision care, and the need for follow-up. They must be made aware of the signs and symptoms of infection, such as redness, swelling, drainage, and fever. Unusual or severe pain, change in motor strength or sensation in the extremities, and sudden weakness or dizziness, which may be symptoms of new-onset bleeding or changes in spinal cord perfusion, should be promptly reported.

#### 15.4. Nursing Care of Surgically Managed Patients

Patients who have undergone open repair of aortic aneurysms or dissection will require more intensive care. A distinguishing feature will be whether the patient had an ascending aortic arch, or descending thoracic aortic repair. Patients who have had a dissection or an aneurysm of the ascending aorta or arch will have a median sternotomy incision. Patients undergoing aortic arch procedures may also have an incision over the axillary artery site. Cardiopulmonary bypass is required for these procedures and can be associated with fluid retention, electrolyte abnormalities, coagulopathies, and hypothermia. In addition, patients with aortic arch repairs are subjected to intervals of circulatory arrest and retrograde or selective cerebral perfusion. These adjuncts can result in neurologic dysfunction in the postoperative period.

Patients with Type B aortic dissections or descending thoracic aneurysms will have lateral thoracic or thoracoabdominal incisions. These incisions are often extensive.

These patients will often have lumbar drains that have been placed to monitor CSF pressure and CSF fluid drainage. The pressure used as a target for drainage varies but will generally be around 10 mm Hg. Pressures are checked hourly or more frequently in the early postoperative period. Care must be taken to prevent drainage that is too rapid or too excessive to prevent subdural hematoma formation.<sup>746</sup> Any change in level of consciousness or onset of irritability, confusion, headache, or pupillary reactivity requires immediate notification of the physician team and clamping of the drain. Neurologic monitoring also involves assessment of lower extremity motor and sensory function. Any deterioration may indicate inadequate spinal cord perfusion.

Standard postoperative care of these patients includes ventilator adjustments, optimization of blood volume, coagulation parameters, and monitoring of other organ system functions.<sup>795–799</sup> Following the transfer of patients from the intensive care unit, nursing care is focused on pain management, progression to independent ambulation, pulmonary physiotherapy and incentive spirometry, and wound care. Preparation for discharge is similar to that described for lower-activity patients earlier in this section.

## 16. Long-Term Issues

### 16.1. Recommendation for Employment and Lifestyle in Patients With Thoracic Aortic Disease Class IIa

- 1. For patients with a current thoracic aortic aneurysm or dissection, or previously repaired aortic dissection, employment and lifestyle restrictions are reasonable, including the avoidance of strenuous lifting, pushing, or straining that would require a Valsalva maneuver. (Level of Evidence: C)**

Establishing clear lifestyle goals for patients with thoracic aortic disease is important in improving long-term health and reducing the risk of complications. Because regular aerobic exercise, a low-fat and low-salt diet, and achieving an ideal body weight are tied to the ability to effectively control blood pressure, cholesterol, and associated aortic wall stress, providing patients with clear lifestyle targets is important. Avoidance of tobacco is critical because it is linked to the development of thoracic aortic disease and to aortic rupture. Not using cocaine or other stimulating drugs such as methamphetamine is important as sudden surges in blood pressure and pulse attributed to such agents have been described as a trigger for aortic catastrophes.<sup>800</sup>

The prescription of exercise represents a dilemma in the management of patients with thoracic aortic disease. Because it is thought that the sudden increases in  $dP/dt$  and systemic blood pressure associated with physical and mental stress may be a trigger for AoD in many patients, the concept of avoiding such stresses makes sense.<sup>801</sup> However, maintaining a regular routine of aerobic exercise has day-to-day benefits in helping patients achieve an ideal blood pressure, heart rate, and body weight. Moreover, many patients simply enjoy engaging in sports such as tennis, basketball, golf, bike riding, etc. and wish to continue in such activities if at all possible.

There are no outcomes data, and scant data of any variety for that matter, to indicate how much exercise is safe or beneficial for patients with thoracic aortic disease. However, aerobic exercise, sometimes referred to as dynamic exercise, is associated with only a modest increase in mean arterial pressure,<sup>802</sup> and AoD rarely occurs during aerobic exercise. Consequently, most experts believe that aerobic exercise, particularly when heart rate and blood pressure are well controlled with medications, is beneficial overall. Nevertheless, if patients wish to engage in vigorous aerobic exercise, such as running or basketball, one might consider performing a symptom-limited stress test to ensure that the patient does not have a hypertensive response to exercise.

Conversely, with isometric exercise, there is a significant increase in mean arterial pressure. When the Valsalva maneuver is used for the lifting of heavy weights, there is a superimposed increase in intrathoracic pressure, followed by a dramatic increase in systemic arterial pressure,<sup>802</sup> with systolic pressures reaching 300 mm Hg or greater.<sup>803</sup> As a result, most experts believe that heavy weight lifting or competitive athletics involving isometric exercise may trigger AoD and/or rupture and that such activities should be

avoided.<sup>804</sup> Working with patients on an individualized basis to streamline these goals based on insufficient data can be challenging. For patients who are very much interested in maintaining some sort of weight lifting program, choosing sets of repetitive light weights appears to make more sense than permitting heavy weight lifting.<sup>802</sup> For example, instead of bench-pressing 200 pounds, one might recommend selecting much lighter weights in repetitive sets to minimize the hemodynamic consequences. Patients often ask exactly how much weight is permissible to lift. Unfortunately, it is not possible to provide a blanket answer to that question, as it all depends on the patient's size, muscular strength, physical fitness, and how the weight is actually lifted. Rather than try to define a numerical limit, it may be useful to explain that patients can lift whatever weight they can comfortably lift without having to "bear down" or perform the Valsalva maneuver.

In addition to the physiologic stress of exercise, certain sports, recreational activities, or sudden stress or trauma to the thorax can potentially precipitate aortic rupture and/or dissection. Thoracic stress or trauma can occur during competitive football, ice hockey, or soccer or may result from a skiing accident, a fall while water skiing, etc. Therefore, experts often advise patients with thoracic aortic disease to avoid these types of sports.<sup>805</sup> Furthermore, rapid chest rotational movement while straining or breath holding (Valsalva maneuver) may be a common denominator in many patients who develop aortic dissection (ie, basketball, tennis, golf, baseball bat swing, chopping wood with an ax, shoveling snow, and rapidly lifting heavy objects).

In addition to the importance of setting clear lifestyle goals with patients with thoracic aortic disease, it is wise to emphasize the importance of adherence to their medications, especially to beta blockers and other antihypertensive agents. Patients who suddenly discontinue their medications because they fail to obtain a refill or perhaps forget their medications at home when traveling, may find themselves in a hypertensive crisis with a potentially catastrophic result.

Even patients who are compliant with their medications may find that their blood pressure may fluctuate between routine visits to their physician, resulting in months of excessive hypertension. Therefore, patients may achieve more consistent control of their hypertension if they regularly track their heart rate and blood pressure with a home monitoring system. In addition, by regularly tracking their weight and activity profile, they can provide their physician and other care members with accurate data with which to make adjustments in medication and lifestyle going forward.

In terms of work, patients with thoracic aortic disease generally can function normally in most types of occupations. The exception is any job involving heavy physical and manual labor accompanied by extreme isometric exercise (eg, lifting heavy boxes in a stockroom, carrying furniture up and down stairs). As with the heavy weight lifting described earlier, this type of unusual sudden stress on the aorta may predispose to a triggering of either aortic rupture or AoD.<sup>806</sup> Therefore, when patients have a vocation in which such extreme lifting might be required, it is important to discuss the details of their daily job responsibilities and to prescribe

avoidance of activities that might put them at risk. In some cases patients can readily avoid such heavy lifting on the job, but in many cases a letter from a physician explaining the restrictions may be required.

Finally, patients with thoracic aortic disease should recognize that aortic disease is usually a lifelong condition that puts them at future risk for acute aortic syndromes. Even those who have received advanced surgical or endovascular therapy must understand that their aortic disease has not been “cured” by the interventions. Educating them about what to do in the event of the sudden onset of chest, back, or abdominal pain or the sudden development of an ischemic complication (ie, neurological or limb) and the critical nature of getting to an emergency department promptly is of the utmost importance. Similarly, those who live with or care for such patients should understand what action needs to be taken should concerning symptoms arise.

## 17. Institutional/Hospital Quality Concerns

### 17.1. Recommendations for Quality Assessment and Improvement for Thoracic Aortic Disease

#### Class I

1. **Hospitals that provide regional care for patients with acute sequelae of thoracic aortic disease (eg, procedures for thoracic aortic dissection and rupture) should participate in standardized quality assessment and improvement activities, including thoracic aortic disease registries. Such activities should include periodic measurement and regional/national interfacility comparisons of thoracic aortic disease–related procedural volumes, complications, and risk-adjusted mortality rates. (Level of Evidence: C)**
2. **Hospitals that provide regional care for patients with acute sequelae of thoracic aortic disease (eg, procedures for thoracic aortic dissection and rupture) should facilitate and coordinate standardized quality assessment and improvement activities with transferring facilities and emergency medical services teams. Such activities might include:**
  - a. **Cooperative joint facility meetings to discuss opportunities for quality improvement and**
  - b. **Interfacility and emergency medical services team comparisons of pretransfer care based on available outcome data and future performance measures developed in accordance with this guideline. (Level of Evidence: C)**

Quality assessment of outcomes for thoracic aortic disease has been ongoing. Creation of one or more standardized thoracic aortic disease registries may significantly improve capacity for quality assessment and provide outcome results and meaningful performance benchmarks. IRAD is an example of such a registry and consists of 12 large referral centers in 6 countries and contains information on 290 variables, including demographics, history, physical findings, management, imaging studies, and outcomes.<sup>227</sup> Commitment to data collection, analysis, measurement, validation, and reporting

should be factored into the payment structures, as all of this will consume time, effort, and infrastructure to do it well.<sup>47</sup>

Moderate evidence supports “evidence-based referral”—that is, limiting specific procedures only to hospitals and physicians with experience, expertise, and capacity to take care of complex problems, especially those requiring specialized surgical skills and support teams. To date, there is no explicit evidence supporting such a recommendation for acute thoracic aortic diseases,<sup>807</sup> although this evidence exists for infrarenal aortic surgery.<sup>808–811</sup> Data courtesy of the UHC Clinical DataBase/Resource Manager for 2006q4 through 2007q3 indicates that for patients with:

- Ruptured thoracic aortic aneurysm:
  - 30% transferred from a different hospital
  - 34% were admitted from the emergency department
  - 19% referred from a clinic or physician’s office
  - 14% transferred from a skilled nursing facility or another nonhospital facility
  - 3% other
- Thoracic AoD:
  - 28% transferred from a different hospital
  - 35% were admitted from the emergency department
  - 23% referred from a clinic, physician’s office, or health maintenance organization
  - 9% transferred from a skilled nursing facility or another nonhospital facility
  - 5% other

Performance measures and quality metrics<sup>811a</sup> have been developed to evaluate quality of care for many areas of cardiac and vascular disease,<sup>5,812–814</sup> but none have yet been established for patients with thoracic aortic diseases. Possible domains of quality to assess could include procedural volumes (facility and operator), outcomes (eg, risk-adjusted mortality, readmission, or complications), time to diagnosis and intervention, and structural measures (eg, distance to nearest referral center, services available, and contingency planning).<sup>815</sup> The well-established evidence base for the regionalization of care for STEMI patients<sup>816</sup> may serve as a model for similar initiatives for patients with thoracic aortic disease (Table 20).

Claims have been made that some centers either do or will limit referrals of critically ill patients that may adversely impact hospital mortality rates, although there are no discrete data to confirm or disprove this behavior.<sup>817</sup> Hence, benchmarking and profiling efforts must recognize and account for the most physiologically precise severity-of-illness information and accurate and appropriate case-mix adjustments; otherwise, referral centers may have an incentive to refuse care for patients who could benefit from being transferred to their facility.<sup>818</sup>

Effective medical record systems are being developed and can enhance communication and provide caregivers with clear documentation of a patient’s course and medications, as well as plans for future.<sup>819,820</sup>

### 17.2. Interinstitutional Issues

Acute AoD or other acute problems involving any portion of the aorta are life-threatening conditions and require placing



**Table 20. Standardized Transferring Facility Assessment, Communication, and Documentation for the Following Domains**

- Blood pressure control for hypertension
- Heart rate control for tachycardia
- Hemodynamic instability
- Blood volume
- Cardiac ischemia
- Neurologic ischemia
- Renal function
- Mesenteric ischemia
- Peripheral arterial pulses and perfusion
- Activation of receiving team
- Imaging expectations and communications
- Timeliness and efficiency
- EMS characteristics of transferring facility, including requisite personnel, requisite in-transport equipment, including catastrophic resuscitation capabilities, in-transfer contingency planning, weather conditions, estimated transfer time, etc.

---

EMS indicates emergency medical services.

the patient in a location where all appropriate diagnostic and therapeutic measures are available. The minimum requirements for the care of patients with acute AoDs include imaging with CT, echocardiography, and angiography; the availability of cardiovascular surgery including cardiopulmonary bypass and endovascular interventions; an intensive care setting that allows continuous monitoring of blood pressure and intravenous management of blood pressure; and physicians with personal experience and expertise in the management of patients with acute AoD.<sup>820</sup>

Transfer of patients with acute AoD from one institution to another represents a period of danger to the patient and must be planned and carried out efficiently. It is incumbent on the transferring institution to provide prior physician-to-physician communication, to stabilize and maintain blood pressure control throughout transport, and to send copies of imaging studies.<sup>821</sup>

Because patients with acute thoracic aortic diseases present in any emergency department or primary care setting, there are opportunities for retrospective and comprehensive quality review. Typical areas of quality assessment could include the evaluation of timely detection in centers that typically are not equipped to manage such patients.

Retrospective evaluation of patients with thoracic aortic diseases, especially those for whom diagnosis was delayed or missed, is critical for learning about how best to more rapidly and effectively identify future patients with life-threatening thoracic aortic aneurysm and/or dissection. Independent external review of poor outcomes may be necessary and appropriately constructed using de-identified clinical records so that bias is not introduced into the evaluation process.

With the dissemination of this guideline, it is hoped that these practice standards can form the basis for more widespread use of a data registry for quality assessment and improvement for patients with thoracic aortic disease. The goals of such a data system would be to establish an extensive population of thoracic aortic disease patients with the intent

of evaluating clinical effectiveness. Domains could include volume and outcome relationships, process of care patterns, development of standardized performance measures (structure, process, and outcomes), and facility and operator feedback quality data systems. It may also be possible to use existing data that use relevant *ICD-9* codes (Table 2A and 2B) and appropriate risk-adjusted methods to evaluate mortality and complications.

## 18. Future Research Directions and Issues

The writing committee believes that there are many opportunities for additional meritorious research in thoracic aortic diseases. Emerging research appears promising for the following areas, in addition to much needed research in other areas.

### 18.1. Risks and Benefits of Current Imaging Technologies

There is a great need to balance the rapid identification of patients with acute AoD or rupture, and the relatively infrequent occurrence against the potential risks of radiation exposure and contrast toxicity incurred by current imaging methods, for the millions of patients who present with chest, back, and/or abdominal pain. The rapid and correct diagnosis of acute thoracic aortic diseases must not impose delays in treatment of patients with acute MI. Additionally, screening and serial radiographic imaging of younger patients clearly exposes those individuals to a risk of later radiation-related diseases. Clinical studies of safety and efficacy of screening protocols using current imaging methods to correctly identify patients who will benefit from surgical, endovascular, and/or medical intervention are needed.

### 18.2. Mechanisms of Aortic Dissection

The year 2010 is the 250th anniversary of the death, attributable to AoD, of King George II of England, whose last moments were memorably described by his valet.<sup>822</sup> Although a number of conditions are known to be associated with dissection, such as hypertension and old age, the cause of spontaneous AoD is still unknown. Is an intimal tear followed by a dissecting hematoma,<sup>823</sup> or does an intramural hemorrhage ruptures into the lumen causing an intimal tear?<sup>824,825</sup> In approximately 4% to 10% of dissections, an aortic intimal tear is not found. Bleeding from the vasa vasorum is hypothesized to be responsible for the intramural hemorrhage, but little is known about the microstructure of the vasa vasorum walls; changes in the vasa vasorum in response to aging, hypertension, and inflammation; and relation of extracellular and intracellular metalloproteinases to protein turnover in the walls of the vasa vasorum. Research into these questions may shed light on the pathogenesis of dissection and provide opportunities for prevention and treatment.

### 18.3. Treatment of Malperfusion and Reperfusion Injury

Malperfusion of the gut, spinal cord, kidneys, and lower extremities doubles the mortality of AoD.<sup>247,826</sup> New treatment strategies for malperfusion and reperfusion injury are needed to improve the dismal prognosis of patients with acute dissection and malperfusion syndromes.

## 18.4. Gene-Based Mechanisms and Models

### 18.4.1. Aortic Disease Management Based on the Underlying Genetic Defects

As genes are identified leading to an inherited predisposition for thoracic aortic disease, it is becoming increasingly evident that the clinical management of thoracic aortic disease associated with different gene mutations may differ. For example, mutations in *TGFBR1* and *TGFBR2* predispose patients to aortic dissection at an aortic diameter of 5.0 cm or less, leading to the recommendation that the aorta be replaced at diameters as small as 4.0 cm. As genes are identified that can cause predisposition to thoracic aortic disease, clinical studies are needed on these patients to determine their optimal management.

### 18.4.2. Biomarkers for Acute Aortic Dissection

A quick laboratory test with at least a high sensitivity, if not specificity, could lead to fewer missed or delayed diagnoses of acute AoD. None currently exists. D-dimer has been proposed as a screening test for acute AoD (see Section 8.6.1.2). A prospective study regarding the safety and efficacy of such a strategy is needed.

### 18.4.3. Genetic Defects and Molecular Pathway Analyses

Recent studies in the mouse model of Marfan syndrome and the identification of *TGFBR1* and *TGFBR2* mutations suggests that alteration of *TGF-Beta* signaling is involved. The identification of mutations in 2 components of the contractile unit in smooth muscle cells, beta-myosin heavy chain and alpha actin, has indicated a role of maintenance of smooth muscle cell contractile function in preserving aortic structure and preventing these aortic diseases. Further studies identifying defective genes and analyzing pathways using human tissues or mouse models will be the basis for understanding the molecular pathology and will be the first step toward development of rational medical therapies for thoracic aortic disease.

### 18.4.4. Clinical Trials for Medical Therapy for Aortic Aneurysms

Recent studies in the mouse model of Marfan syndrome with aortic disease similar to that seen in humans showed the treatment with losartan normalized aortic root growth and aortic wall architecture.<sup>6</sup> Doxycycline, an inhibitor of MMP, significantly delayed aneurysm rupture in this mouse model. A clinical trial is ongoing in patients with Marfan syndrome under the age of 25 years to determine if losartan delays aortic progression. More aggressive trials (other agents, 2 or 3 agent therapies) based on the results in mouse models to prevent the onset of aortic disease in individuals genetically predisposed or to delay the enlargement of already formed aneurysms are needed.

## 18.5. Aortic Atheroma and Atherosclerosis Identification and Treatment

As noted in Section 11, there is a need for research into the mechanistic aspects of aortic arch atheroma in causing embolic events. Additionally, for those patients with known aortic arch atheroma, a randomized blinded controlled trial is needed to test currently available treatment options, both medical and surgical, to prevent embolic vascular events.

The value of current imaging (MR, CT, TEE) technologies to identify and quantitate risk for patients with aortic arch atheroma is unknown.

## 18.6. Prediction Models of Aortic Rupture and the Need for Preemptive Interventions

We need to have models or indices that are better than just aortic diameter to predict rupture and to better determine the best timing for surgical or endovascular intervention. Since the advent of CT and MR scanning, a massive amount of radiological data has accumulated with multiple studies in individual patients that could be linked to clinical data and used for this purpose. The evidence base regarding the clinical course of patients with Marfan syndrome is more robust than for patients with degenerative aneurysms and other thoracic aortic conditions. An ongoing registry similar to that used for patients with Marfan syndrome would be a place to start.

## 18.7. National Heart, Lung, and Blood Institute Working Group Recommendations

The National Heart, Lung, and Blood Institute Working Group on Research in Marfan Syndrome and Related Disorders<sup>827</sup> posted a summary of recommendations for future research which apply to the broad range of patients with thoracic aortic disease. The importance of multidisciplinary teams and collaborative research models were stressed:

- Existing registries should be expanded or new registries developed to define the presentation, natural history, and clinical history of aneurysm syndromes.
- Biological and aortic tissue sample collection should be incorporated into every clinical research program on Marfan syndrome and related disorders and funds should be provided to ensure that this occurs. Such resources, once established, should be widely shared among investigators.
- An Aortic Aneurysm Clinical Trials Network should be developed to test both surgical and medical therapies in patients with thoracic aortic aneurysms. Partnership in this effort should be sought with industry, academic organizations, foundations, and other governmental entities.
- The identification of novel therapeutic targets and biomarkers should be facilitated by the development of genetically defined animal models and the expanded use of genomic, proteomic and functional analyses. There is a specific need to understand cellular pathways that are altered leading to aneurysms and dissections, and to develop robust in vivo reporter assays to monitor TGF-Beta and other cellular signaling cascades.
- The developmental underpinnings of apparently acquired phenotypes should be explored. This effort will be facilitated by the dedicated analysis of both prenatal and early postnatal tissues in genetically defined animal models and through the expanded availability to researchers of surgical specimens from affected children and young adults.

The writing committee enthusiastically endorses these concepts.

**Staff****American College of Cardiology Foundation**

John C. Lewin, MD, Chief Executive Officer  
 Charlene May, Senior Director, Science and Clinical Policy  
 Lisa Bradfield, CAE, Associate Director, Science and Clinical Policy  
 Mark D. Stewart, MPH, Associate Director, Evidence-Based Medicine  
 Sue Keller, BSN, MPH, Senior Specialist, Evidence-Based Medicine  
 Erin A. Barrett, Senior Specialist, Science and Clinical Policy  
 Jesse M. Welsh, Specialist, Science and Clinical Policy

**American Heart Association**

Nancy Brown, Chief Executive Officer  
 Gayle R. Whitman, PhD, RN, FAHA, FAAN, Senior Vice President, Office of Science Operations

**References**

1. ACCF/AHA Task Force on Practice Guidelines. Manual for ACCF/AHA Guideline Writing Committees: Methodologies and Policies from the ACCF/AHA Task Force on Practice Guidelines. Available at: <http://www.acc.org/qualityandscience/clinical/manual/pdfs/methodology.pdf> and <http://circ.ahajournals.org/manual/>. Accessed January 7, 2010.
2. Svensson LG, Rodriguez ER. Aortic organ disease epidemic, and why do balloons pop? *Circulation*. 2005;112:1082-4.
3. Svensson LG, Crawford ES. Cardiovascular and Vascular Disease of the Aorta. Philadelphia, PA: WB Saunders Co; 1997.
4. Hirsch AT, Haskal ZJ, Hertzler NR, et al. ACC/AHA 2005 Practice Guidelines for the management of patients with peripheral arterial disease (lower extremity, renal, mesenteric, and abdominal aortic). *Circulation*. 2006;113:e463-e654.
5. Bonow RO, Carabello BA, Kanu C, et al. ACC/AHA 2006 guidelines for the management of patients with valvular heart disease. *Circulation*. 2006;114:e84-231.
6. Habashi JP, Judge DP, Holm TM, et al. Losartan, an AT1 antagonist, prevents aortic aneurysm in a mouse model of Marfan syndrome. *Science*. 2006;312:117-21.
7. Pannu H, Tran-Fadulu V, Papke CL, et al. MYH11 mutations result in a distinct vascular pathology driven by insulin-like growth factor I and angiotensin II. *Hum Mol Genet*. 2007;16:2453-62.
8. Kumar SR. Pathologic Basis of Disease. Philadelphia, PA: Elsevier Saunders. 2005.
9. Collins JS, Evangelista A, Nienaber CA, et al. Differences in clinical presentation, management, and outcomes of acute type A aortic dissection in patients with and without previous cardiac surgery. *Circulation*. 2004;110:II237-II242.
10. Razzouk A, Gundry S, Wang N, et al. Pseudoaneurysms of the aorta after cardiac surgery or chest trauma. *Am Surg*. 1993;59:818-23.
11. Milewicz DM, Guo DC, Tran-Fadulu V, et al. Genetic basis of thoracic aortic aneurysms and dissections: focus on smooth muscle cell contractile dysfunction. *Annu Rev Genomics Hum Genet*. 2008;9:283-302.
12. Johnston KW, Rutherford RB, Tilson MD, et al. Suggested standards for reporting on arterial aneurysms. Subcommittee on Reporting Standards for Arterial Aneurysms, Ad Hoc Committee on Reporting Standards, Society for Vascular Surgery and North American Chapter, International Society for Cardiovascular Surgery. *J Vasc Surg*. 1991;13:452-8.
13. Hannuksela M, Lundqvist S, Carlberg B. Thoracic aorta: dilated or not? *Scand Cardiovasc J*. 2006;40:175-8.
14. Hager A, Kaemmerer H, Rapp-Bernhardt U, et al. Diameters of the thoracic aorta throughout life as measured with helical computed tomography. *J Thorac Cardiovasc Surg*. 2002;123:1060-6.
15. Roman MJ, Devereux RB, Kramer-Fox R, et al. Two-dimensional echocardiographic aortic root dimensions in normal children and adults. *Am J Cardiol*. 1989;64:507-12.
16. Svensson LG, Khitin L. Aortic cross-sectional area/height ratio timing of aortic surgery in asymptomatic patients with Marfan syndrome. *J Thorac Cardiovasc Surg*. 2002;123:360-1.
17. Stry HC, Chandler AB, Dinsmore RE, et al. A definition of advanced types of atherosclerotic lesions and a histological classification of atherosclerosis. A report from the Committee on Vascular Lesions of the Council on Arteriosclerosis, American Heart Association. *Circulation*. 1995;92:1355-74.
18. He R, Guo DC, Estrera AL, et al. Characterization of the inflammatory and apoptotic cells in the aortas of patients with ascending thoracic aortic aneurysms and dissections. *J Thorac Cardiovasc Surg*. 2006;131:671-8.
19. Tang PC, Coady MA, Lovoulos C, et al. Hyperplastic cellular remodeling of the media in ascending thoracic aortic aneurysms. *Circulation*. 2005;112:1098-105.
20. Segura AM, Luna RE, Horiba K, et al. Immunohistochemistry of matrix metalloproteinases and their inhibitors in thoracic aortic aneurysms and aortic valves of patients with Marfan's syndrome. *Circulation*. 1998;98:II331-II337.
21. Fedak PW, de Sa MP, Verma S, et al. Vascular matrix remodeling in patients with bicuspid aortic valve malformations: implications for aortic dilatation. *J Thorac Cardiovasc Surg*. 2003;126:797-806.
22. Lemaire SA, Wang X, Wilks JA, et al. Matrix metalloproteinases in ascending aortic aneurysms: bicuspid versus trileaflet aortic valves. *J Surg Res*. 2005;123:40-8.
23. Lemaire SA, Pannu H, Tran-Fadulu V, et al. Severe aortic and arterial aneurysms associated with a TGFBR2 mutation. *Nat Clin Pract Cardiovasc Med*. 2007;4:167-71.
24. Ikonomidis JS, Jones JA, Barbour JR, et al. Expression of matrix metalloproteinases and endogenous inhibitors within ascending aortic aneurysms of patients with bicuspid or tricuspid aortic valves. *J Thorac Cardiovasc Surg*. 2007;133:1028-36.
25. Dong C, Wu QY, Tang Y. Ruptured sinus of valsalva aneurysm: a Beijing experience. *Ann Thorac Surg*. 2002;74:1621-4.
26. Pannu H, Fadulu VT, Chang J, et al. Mutations in transforming growth factor-beta receptor type II cause familial thoracic aortic aneurysms and dissections. *Circulation*. 2005;112:513-20.
27. Guo D, Pannu H, Tran-Fadulu V, et al. Mutations in smooth muscle alpha-actin (ACTA2). *Nat Genet*. 2007;39:1488-93.
28. Weyand CM, Goronzy JJ. Medium- and large-vessel vasculitis. *N Engl J Med*. 2003;349:160-9.
29. Salvarani C, Gabriel SE, O'Fallon WM, et al. The incidence of giant cell arteritis in Olmsted County, Minnesota: apparent fluctuations in a cyclic pattern. *Ann Intern Med*. 1995;123:192-4.
30. Amis ES Jr., Butler PF, Applegate KE, et al. American College of Radiology white paper on radiation dose in medicine. *J Am Coll Radiol*. 2007;4:272-84.
31. Brenner DJ, Hall EJ. Computed tomography: an increasing source of radiation exposure. *N Engl J Med*. 2007;357:2277-84.
32. Shellock FG, Spinazzi A. MRI safety update 2008: part 1, MRI contrast agents and nephrogenic systemic fibrosis. *AJR Am J Roentgenol*. 2008;191:1129-39.
33. Cascade PN, Leibel SA. Decision-making in radiotherapy for the cancer patient: the American College of Radiology Appropriateness Criteria Project. *CA Cancer J Clin*. 1998;48:146-50.
34. International Commission on Radiological Protection (ICRP). Recommendations of the International Commission on Radiological Protection. *Ann ICRP*. 1977;1:1-53.
35. McCollough CH, Bruesewitz MR, Kofler JM Jr. CT dose reduction and dose management tools: overview of available options. *Radiographics*. 2006;26:503-12.
36. Parker MS, Matheson TL, Rao AV, et al. Making the transition: the role of helical CT in the evaluation of potentially acute thoracic aortic injuries. *AJR Am J Roentgenol*. 2001;176:1267-72.
37. Klompas M. Does this patient have an acute thoracic aortic dissection? *JAMA*. 2002;287:2262-72.
38. von Kodolitsch Y, Nienaber CA, Dieckmann C, et al. Chest radiography for the diagnosis of acute aortic syndrome. *Am J Med*. 2004;116:73-7.
39. Woodring JH, King JG. The potential effects of radiographic criteria to exclude aortography in patients with blunt chest trauma. Results of a study of 32 patients with proved aortic or brachiocephalic arterial injury. *J Thorac Cardiovasc Surg*. 1989;97:456-60.
40. Mirvis SE, Bidwell JK, Buddemeyer EU, et al. Value of chest radiography in excluding traumatic aortic rupture. *Radiology*. 1987;163:487-93.
41. Schwab CW, Lawson RB, Lind JF, et al. Aortic injury: comparison of supine and upright portable chest films to evaluate the widened mediastinum. *Ann Emerg Med*. 1984;13:896-9.
42. Erbel R, Engberding R, Daniel W, et al. Echocardiography in diagnosis of aortic dissection. *Lancet*. 1989;1:457-61.

43. Yoshida S, Akiba H, Tamakawa M, et al. Thoracic involvement of type A aortic dissection and intramural hematoma: diagnostic accuracy: comparison of emergency helical CT and surgical findings. *Radiology*. 2003;228:430–5.
44. Sommer T, Fehske W, Holzknicht N, et al. Aortic dissection: a comparative study of diagnosis with spiral CT, multiplanar transesophageal echocardiography, and MR imaging. *Radiology*. 1996;199:347–52.
45. Zeman RK, Berman PM, Silverman PM, et al. Diagnosis of aortic dissection: value of helical CT with multiplanar reformation and three-dimensional rendering. *AJR Am J Roentgenol*. 1995;164:1375–80.
46. Shiga T, Wajima Z, Apfel CC, et al. Diagnostic accuracy of transesophageal echocardiography, helical computed tomography, and magnetic resonance imaging for suspected thoracic aortic dissection: systematic review and meta-analysis. *Arch Intern Med*. 2006;166:1350–6.
47. Hagan PG, Nienaber CA, Isselbacher EM, et al. The International Registry of Acute Aortic Dissection (IRAD): new insights into an old disease. *JAMA*. 2000;283:897–903.
48. Mirvis SE, Shanmuganathan K, Buell J, et al. Use of spiral computed tomography for the assessment of blunt trauma patients with potential aortic injury. *J Trauma*. 1998;45:922–30.
49. Wicky S, Wintermark M, Schnyder P, et al. Imaging of blunt chest trauma. *Eur Radiol*. 2000;10:1524–38.
50. Gavant ML. Helical CT. grading of traumatic aortic injuries. Impact on clinical guidelines for medical and surgical management. *Radiol Clin North Am*. 1999;37:553–74, vi.
51. Mirvis SE, Shanmuganathan K, Miller BH, et al. Traumatic aortic injury: diagnosis with contrast-enhanced thoracic CT: five-year experience at a major trauma center. *Radiology*. 1996;200:413–22.
52. Scaglione M, Pinto A, Pinto F, et al. Role of contrast-enhanced helical CT in the evaluation of acute thoracic aortic injuries after blunt chest trauma. *Eur Radiol*. 2001;11:2444–8.
53. Ellis JD, Mayo JR. Computed tomography evaluation of traumatic rupture of the thoracic aorta: an outcome study. *Can Assoc Radiol J*. 2007;58:22–6.
54. Quint LE, Francis IR, Williams DM, et al. Evaluation of thoracic aortic disease with the use of helical CT and multiplanar reconstructions: comparison with surgical findings. *Radiology*. 1996;201:37–41.
55. ACR Accreditation Program Clinical Image and Quality Guide 2008. Available at: [http://www.acr.org/accreditation/computed/qc\\_forms/image\\_guide.aspx](http://www.acr.org/accreditation/computed/qc_forms/image_guide.aspx). Accessed January 7, 2010.
56. American College of Radiology. ACR CT Accreditation Clinical Image Quality Guide. Available at: [http://www.acr.org/accreditation/computed/qc\\_forms/image\\_guide.aspx](http://www.acr.org/accreditation/computed/qc_forms/image_guide.aspx). Accessed January 7, 2010.
57. Practice Guideline for the Performance and Interpretation of Computed Tomography Angiography. Available at: [http://www.acr.org/SecondaryMainMenuCategories/quality\\_safety/guidelines/dx/cardio/ct\\_angiography.aspx](http://www.acr.org/SecondaryMainMenuCategories/quality_safety/guidelines/dx/cardio/ct_angiography.aspx). Accessed January 7, 2010.
58. Francois CJ, Carr JC. MRI of the thoracic aorta. *Cardiol Clin*. 2007;25:171–84, vii.
59. Kapustin AJ, Litt HI. Diagnostic imaging for aortic dissection. *Semin Thorac Cardiovasc Surg*. 2005;17:214–23.
60. Cigarroa JE, Isselbacher EM, DeSanctis RW, et al. Diagnostic imaging in the evaluation of suspected aortic dissection. Old standards and new directions. *N Engl J Med*. 1993;328:35–43.
61. Tsai TT, Nienaber CA, Eagle KA. Acute aortic syndromes. *Circulation*. 2005;112:3802–13.
62. Miller JS, Lemaire SA, Coselli JS. Evaluating aortic dissection: when is coronary angiography indicated? *Heart*. 2000;83:615–6.
63. Moore AG, Eagle KA, Bruckman D, et al. Choice of computed tomography, transesophageal echocardiography, magnetic resonance imaging, and aortography in acute aortic dissection: International Registry of Acute Aortic Dissection (IRAD). *Am J Cardiol*. 2002;89:1235–8.
64. Bansal RC, Chandrasekaran K, Ayala K, et al. Frequency and explanation of false negative diagnosis of aortic dissection by aortography and transesophageal echocardiography. *J Am Coll Cardiol*. 1995;25:1393–401.
65. Shugord WH. Problems in the aortographic diagnosis of dissecting aneurysms of the aorta. *N Engl J Med*. 1969;280:225–31.
66. Macura KJ, Szarf G, Fishman EK, et al. Role of computed tomography and magnetic resonance imaging in assessment of acute aortic syndromes. *Semin Ultrasound CT MR*. 2003;24:232–54.
67. Nienaber CA, von Kodolitsch Y, Nicolas V, et al. The diagnosis of thoracic aortic dissection by noninvasive imaging procedures. *N Engl J Med*. 1993;328:1–9.
68. Beebe HG, Kritpracha B, Serres S, et al. Endograft planning without preoperative arteriography: a clinical feasibility study. *J Endovasc Ther*. 2000;7:8–15.
69. Katz ES, Konecky N, Tunick PA, et al. Visualization and identification of the left common carotid and left subclavian arteries: a transesophageal echocardiographic approach. *J Am Soc Echocardiogr*. 1996;9:58–61.
70. Min JK, Spencer KT, Furlong KT, et al. Clinical features of complications from transesophageal echocardiography: a single-center case series of 10,000 consecutive examinations. *J Am Soc Echocardiogr*. 2005;18:925–9.
71. Lee DY, Williams DM, Abrams GD. The dissected aorta: part II. Differentiation of the true from the false lumen with intravascular US. *Radiology*. 1997;203:32–6.
72. LePage MA, Quint LE, Sonnad SS, et al. Aortic dissection: CT features that distinguish true lumen from false lumen. *AJR Am J Roentgenol*. 2001;177:207–11.
73. Borner N, Erbel R, Braun B, et al. Diagnosis of aortic dissection by transesophageal echocardiography. *Am J Cardiol*. 1984;54:1157–8.
74. Pearson GD, Devereux R, Loeys B, et al. Report of the National Heart, Lung, and Blood Institute and National Marfan Foundation Working Group on research in Marfan syndrome and related disorders. *Circulation*. 2008;118:785–91.
75. Svensson LG, Crawford ES, Coselli JS, et al. Impact of cardiovascular operation on survival in the Marfan patient. *Circulation*. 1989;80:1233–1242.
76. Svensson LG, Blackstone EH, Feng J, et al. Are Marfan syndrome and marfanoid patients distinguishable on long-term follow-up? *Ann Thorac Surg*. 2007;83:1067–74.
77. Zhu L, Vranckx R, Khau Van Kien P, et al. Mutations in myosin heavy chain 11 cause a syndrome associating thoracic aortic aneurysm/aortic dissection and patent ductus arteriosus. *Nat Genet*. 2006;38:343–9.
78. Loeys BL, Schwarze U, Holm T, et al. Aneurysm syndromes caused by mutations in the TGF-beta receptor. *N Engl J Med*. 2006;355:788–98.
79. Williams JA, Loeys BL, Nwakanma LU, et al. Early surgical experience with Loeys-Dietz: a new syndrome of aggressive thoracic aortic aneurysm disease. *Ann Thorac Surg*. 2007;83:S757–S763.
80. Bondy CA. Care of girls and women with Turner syndrome: A guideline of the Turner Syndrome Study Group. *J Clin Endocrinol Metab*. 2007;92:10–25.
81. Gott VL, Greene PS, Alejo DE, et al. Replacement of the aortic root in patients with Marfan's syndrome. *N Engl J Med*. 1999;340:1307–13.
82. Dietz HC, Pyeritz RE. Mutations in the human gene for fibrillin-1 (FBN1) in the Marfan syndrome and related disorders. *Hum Mol Genet*. 1995;4 Spec No:1799–809.
83. Mizuguchi T, Collod-Beroud G, Akiyama T, et al. Heterozygous TGFBR2 mutations in Marfan syndrome. *Nat Genet*. 2004;36:855–60.
84. De Paepe A, Devereux RB, Dietz HC, et al. Revised diagnostic criteria for the Marfan syndrome. *Am J Med Genet*. 1996;62:417–26.
85. van Karnebeek CD, Naef MS, Mulder BJ, et al. Natural history of cardiovascular manifestations in Marfan syndrome. *Arch Dis Child*. 2001;84:129–37.
86. Roman MJ, Rosen SE, Kramer-Fox R, et al. Prognostic significance of the pattern of aortic root dilation in the Marfan syndrome. *J Am Coll Cardiol*. 1993;22:1470–6.
87. Umana JP, Miller DC, Mitchell RS. What is the best treatment for patients with acute type B aortic dissections: medical, surgical, or endovascular stent-grafting? *Ann Thorac Surg*. 2002;74:S1840–S1843.
88. Shores J, Berger KR, Murphy EA, et al. Progression of aortic dilatation and the benefit of long-term beta-adrenergic blockade in Marfan's syndrome. *N Engl J Med*. 1994;330:1335–41.
89. Brooke BS, Habashi JP, Judge DP, et al. Angiotensin II blockade and aortic-root dilation in Marfan's syndrome. *N Engl J Med*. 2008;358:2787–95.
90. Lacro RV, Dietz HC, Wruck LM, et al. Rationale and design of a randomized clinical trial of beta-blocker therapy (atenolol) versus angiotensin II receptor blocker therapy (losartan) in individuals with Marfan syndrome. *Am Heart J*. 2007;154:624–31.
91. Milewicz DM, Dietz HC, Miller DC. Treatment of aortic disease in patients with Marfan syndrome. *Circulation*. 2005;111:e150–e157.
92. Silverman DI, Burton KJ, Gray J, et al. Life expectancy in the Marfan syndrome. *Am J Cardiol*. 1995;75:157–60.

93. Finkbohner R, Johnston D, Crawford ES, et al. Marfan syndrome. Long-term survival and complications after aortic aneurysm repair. *Circulation*. 1995;91:728–33.
94. Svensson LG. Sizing for modified David's reimplantation procedure. *Ann Thorac Surg*. 2003;76:1751–3.
95. David TE, Feindel CM, Webb GD, et al. Aortic valve preservation in patients with aortic root aneurysm: results of the reimplantation technique. *Ann Thorac Surg*. 2007;83:S732–S735.
96. Fazel SS, David TE. Aortic valve-sparing operations for aortic root and ascending aortic aneurysms. *Curr Opin Cardiol*. 2007;22:497–503.
97. Kallenbach K, Baraki H, Khaladj N, et al. Aortic valve-sparing operation in Marfan syndrome: what do we know after a decade? *Ann Thorac Surg*. 2007;83:S764–S768.
98. Patel ND, Weiss ES, Alejo DE, et al. Aortic root operations for Marfan syndrome: a comparison of the Bentall and valve-sparing procedures. *Ann Thorac Surg*. 2008;85:2003–10.
99. Svensson LG, Deglurkar I, Ung J, et al. Aortic valve repair and root preservation by remodeling, reimplantation, and tailoring: technical aspects and early outcome. *J Card Surg*. 2007;22:473–9.
100. Burkhart HM, Zehr KJ, Schaff HV, et al. Valve-preserving aortic root reconstruction: a comparison of techniques. *J Heart Valve Dis*. 2003;12:62–7.
101. Zehr KJ, Matloobi A, Connolly HM, et al. Surgical management of the aortic root in patients with Marfan syndrome. *J Heart Valve Dis*. 2005;14:121–8.
102. Rossiter JP, Repke JT, Morales AJ, et al. A prospective longitudinal evaluation of pregnancy in the Marfan syndrome. *Am J Obstet Gynecol*. 1995;173:1599–606.
103. Sakaguchi M, Kitahara H, Watanabe T, et al. Successful surgical treatment for acute aortic dissection in pregnancy with Marfan's syndrome. *Jpn J Thorac Cardiovasc Surg*. 2005;53:220–2.
104. Singh KK, Rommel K, Mishra A, et al. TGFBR1 and TGFBR2 mutations in patients with features of Marfan syndrome and Loeys-Dietz syndrome. *Hum Mutat*. 2006;27:770–7.
105. Loeys BL, Chen J, Neptune ER, et al. A syndrome of altered cardiovascular, craniofacial, neurocognitive and skeletal development caused by mutations in TGFBR1 or TGFBR2. *Nat Genet*. 2005;37:275–81.
106. Pepin M, Schwarze U, Superti-Furga A, et al. Clinical and genetic features of Ehlers-Danlos syndrome type IV, the vascular type. *N Engl J Med*. 2000;342:673–80.
107. Ascione R, Gomes VJ, Bates M, et al. Emergency repair of type A aortic dissection in type IV Ehlers-Danlos syndrome. *Cardiovasc Surg*. 2000;8:75–8.
108. Sybert VP. Cardiovascular malformations and complications in Turner syndrome. *Pediatrics*. 1998;101:E11.
109. Gotzsche CO, Krag-Olsen B, Nielsen J, et al. Prevalence of cardiovascular malformations and association with karyotypes in Turner's syndrome. *Arch Dis Child*. 1994;71:433–6.
110. Ostberg JE, Brookes JA, McCarthy C, et al. A comparison of echocardiography and magnetic resonance imaging in cardiovascular screening of adults with Turner syndrome. *J Clin Endocrinol Metab*. 2004;89:5966–71.
111. Lin AE, Silberbach M. Focus on the heart and aorta in Turner syndrome. *J Pediatr*. 2007;150:572–4.
112. Gravholt CH, Landin-Wilhelmsen K, Stochholm K, et al. Clinical and epidemiological description of aortic dissection in Turner's syndrome. *Cardiol Young*. 2006;16:430–6.
113. Bondy CA, Van PL, Bakalov VK, et al. Growth hormone treatment and aortic dimensions in Turner syndrome. *J Clin Endocrinol Metab*. 2006;91:1785–8.
114. Boissonnas CC, Davy C, Bornes M, et al. Careful cardiovascular screening and follow-up of women with Turner syndrome before and during pregnancy is necessary to prevent maternal mortality. *Fertil Steril*. 2009;91:929.e5–7.
115. Matura LA, Sachdev V, Bakalov VK, et al. Growth hormone treatment and left ventricular dimensions in Turner syndrome. *J Pediatr*. 2007;150:587–91.
116. Sas TC, Cromme-Dijkhuis AH, de Muinck Keizer-Schrama SM, et al. The effects of long-term growth hormone treatment on cardiac left ventricular dimensions and blood pressure in girls with Turner's syndrome. Dutch Working Group on Growth Hormone *J Pediatr*. 1999;135:470–6.
117. Wenstrup RJ, Meyer RA, Lyle JS, et al. Prevalence of aortic root dilation in the Ehlers-Danlos syndrome. *Genet Med*. 2002;4:112–7.
118. Gupta PA, Putnam EA, Carmical SG, et al. Ten novel FBN2 mutations in congenital contractural arachnodactyly: delineation of the molecular pathogenesis and clinical phenotype. *Hum Mutat*. 2002;19:39–48.
119. Gupta PA, Wallis DD, Chin TO, et al. FBN2 mutation associated with manifestations of Marfan syndrome and congenital contractural arachnodactyly. *J Med Genet*. 2004;41:e56.
120. Adeola T, Adeleye O, Potts JL, et al. Thoracic aortic dissection in a patient with autosomal dominant polycystic kidney disease. *J Natl Med Assoc*. 2001;93:282–7.
121. Lee CC, Chang WT, Fang CC, et al. Sudden death caused by dissecting thoracic aortic aneurysm in a patient with autosomal dominant polycystic kidney disease. *Resuscitation*. 2004;63:93–6.
122. Purnell R, Williams I, Von Oppell U, et al. Giant aneurysms of the sinuses of Valsalva and aortic regurgitation in a patient with Noonan's syndrome. *Eur J Cardiothorac Surg*. 2005;28:346–8.
123. Morgan JM, Coupe MO, Honey M, et al. Aneurysms of the sinuses of Valsalva in Noonan's syndrome. *Eur Heart J*. 1989;10:190–3.
124. Shachter N, Perloff JK, Mulder DG. Aortic dissection in Noonan's syndrome (46 XY turner). *Am J Cardiol*. 1984;54:464–5.
125. McElhinney DB, Krantz ID, Bason L, et al. Analysis of cardiovascular phenotype and genotype-phenotype correlation in individuals with a JAG1 mutation and/or Alagille syndrome. *Circulation*. 2002;106:2567–74.
126. Albornoz G, Coady MA, Roberts M, et al. Familial thoracic aortic aneurysms and dissections: incidence, modes of inheritance, and phenotypic patterns. *Ann Thorac Surg*. 2006;82:1400–5.
127. Coady MA, Davies RR, Roberts M, et al. Familial patterns of thoracic aortic aneurysms. *Arch Surg*. 1999;134:361–7.
128. Steneur C, Colod-Beroud G, Faivre L, et al. Identification of 23 TGFBR2 and 6 TGFBR1 gene mutations and genotype-phenotype investigations in 457 patients with Marfan syndrome type I and II, Loeys-Dietz syndrome and related disorders *Hum Mutat*. 2008;29:E284–E295.
129. Guo DC, Papke CL, Tran-Fadulu V, et al. Mutations in smooth muscle alpha-actin (ACTA2) cause coronary artery disease, stroke, and moyamoya disease, along with thoracic aortic disease. *Am J Hum Genet*. 2009;84:617–27.
130. Biddinger A, Rocklin M, Coselli J, et al. Familial thoracic aortic dilations and dissections: a case control study. *J Vasc Surg*. 1997;25:506–11.
131. Milewicz DM, Chen H, Park ES, et al. Reduced penetrance and variable expressivity of familial thoracic aortic aneurysms/dissections. *Am J Cardiol*. 1998;82:474–9.
132. Guo D, Hasham S, Kuang SQ, et al. Familial thoracic aortic aneurysms and dissections: genetic heterogeneity with a major locus mapping to 5q13-14. *Circulation*. 2001;103:2461–8.
133. Hasham SN, Willing MC, Guo DC, et al. Mapping a locus for familial thoracic aortic aneurysms and dissections (TAAD2) to 3p24–25. *Circulation*. 2003;107:3184–90.
134. Vaughan CJ, Casey M, He J, et al. Identification of a chromosome 11q23.2-q24 locus for familial aortic aneurysm disease, a genetically heterogeneous disorder. *Circulation*. 2001;103:2469–75.
135. Khau Van Kien P, Mathieu F, Zhu L, et al. Mapping of familial thoracic aortic aneurysm/dissection with patent ductus arteriosus to 16p12.2-p13.13. *Circulation*. 2005;112:200–6.
136. Fatigati V, Murphy R. Actin and tropomyosin Variants. *J Bio Chem*. 1984;259:14383–8.
137. Braverman AC, Guven H, Beardslee MA, et al. The bicuspid aortic valve. *Curr Probl Cardiol*. 2005;30:470–522.
138. Borger MA, David TE. Management of the valve and ascending aorta in adults with bicuspid aortic valve disease. *Semin Thorac Cardiovasc Surg*. 2005;17:143–7.
139. Svensson LG, Blackstone EH, Cosgrove DM, III. Surgical options in young adults with aortic valve disease. *Curr Probl Cardiol*. 2003;28:417–80.
140. Svensson LG. Aortic valve stenosis and regurgitation: an overview of management. *J Cardiovasc Surg (Torino)*. 2008;49:297–303.
141. Huntington K, Hunter AG, Chan KL. A prospective study to assess the frequency of familial clustering of congenital bicuspid aortic valve. *J Am Coll Cardiol*. 1997;30:1809–12.
142. Loscalzo ML, Goh DL, Loeys B, et al. Familial thoracic aortic dilation and bicommissural aortic valve: a prospective analysis of natural history and inheritance. *Am J Med Genet A*. 2007;143A:1960–7.

143. Svensson LG, Kim KH, Lytle BW, et al. Relationship of aortic cross-sectional area to height ratio and the risk of aortic dissection in patients with bicuspid aortic valves. *J Thorac Cardiovasc Surg.* 2003;126:892–3.
144. Larson EW, Edwards WD. Risk factors for aortic dissection: a necropsy study of 161 cases. *Am J Cardiol.* 1984;53:849–55.
145. Roberts WC, Ko JM. Frequency by decades of unicuspid, bicuspid, and tricuspid aortic valves in adults having isolated aortic valve replacement for aortic stenosis, with or without associated aortic regurgitation. *Circulation.* 2005;111:920–5.
146. Bayford D. An account of a singular case of obstructed deglutition. *Memoirs Med Soc London.* 1794;2:275–86.
147. Svensson LG, Crawford ES. *Cardiovascular and Vascular Disease of the Aorta.* Philadelphia, PA: WB Saunders Co; 1997.
148. Austin EH, Wolfe WG. Aneurysm of aberrant subclavian artery with a review of the literature. *J Vasc Surg.* 1985;2:571–7.
149. Stone WM, Brewster DC, Moncure AC, et al. Aberrant right subclavian artery: varied presentations and management options. *J Vasc Surg.* 1990;11:812–7.
150. Branscom JJ, Austin JH. Aberrant right subclavian artery. Findings seen on plain chest roentgenograms. *Am J Roentgenol Radium Ther Nucl Med.* 1973;119:539–42.
151. Freed K, Low VH. The aberrant subclavian artery. *AJR Am J Roentgenol.* 1997;168:481–4.
152. Kouchoukos NT, Masetti P. Aberrant subclavian artery and Kommerell aneurysm: surgical treatment with a standard approach. *J Thorac Cardiovasc Surg.* 2007;133:888–92.
153. Simon RW, Lachat M, Pfammatter T, et al. Giant aneurysm of an aberrant right subclavian artery from the left aortic arch. *J Thorac Cardiovasc Surg.* 2006;132:1478–9.
154. Ou P, Mousseaux E, Celermajer DS, et al. Aortic arch shape deformation after coarctation surgery: effect on blood pressure response. *J Thorac Cardiovasc Surg.* 2006;132:1105–11.
155. Kutty S, Greenberg RK, Fletcher S, et al. Endovascular stent grafts for large thoracic aneurysms after coarctation repair. *Ann Thorac Surg.* 2008;85:1332–8.
156. Lajos TZ, Meckstroth CV, Klassen KP, et al. Pseudocoarctation of the aorta: a variant or an entity? *Chest.* 1970;58:571–6.
157. Felson B, Palayew MJ. The two types of right aortic arch. *Radiology.* 1963;81:745–59.
158. Kerr GS, Hallahan CW, Giordano J, et al. Takayasu arteritis. *Ann Intern Med.* 1994;120:919–29.
159. Mazlumzadeh M, Hunder GG, Easley KA, et al. Treatment of giant cell arteritis using induction therapy with high-dose glucocorticoids: a double-blind, placebo-controlled, randomized prospective clinical trial. *Arthritis Rheum.* 2006;54:3310–8.
160. Ishikawa K, Maetani S. Long-term outcome for 120 Japanese patients with Takayasu's disease. Clinical and statistical analyses of related prognostic factors. *Circulation.* 1994;90:1855–60.
161. Kyle V, Cawston TE, Hazleman BL. Erythrocyte sedimentation rate and C reactive protein in the assessment of polymyalgia rheumatica/giant cell arteritis on presentation and during follow up. *Ann Rheum Dis.* 1989;48:667–71.
162. Fields CE, Bower TC, Cooper LT, et al. Takayasu's arteritis: operative results and influence of disease activity. *J Vasc Surg.* 2006;43:64–71.
163. Arend WP, Michel BA, Bloch DA, et al. The American College of Rheumatology 1990 criteria for the classification of Takayasu arteritis. *Arthritis Rheum.* 1990;33:1129–34.
164. Hunder GG, Bloch DA, Michel BA, et al. The American College of Rheumatology 1990 criteria for the classification of giant cell arteritis. *Arthritis Rheum.* 1990;33:1122–8.
165. Evaluation of diagnostic ('classification') criteria in Behcet's disease: towards internationally agreed criteria. The International Study Group for Behcet's disease. *Br J Rheumatol.* 1992;31:299–308.
166. Goie The HS, Steven MM, van der Linden SM, et al. Evaluation of diagnostic criteria for ankylosing spondylitis: a comparison of the Rome, New York and modified New York criteria in patients with a positive clinical history screening test for ankylosing spondylitis. *Br J Rheumatol.* 1985;24:242–9.
167. Hata A, Noda M, Moriwaki R, et al. Angiographic findings of Takayasu arteritis: new classification. *Int J Cardiol.* 1996;54 Suppl:S155–S163.
168. Yajima M, Numano F, Park YB, et al. Comparative studies of patients with Takayasu arteritis in Japan, Korea and India: comparison of clinical manifestations, angiography and HLA-B antigen. *Jpn Circ J.* 1994;58:9–14.
169. Sharma BK, Sagar S, Singh AP, et al. Takayasu arteritis in India. *Heart Vessels Suppl.* 1992;7:37–43.
170. Matsumura K, Hirano T, Takeda K, et al. Incidence of aneurysms in Takayasu's arteritis. *Angiology.* 1991;42:308–15.
171. Weaver FA, Kumar SR, Yellin AE, et al. Renal revascularization in Takayasu arteritis-induced renal artery stenosis. *J Vasc Surg.* 2004;39:749–57.
172. Fava MP, Foradori GB, Garcia CB, et al. Percutaneous transluminal angioplasty in patients with Takayasu arteritis: five-year experience. *J Vasc Interv Radiol.* 1993;4:649–52.
173. Tyagi S, Verma PK, Gambhir DS, et al. Early and long-term results of subclavian angioplasty in aortoarteritis (Takayasu disease): comparison with atherosclerosis. *Cardiovasc Intervent Radiol.* 1998;21:219–24.
174. Miyata T, Sato O, Deguchi J, et al. Anastomotic aneurysms after surgical treatment of Takayasu's arteritis: a 40-year experience. *J Vasc Surg.* 1998;27:438–45.
175. Hunder GG. Epidemiology of giant-cell arteritis. *Cleve Clin J Med.* 2002;69 Suppl 2:SII79–SII82.
176. Nordborg E, Andersson R, Bengtsson BA. Giant cell arteritis. Epidemiology and treatment. *Drugs Aging.* 1994;4:135–44.
177. Chmielewski WL, McKnight KM, Agudelo CA, et al. Presenting features and outcomes in patients undergoing temporal artery biopsy. A review of 98 patients. *Arch Intern Med.* 1992;152:1690–5.
178. Nuenninghoff DM, Hunder GG, Christianson TJ, et al. Incidence and predictors of large-artery complication (aortic aneurysm, aortic dissection, and/or large-artery stenosis) in patients with giant cell arteritis: a population-based study over 50 years. *Arthritis Rheum.* 2003;48:3522–31.
179. Lie JT. Aortic and extracranial large vessel giant cell arteritis: a review of 72 cases with histopathologic documentation. *Semin Arthritis Rheum.* 1995;24:422–31.
180. Taylor-Gjevre R, Vo M, Shukla D, et al. Temporal artery biopsy for giant cell arteritis. *J Rheumatol.* 2005;32:1279–82.
181. Achkar AA, Lie JT, Hunder GG, et al. How does previous corticosteroid treatment affect the biopsy findings in giant cell (temporal) arteritis? *Ann Intern Med.* 1994;120:987–92.
182. Hunder GG, Sheps SG, Allen GL, et al. Daily and alternate-day corticosteroid regimens in treatment of giant cell arteritis: comparison in a prospective study. *Ann Intern Med.* 1975;82:613–8.
183. Neshar G, Rubinow A, Sonnenblick M. Efficacy and adverse effects of different corticosteroid dose regimens in temporal arteritis: a retrospective study. *Clin Exp Rheumatol.* 1997;15:303–6.
184. Salvarani C, Cantini F, Boiardi L, et al. Polymyalgia rheumatica and giant-cell arteritis. *N Engl J Med.* 2002;347:261–71.
- 184a. Hoffman GS, Cid MC, Hellmann DB, et al. A multicenter, randomized, double-blind, placebo-controlled trial of adjuvant methotrexate treatment for giant cell arteritis. *Arthritis Rheum.* 2002;46:1309–18.
185. Azizlerli G, Kose AA, Sarica R, et al. Prevalence of Behcet's disease in Istanbul, Turkey. *Int J Dermatol.* 2003;42:803–6.
186. Idil A, Gurler A, Boyvat A, et al. The prevalence of Behcet's disease above the age of 10 years. The results of a pilot study conducted at the Park Primary Health Care Center in Ankara, Turkey. *Ophthalmic Epidemiol.* 2002;9:325–31.
187. Sakane T, Takeno M, Suzuki N, et al. Behcet's disease. *N Engl J Med.* 1999;341:1284–91.
188. Criteria for diagnosis of Behcet's disease. International Study Group for Behcet's Disease. *Lancet.* 1990;335:1078–80.
189. Sarica-Kucukoglu R, Akdag-Kose A, Kayaball M, et al. Vascular involvement in Behcet's disease: a retrospective analysis of 2319 cases. *Int J Dermatol.* 2006;45:919–21.
190. Tunaci A, Berkmen YM, Gokmen E. Thoracic involvement in Behcet's disease: pathologic, clinical, and imaging features. *AJR Am J Roentgenol.* 1995;164:51–6.
191. Kisacikoglu B, Tansal S, Tokcan A, et al. 1992. Behcet's Disease and Arterial Aneurysms. *Journal of Islamic Academy of Sciences.* 1992; 290–3.
192. Hosaka A, Miyata T, Shigematsu H, et al. Long-term outcome after surgical treatment of arterial lesions in Behcet disease. *J Vasc Surg.* 2005;42:116–21.
193. Park JH, Chung JW, Joh JH, et al. Aortic and arterial aneurysms in behcet disease: management with stent-grafts: initial experience. *Radiology.* 2001;220:745–50.
194. Brewerton DA, Hart FD, Nicholls A, et al. Ankylosing spondylitis and HL-A 27. *Lancet.* 1973;1:904–7.

195. Khan MA. Update on spondyloarthropathies. *Ann Intern Med.* 2002;136:896–907.
196. Braun J, Sieper J. Ankylosing spondylitis. *Lancet.* 2007;369:1379–90.
197. van der Linden S, Valkenburg HA, Cats A. Evaluation of diagnostic criteria for ankylosing spondylitis. A proposal for modification of the New York criteria. *Arthritis Rheum.* 1984;27:361–8.
198. Roldan CA, Chavez J, Wiest PW, et al. Aortic root disease and valve disease associated with ankylosing spondylitis. *J Am Coll Cardiol.* 1998;32:1397–404.
199. Osler W. The Gulstonian lectures on malignant endocarditis. *BMJ.* 1885;1:467–70.
200. Follis FM, Paone RF, Wernly JA. Mycotic aneurysm of the ascending aorta after coronary revascularization. *Ann Thorac Surg.* 1994;58:236–8.
201. Morgan MB, Cintron G, Balis JU. Infective “mycotic” aortic root aneurysm following coronary artery bypass grafting. *Am J Med.* 1993;94:550–2.
202. Oz MC, Brener BJ, Buda JA, et al. A ten-year experience with bacterial aortitis. *J Vasc Surg.* 1989;10:439–49.
203. Cina CS, Arena GO, Fiture AO, et al. Ruptured mycotic thoracoabdominal aortic aneurysms: a report of three cases and a systematic review. *J Vasc Surg.* 2001;33:861–7.
204. Malouf JF, Chandrasekaran K, Orszulak TA. Mycotic aneurysms of the thoracic aorta: a diagnostic challenge. *Am J Med.* 2003;115:489–96.
205. Byard RW, Jimenez CL, Carpenter BF, et al. Aspergillus-related aortic thrombosis. *CMAJ.* 1987;136:155–6.
206. Allins AD, Wagner WH, Cossman DV, et al. Tuberculous infection of the descending thoracic and abdominal aorta: case report and literature review. *Ann Vasc Surg.* 1999;13:439–44.
207. Lai WW, Colan SD, Easley KA, et al. Dilatation of the aortic root in children infected with human immunodeficiency virus type 1: The Prospective P2C2 HIV Multicenter Study. *Am Heart J.* 2001;141:661–70.
208. Brawley JG, Clagett GP. Mycotic aortic aneurysm. *J Vasc Surg.* 2005;42:172.
209. Vilacosta I, Roman JA. Acute aortic syndrome. *Heart.* 2001;85:365–8.
210. Roberts CS, Roberts WC. Aortic dissection with the entrance tear in the descending thoracic aorta. Analysis of 40 necropsy patients. *Ann Surg.* 1991;213:356–68.
211. Svensson LG, Nadolny EM, Kimmel WA. Multimodal protocol influence on stroke and neurocognitive deficit prevention after ascending/arch aortic operations. *Ann Thorac Surg.* 2002;74:2040–6.
212. Svensson LG, Labib SB, Eisenhauer AC, et al. Intimal tear without hematoma: an important variant of aortic dissection that can elude current imaging techniques. *Circulation.* 1999;99:1331–6.
213. Chirillo F, Salvador L, Bacchion F, et al. Clinical and anatomical characteristics of subtle-discrete dissection of the ascending aorta. *Am J Cardiol.* 2007;100:1314–9.
214. Murray CA, Edwards JE. Spontaneous laceration of ascending aorta. *Circulation.* 1973;47:848–58.
215. Meszaros I, Morocz J, Szlavi J, et al. Epidemiology and clinicopathology of aortic dissection. *Chest.* 2000;117:1271–8.
216. Bickerstaff LK, Pairolo PC, Hollier LH, et al. Thoracic aortic aneurysms: a population-based study. *Surgery.* 1982;92:1103–8.
217. Clouse WD, Hallett JW, Jr., Schaff HV, et al. Acute aortic dissection: population-based incidence compared with degenerative aortic aneurysm rupture. *Mayo Clin Proc.* 2004;79:176–80.
218. Olsson C, Thelin S, Stahle E, et al. Thoracic aortic aneurysm and dissection: increasing prevalence and improved outcomes reported in a nationwide population-based study of more than 14,000 cases from 1987 to 2002. *Circulation.* 2006;114:2611–8.
219. Anagnostopoulos CE, Prabhakar MJ, Kittle CF. Aortic dissections and dissecting aneurysms. *Am J Cardiol.* 1972;30:263–73.
220. Hirst AE Jr., Johns VJ Jr., Kime SW Jr. Dissecting aneurysm of the aorta: a review of 505 cases. *Medicine (Baltimore).* 1958;37:217–79.
221. Masuda Y, Yamada Z, Morooka N, et al. 1991. Prognosis of patients with medically treated aortic dissections. *Circulation.* 84:III7–III13.
222. Crawford ES, Kirklin JW, Naftel DC, et al. Surgery for acute dissection of ascending aorta. Should the arch be included? *J Thorac Cardiovasc Surg.* 1992;104:46–59.
223. Januzzi JL, Isselbacher EM, Fattori R, et al. Characterizing the young patient with aortic dissection: results from the International Registry of Aortic Dissection (IRAD). *J Am Coll Cardiol.* 2004;43:665–9.
224. Milewicz DM, Michael K, Fisher N, et al. Fibrillin-1 (FBN1) mutations in patients with thoracic aortic aneurysms. *Circulation.* 1996;94:2708–11.
225. Francke U, Berg MA, Tynan K, et al. A Gly1127Ser mutation in an EGF-like domain of the fibrillin-1 gene is a risk factor for ascending aortic aneurysm and dissection. *Am J Hum Genet.* 1995;56:1287–96.
226. Hatzaras IS, Bible JE, Koullias GJ, et al. Role of exertion or emotion as inciting events for acute aortic dissection. *Am J Cardiol.* 2007;100:1470–2.
- 226a. Patel MR, Dehmer GJ, Hirshfeld JW, et al. ACCF/SCAI/STS/AATS/AHA/ASNC 2009 Appropriateness Criteria for Coronary Revascularization. *J Am Coll Cardiol.* 2009;53:530–53.
227. Pape LA, Tsai TT, Isselbacher EM, et al. Aortic diameter  $\geq$  or = 5.5 cm is not a good predictor of type A aortic dissection: observations from the International Registry of Acute Aortic Dissection (IRAD). *Circulation.* 2007;116:1120–7.
228. Miller DC, Stinson EB, Oyer PE, et al. Operative treatment of aortic dissections. Experience with 125 patients over a sixteen-year period. *J Thorac Cardiovasc Surg.* 1979;78:365–82.
229. Cachera JP, Vouhe PR, Loisanse DY, et al. Surgical management of acute dissections involving the ascending aorta. Early and late results in 38 patients. *J Thorac Cardiovasc Surg.* 1981;82:576–84.
230. Jex RK, Schaff HV, Piehler JM, et al. Repair of ascending aortic dissection. Influence of associated aortic valve insufficiency on early and late results. *J Thorac Cardiovasc Surg.* 1987;93:375–84.
231. Fann JI, Smith JA, Miller DC, et al. 1995 Surgical management of aortic dissection during a 30-year period. *Circulation.* 1995;92:III113–III121.
232. Mazzucotelli JP, Deleuze PH, Baufretton C, et al. Preservation of the aortic valve in acute aortic dissection: long-term echocardiographic assessment and clinical outcome. *Ann Thorac Surg.* 1993;55:1513–7.
233. Von Segesser LK, Lorenzetti E, Lachat M, et al. Aortic valve preservation in acute type A dissection: is it sound? *J Thorac Cardiovasc Surg.* 1996;111:381–90.
234. Massimo CG, Presenti LF, Marranci P, et al. Extended and total aortic resection in the surgical treatment of acute type A aortic dissection: experience with 54 patients. *Ann Thorac Surg.* 1998;46:420–4.
235. Movsowitz HD, Levine RA, Hilgenberg AD, et al. Transesophageal echocardiographic description of the mechanisms of aortic regurgitation in acute type A aortic dissection: implications for aortic valve repair. *J Am Coll Cardiol.* 2000;36:884–90.
236. Januzzi JL, Eagle KA, Cooper JV, et al. Acute aortic dissection presenting with congestive heart failure: results from the International Registry of Acute Aortic Dissection. *J Am Coll Cardiol.* 2005;46:733–5.
237. Sullivan PR, Wolfson AB, Leckey RD, et al. Diagnosis of acute thoracic aortic dissection in the emergency department. *Am J Emerg Med.* 2000;18:46–50.
238. Baydin A, Nargis C, Nural MS, et al. Painless, acute aortic dissection presenting as an acute stroke. *Mt Sinai J Med.* 2006;73:1129–31.
239. Ayrık C, Cece H, Aslan O, et al. Seeing the invisible: painless aortic dissection in the emergency setting. *Emerg Med J.* 2006;23:e24.
240. Young J, Herd AM. Painless acute aortic dissection and rupture presenting as syncope. *J Emerg Med.* 2002;22:171–4.
241. Park SW, Hutchison S, Mehta RH, et al. Association of painless acute aortic dissection with increased mortality. *Mayo Clin Proc.* 2004;79:1252–7.
242. Nallamothu BK, Mehta RH, Saint S, et al. Syncope in acute aortic dissection: diagnostic, prognostic, and clinical implications. *Am J Med.* 2002;113:468–71.
243. Svensson LG, Crawford ES. Aortic dissection and aortic aneurysm surgery: clinical observations, experimental investigations, and statistical analyses. Part II *Curr Probl Surg.* 1992;29:913–1057.
244. Williams DM, Lee DY, Hamilton BH, et al. The dissected aorta: part III. Anatomy and radiologic diagnosis of branch-vessel compromise. *Radiology.* 1997;203:37–44.
245. Khan IA, Nair CK. Clinical, diagnostic, and management perspectives of aortic dissection. *Chest.* 2002;122:311–28.
246. Bossone E, Rampoldi V, Nienaber CA, et al. Usefulness of pulse deficit to predict in-hospital complications and mortality in patients with acute type A aortic dissection. *Am J Cardiol.* 2002;89:851–5.
247. Yagdi T, Atay Y, Engin C, et al. Impact of organ malperfusion on mortality and morbidity in acute type A aortic dissections. *J Card Surg.* 2006;21:363–9.

248. Henke PK, Williams DM, Upchurch GR, Jr., et al. Acute limb ischemia associated with type B aortic dissection: clinical relevance and therapy. *Surgery*. 2006;140:532–9.
249. Tsai TT, Bossone E, Isselbacher EM, et al. Clinical characteristics of hypotension in patients with acute aortic dissection. *Am J Cardiol*. 2005;95:48–52.
250. Neri E, Toscano T, Papalia U, et al. Proximal aortic dissection with coronary malperfusion: presentation, management, and outcome. *J Thorac Cardiovasc Surg*. 2001;121:552–60.
251. Lee SI, Pyun SB, Jang DH. Dysphagia and hoarseness associated with painless aortic dissection: a rare case of cardiovascular syndrome. *Dysphagia*. 2006;21:129–32.
252. Hansen MS, Nogareda GJ, Hutchison SJ. Frequency of and inappropriate treatment of misdiagnosis of acute aortic dissection. *Am J Cardiol*. 2007;99:852–6.
253. Gaul C, Dietrich W, Friedrich I, et al. Neurological symptoms in type A aortic dissections. *Stroke*. 2007;38:292–7.
254. Zull DN, Cydulka R. Acute paraplegia: a presenting manifestation of aortic dissection. *Am J Med*. 1988;84:765–70.
255. Fessler AJ, Alberts MJ. Stroke treatment with tissue plasminogen activator in the setting of aortic dissection. *Neurology*. 2000;54:1010.
256. Morita S, Shibata M, Nakagawa Y, et al. Painless acute aortic dissection with a left hemiparesis. *Neurocrit Care*. 2006;4:234–6.
257. Armstrong WF, Bach DS, Carey LM, et al. Clinical and echocardiographic findings in patients with suspected acute aortic dissection. *Am Heart J*. 1998;136:1051–60.
258. Garcia-Jimenez A, Peraza TA, Martinez LG, et al. Cardiac tamponade by aortic dissection in a hospital without cardiothoracic surgery. *Chest*. 1993;104:290–1.
259. Pretre R, Von Segesser LK. Aortic dissection. *Lancet*. 1997;349:1461–4.
260. Gilon D, Mehta RH, Oh JK, et al. Characteristics and in-hospital outcomes of patients with cardiac tamponade complicating type A acute aortic dissection. *Am J Cardiol*. 2009;103:1029–31.
261. von Kodolitsch Y, Schwartz AG, Nienaber CA. Clinical prediction of acute aortic dissection. *Arch Intern Med*. 2000;160:2977–82.
262. Kawarabuki K, Sakakibara T, Hirai M, et al. Acute aortic dissection presenting as a neurologic disorder. *J Stroke Cerebrovasc Dis*. 2006;15:26–9.
263. Kuhlmann TP, Powers RD. Painless aortic dissection: an unusual cause of syncope. *Ann Emerg Med*. 1984;13:549–51.
264. Spittell PC, Spittell JA, Jr., Joyce JW, et al. 1993. Clinical features and differential diagnosis of aortic dissection: experience with 236 cases (1980 through 1990). *Mayo Clin Proc*. 68:642–51.
265. Slater E. Aortic dissection: presentation and diagnosis. In: Dorghazi RM, Slater E, editors. *Aortic Dissection*. New York: McGraw-Hill 1983;61–70.
266. Sanders JS, Ferguson DW, Mark AL. Arterial baroreflex control of sympathetic nerve activity during elevation of blood pressure in normal man: dominance of aortic baroreflexes. *Circulation*. 1988;77:279–88.
267. Nienaber CA, Eagle KA. Aortic dissection: new frontiers in diagnosis and management: Part I: from etiology to diagnostic strategies. *Circulation*. 2003;108:628–35.
268. Holloway SF, Fayad PB, Kalb RG, et al. Painless aortic dissection presenting as a progressive myelopathy. *J Neurol Sci*. 1993;120:141–4.
269. Syed MA, Fiad TM. Transient paraplegia as a presenting feature of aortic dissection in a young man. *Emerg Med J*. 2002;19:174–5.
270. Zaidat OO, Ubogu EE, Lerner AJ. Recurrent transient ischemic attacks as the initial presenting manifestation of type A aortic dissection. *Ann Vasc Surg*. 2002;16:676–8.
271. John LC. Fluctuating neurological deficit with acute aortic dissection: the omega sign. *Int J Cardiol*. 2006;106:130–1.
272. Hata N, Tanaka K, Imaizumi T, et al. Clinical significance of pleural effusion in acute aortic dissection. *Chest*. 2002;121:825–30.
273. Gandelman G, Barzilay N, Krupsky M, et al. Left pleural hemorrhagic effusion. A presenting sign of thoracic aortic dissecting aneurysm. *Chest*. 1994;106:636–8.
274. Tristano AG, Tairouz Y. Painless right hemorrhagic pleural effusions as presentation sign of aortic dissecting aneurysm. *Am J Med*. 2005;118:794–5.
275. Little S, Johnson J, Moon BY, et al. Painless left hemorrhagic pleural effusion: An unusual presentation of dissecting ascending aortic aneurysm. *Chest*. 1999;116:1478–80.
276. Massetti M, Babatasi G, Saloux E, et al. Aorto-pulmonary fistula: a rare event in the evolution of a dissecting aneurysm of the thoracic aorta. *Eur J Cardiothorac Surg*. 1997;11:994–6.
277. Takahashi M, Ikeda U, Shimada K, et al. Unilateral pulmonary edema related to pulmonary artery compression resulting from acute dissecting aortic aneurysm. *Am Heart J*. 1993;126:1225–7.
278. Masuo M, Takano H, Takamoto S, et al. Pulmonary artery obstruction caused by thoracic aortic dissection: a case with unique pathological findings. *Circ J*. 2004;68:392–5.
279. Guidetti AS, Pik A, Peer A, et al. Haemoptysis as the sole presenting symptom of dissection of the aorta. *Thorax*. 1989;44:444–5.
280. Dickens P, Pittaluga S, Chau CH. Sudden death presenting as massive haemoptysis due to ruptured intrapulmonary aortic aneurysm. *Forensic Sci Int*. 1993;60:121–5.
281. Born C, Forster A, Rock C, et al. A case of an upper gastrointestinal bleeding due to a ruptured dissection of a right aortic arch. *Cardiovasc Intervent Radiol*. 2003;26:506–9.
282. Nath HP, Jaques PF, Soto B, et al. Aortic dissection masquerading as gastrointestinal disease. *Cardiovasc Intervent Radiol*. 1986;9:37–41.
283. Hollander JE, Quick G. Aortoesophageal fistula: a comprehensive review of the literature. *Am J Med*. 1991;91:279–87.
284. Prisant LM, Nalamolu VR. Aortic dissection. *J Clin Hypertens (Greenwich)*. 2005;7:367–71.
285. Suzuki T, Mehta RH, Ince H, et al. Clinical profiles and outcomes of acute type B aortic dissection in the current era: lessons from the International Registry of Aortic Dissection (IRAD). *Circulation*. 2003;108(suppl 1):II312–II317.
286. Trimarchi S, Nienaber CA, Rampoldi V, et al. Role and results of surgery in acute type B aortic dissection: insights from the International Registry of Acute Aortic Dissection (IRAD). *Circulation*. 2006;114:1357–1364.
287. Tsai TT, Fattori R, Trimarchi S, et al. Long-term survival in patients presenting with type B acute aortic dissection: insights from the International Registry of Acute Aortic Dissection. *Circulation*. 2006;114:2226–31.
288. Mehta RH, O'Gara PT, Bossone E, et al. Acute type A aortic dissection in the elderly: clinical characteristics, management, and outcomes in the current era. *J Am Coll Cardiol*. 2002;40:685–92.
289. Nienaber CA, Fattori R, Mehta RH, et al. Gender-related differences in acute aortic dissection. *Circulation*. 2004;109:3014–21.
290. Evangelista A, Mukherjee D, Mehta RH, et al. Acute intramural hematoma of the aorta: a mystery in evolution. *Circulation*. 2005;111:1063–70.
291. Nienaber CA, von KY, Petersen B, et al. Intramural hemorrhage of the thoracic aorta. Diagnostic and therapeutic implications. *Circulation*. 1995;92:1465–72.
292. Mohr-Kahaly S, Erbel R, Kearney P, et al. Aortic intramural hemorrhage visualized by transesophageal echocardiography: findings and prognostic implications. *J Am Coll Cardiol*. 1994;23:658–64.
293. O'Gara PT, DeSanctis RW. Acute aortic dissection and its variants. Toward a common diagnostic and therapeutic approach. *Circulation*. 1995;92:1376–8.
294. Nienaber CA, Sievers HH. Intramural hematoma in acute aortic syndrome: more than one variant of dissection? *Circulation*. 2002;106:284–5.
295. Vilacosta I, San Roman JA, Ferreiros J, et al. Natural history and serial morphology of aortic intramural hematoma: a novel variant of aortic dissection. *Am Heart J*. 1997;134:495–507.
296. von Kodolitsch Y, Csoz SK, Koschyk DH, et al. Intramural hematoma of the aorta: predictors of progression to dissection and rupture. *Circulation*. 2003;107:1158–63.
297. Kaji S, Akasaka T, Katayama M, et al. Long-term prognosis of patients with type B aortic intramural hematoma. *Circulation*. 2003;108(suppl 1):II307–II311.
298. Sueyoshi E, Imada T, Sakamoto I, et al. Analysis of predictive factors for progression of type B aortic intramural hematoma with computed tomography. *J Vasc Surg*. 2002;35:1179–83.
299. Williams MP, Farrow R. Atypical patterns in the CT diagnosis of aortic dissection. *Clin Radiol*. 1994;49:686–9.
300. Sueyoshi E, Matsuoka Y, Sakamoto I, et al. Fate of intramural hematoma of the aorta: CT evaluation. *J Comput Assist Tomogr*. 1997;21:931–8.
301. Moizumi Y, Komatsu T, Motoyoshi N, et al. Clinical features and long-term outcome of type A and type B intramural hematoma of the aorta. *J Thorac Cardiovasc Surg*. 2004;127:421–7.



302. Choi SH, Choi SJ, Kim JH, et al. Useful CT findings for predicting the progression of aortic intramural hematoma to overt aortic dissection. *J Comput Assist Tomogr*. 2001;25:295–9.
303. Moriyama Y, Yotsumoto G, Kuriwaki K, et al. Intramural hematoma of the thoracic aorta. *Eur J Cardiothorac Surg*. 1998;13:230–9.
304. Kaji S, Akasaka T, Horibata Y, et al. Long-term prognosis of patients with type A aortic intramural hematoma. *Circulation*. 2002;106:1248–1252.
305. Murray JG, Manisali M, Flamm SD, et al. Intramural hematoma of the thoracic aorta: MR image findings and their prognostic implications. *Radiology*. 1997;204:349–55.
306. Lee YK, Seo JB, Jang YM, et al. Acute and chronic complications of aortic intramural hematoma on follow-up computed tomography: incidence and predictor analysis. *J Comput Assist Tomogr*. 2007;31:435–40.
307. Song JK, Kim HS, Kang DH, et al. Different clinical features of aortic intramural hematoma versus dissection involving the ascending aorta. *J Am Coll Cardiol*. 2001;37:1604–10.
308. Song JM, Kim HS, Song JK, et al. Usefulness of the initial noninvasive imaging study to predict the adverse outcomes in the medical treatment of acute type A aortic intramural hematoma. *Circulation*. 2003;108(suppl 1):II324–II328.
309. Stanson AW, Kazmier FJ, Hollier LH, et al. Penetrating atherosclerotic ulcers of the thoracic aorta: natural history and clinicopathologic correlations. *Ann Vasc Surg*. 1986;1:15–23.
310. Cho KR, Stanson AW, Potter DD, et al. Penetrating atherosclerotic ulcer of the descending thoracic aorta and arch. *J Thorac Cardiovasc Surg*. 2004;127:1393–9.
311. Harris JA, Bis KG, Glover JL, et al. Penetrating atherosclerotic ulcers of the aorta. *J Vasc Surg*. 1994;19:90–8.
312. Williams DM, Cronin P, Dasika N, et al. Aortic branch artery pseudoaneurysms accompanying aortic dissection. Part I Pseudoaneurysm anatomy. *J Vasc Interv Radiol*. 2006;17:765–71.
313. Pretre R, Chilcott M. Blunt trauma to the heart and great vessels. *N Engl J Med*. 1997;336:626–32.
314. Heller G, Immer FF, Savolainen H, et al. Aortic rupture in high-speed skiing crashes. *J Trauma*. 2006;61:979–80.
315. Gurkan S, Sunar H, Canbaz S, et al. Late manifestation of a pseudoaneurysm in the descending thoracic aorta. *Vasa*. 2006;35:112–4.
316. Patel TM, Shah SC, Ranjan A. Unusual retrograde aortic arch dissection during percutaneous coronary intervention: a case report. *Angiology*. 2006;57:501–5.
317. Lundevall J. Traumatic rupture of the aorta, with special reference to road accidents. *Acta Pathol Microbiol Scand*. 1964;62:29–33.
318. Parmley LF, Mattingly TW, Manion WC, et al. Nonpenetrating traumatic injury of the aorta. *Circulation*. 1958;17:1086–101.
319. Richens D, Kotidis K, Neale M, et al. Rupture of the aorta following road traffic accidents in the United Kingdom 1992–1999. The results of the co-operative crash injury study. *Eur J Cardiothorac Surg*. 2003;23:143–8.
320. Joyce JW, Fairbairn JF, Kincaid OW, et al. Aneurysms of the thoracic aorta. a clinical study with special reference to prognosis. *Circulation*. 1964;29:176–81.
321. Pate JW, Cole FH Jr., Walker WA, et al. Penetrating injuries of the aortic arch and its branches. *Ann Thorac Surg*. 1993;55:586–92.
322. Bruckner BA, DiBardino DJ, Cumbie TC, et al. Critical evaluation of chest computed tomography scans for blunt descending thoracic aortic injury. *Ann Thorac Surg*. 2006;81:1339–46.
323. Fabian TC, Davis KA, Gavant ML, et al. Prospective study of blunt aortic injury: helical CT is diagnostic and antihypertensive therapy reduces rupture. *Ann Surg*. 1998;227:666–76.
324. Roberts WC, Ko JM, Moore TR, et al. Causes of pure aortic regurgitation in patients having isolated aortic valve replacement at a single US tertiary hospital (1993 to 2005). *Circulation*. 2006;114:422–9.
325. Weber T, Hogler S, Auer J, et al. D-dimer in acute aortic dissection. *Chest*. 2003;123:1375–8.
326. Eggebrecht H, Naber CK, Bruch C, et al. Value of plasma fibrin D-dimers for detection of acute aortic dissection. *J Am Coll Cardiol*. 2004;44:804–9.
327. Suzuki T, Katoh H, Watanabe M, et al. Novel biochemical diagnostic method for aortic dissection. Results of a prospective study using an immunoassay of smooth muscle myosin heavy chain. *Circulation*. 1996;93:1244–9.
328. Suzuki T, Katoh H, Tsuchio Y, et al. Diagnostic implications of elevated levels of smooth-muscle myosin heavy-chain protein in acute aortic dissection. The Smooth Muscle Myosin Heavy Chain Study. *Ann Intern Med*. 2000;133:537–41.
329. American College of Emergency Physicians. Clinical policy: critical issues in the evaluation and management of adult patients presenting with suspected pulmonary embolism. *Ann Emerg Med*. 2003;41:257–70.
330. Marill KA. Serum D-dimer is a sensitive test for the detection of acute aortic dissection: a pooled meta-analysis. *J Emerg Med*. 2008;34:367–75.
331. Ohlmann P, Faure A, Morel O, et al. Diagnostic and prognostic value of circulating D-dimers in patients with acute aortic dissection. *Crit Care Med*. 2006;34:1358–64.
332. Elefteriades JA, Barrett PW, Kopf GS. Litigation in nontraumatic aortic diseases: a tempest in the malpractice maelstrom. *Cardiology*. 2008;109:263–72.
333. Antman EM, Anbe DT, Armstrong PW, et al. ACC/AHA guidelines for the management of patients with ST-elevation myocardial infarction: executive summary. *J Am Coll Cardiol*. 2004;44:671–719.
334. Estrera AL, Miller CC III, Safi HJ, et al. Outcomes of medical management of acute type B aortic dissection. *Circulation*. 2006;114:1384–1389.
335. Umana JP, Lai DT, Mitchell RS, et al. Is medical therapy still the optimal treatment strategy for patients with acute type B aortic dissections? *J Thorac Cardiovasc Surg*. 2002;124:896–910.
336. Mehta RH, Suzuki T, Hagan PG, et al. Predicting death in patients with acute type A aortic dissection. *Circulation*. 2002;105:200–6.
337. Chiappini B, Schepens M, Tan E, et al. Early and late outcomes of acute type A aortic dissection: analysis of risk factors in 487 consecutive patients. *Eur Heart J*. 2005;26:180–6.
338. Furman MI, Dauerman HL, Goldberg RJ, et al. Twenty-two year (1975 to 1997) trends in the incidence, in-hospital and long-term case fatality rates from initial Q-wave and non-Q-wave myocardial infarction: a multi-hospital, community-wide perspective. *J Am Coll Cardiol*. 2001;37:1571–80.
339. Isselbacher E. *Cecil Medicine*. 23rd ed. Philadelphia: Elsevier Health Sciences, 2008.
340. Libby P, Bonow RO, Mann DL, Zipes DP. *Braunwald's Heart Disease: A Textbook of Cardiovascular Medicine*. 8th ed. Philadelphia: 2007.
341. Townsend CM, Beauchamp RD, Evers BM, Mattox KL. *Sabiston Textbook of Surgery*. 18th ed. Philadelphia: Elsevier Health Sciences, 2008.
342. Mukherjee D, Eagle KA. Aortic dissection: an update. *Curr Probl Cardiol*. 2005;30:287–325.
343. Januzzi JL, Sabatine MS, Eagle KA, et al. Iatrogenic aortic dissection. *Am J Cardiol*. 2002;89:623–6.
344. Kario K, Ishikawa J, Pickering TG, et al. Morning hypertension: the strongest independent risk factor for stroke in elderly hypertensive patients. *Hypertens Res*. 2006;29:581–7.
345. Khoynzhad A, Plestis KA. Managing emergency hypertension in aortic dissection and aortic aneurysm surgery. *J Card Surg*. 2006;21(suppl 1):S3–S7.
346. Vriend JW, Mulder BJ. Late complications in patients after repair of aortic coarctation: implications for management. *Int J Cardiol*. 2005;101:399–406.
347. Eggebrecht H, Schermund A, von Birgelen C, et al. Resistant hypertension in patients with chronic aortic dissection. *J Hum Hypertens*. 2005;19:227–31.
348. Kim KH, Moon IS, Park JS, et al. Nicardipine hydrochloride injectable phase IV open-label clinical trial: study on the anti-hypertensive effect and safety of nicardipine for acute aortic dissection. *J Int Med Res*. 2002;30:337–45.
349. Isselbacher EM, Cigarroa JE, Eagle KA. Cardiac tamponade complicating proximal aortic dissection. Is pericardiocentesis harmful? *Circulation*. 1994;90:2375–8.
350. Kaji S, Nishigami K, Akasaka T, et al. Prediction of progression or regression of type A aortic intramural hematoma by computed tomography. *Circulation*. 1999;100:II281–II286.
351. Motoyoshi N, Moizumi Y, Komatsu T, et al. Intramural hematoma and dissection involving ascending aorta: the clinical features and prognosis. *Eur J Cardiothorac Surg*. 2003;24:237–42.
352. Moizumi Y, Komatsu T, Motoyoshi N, et al. Management of patients with intramural hematoma involving the ascending aorta. *J Thorac Cardiovasc Surg*. 2002;124:918–24.

353. Elefteriades JA, Hartleroad J, Gusberg RJ, et al. Long-term experience with descending aortic dissection: the complication-specific approach. *Ann Thorac Surg.* 1992;53:11–20.
354. Tittle SL, Lynch RJ, Cole PE, et al. Midterm follow-up of penetrating ulcer and intramural hematoma of the aorta. *J Thorac Cardiovasc Surg.* 2002;123:1051–9.
355. Nagy K, Fabian T, Rodman G, et al. Guidelines for the diagnosis and management of blunt aortic injury: an EAST Practice Management Guidelines Work Group. *J Trauma.* 2000;48:1128–43.
356. Xenos ES, Abedi NN, Davenport DL, et al. Meta-analysis of endovascular vs open repair for traumatic descending thoracic aortic rupture. *J Vasc Surg.* 2008;48:1343–51.
357. Galli R, Pacini D, Di BR, et al. Surgical indications and timing of repair of traumatic ruptures of the thoracic aorta. *Ann Thorac Surg.* 1998;65:461–4.
358. Pate JW, Gavant ML, Weiman DS, et al. Traumatic rupture of the aortic isthmus: program of selective management. *World J Surg.* 1999;23:59–63.
359. Svensson LG, Antunes MD, Kinsley RH. Traumatic rupture of the thoracic aorta. A report of 14 cases and a review of the literature. *S Afr Med J.* 1985;67:853–7.
360. von Oppell UO, Dunne TT, De Groot MK, et al. Traumatic aortic rupture: twenty-year metaanalysis of mortality and risk of paraplegia. *Ann Thorac Surg.* 1994;58:585–93.
361. Katz NM, Blackstone EH, Kirklin JW, et al. Incremental risk factors for spinal cord injury following operation for acute traumatic aortic transection. *J Thorac Cardiovasc Surg.* 1981;81:669–74.
362. Verdant A, Page A, Cossette R, et al. Surgery of the descending thoracic aorta: spinal cord protection with the Gott shunt. *Ann Thorac Surg.* 1988;46:147–54.
363. Hilgenberg AD, Logan DL, Akins CW, et al. Blunt injuries of the thoracic aorta. *Ann Thorac Surg.* 1992;53:233–8.
364. Pate JW, Fabian TC, Walker WA. Acute traumatic rupture of the aortic isthmus: repair with cardiopulmonary bypass. *Ann Thorac Surg.* 1995;59:90–8.
365. Lettinga-van de Poll T, Schurink GW, De Haan MW, et al. Endovascular treatment of traumatic rupture of the thoracic aorta. *Br J Surg.* 2007;94:525–33.
366. Muhs BE, Balm R, White GH, et al. Anatomic factors associated with acute endograft collapse after Gore TAG treatment of thoracic aortic dissection or traumatic rupture. *J Vasc Surg.* 2007;45:655–61.
367. Neschis DG, Moaine S, Gutta R, et al. Twenty consecutive cases of endograft repair of traumatic aortic disruption: lessons learned. *J Vasc Surg.* 2007;45:487–92.
368. Marcheix B, Dambrin C, Bolduc JP, et al. Endovascular repair of traumatic rupture of the aortic isthmus: midterm results. *J Thorac Cardiovasc Surg.* 2006;132:1037–41.
369. Kato N, Dake MD, Miller DC, et al. Traumatic thoracic aortic aneurysm: treatment with endovascular stent-grafts. *Radiology.* 1997;205:657–62.
370. Tehrani HY, Peterson BG, Katariya K, et al. Endovascular repair of thoracic aortic tears. *Ann Thorac Surg.* 2006;82:873–7.
371. Svensson LG, Kouchoukos NT, Miller DC, et al. Expert consensus document on the treatment of descending thoracic aortic disease using endovascular stent-grafts. *Ann Thorac Surg.* 2008;85:S1–41.
372. Clouse WD, Hallett JW Jr., Schaff HV, et al. Improved prognosis of thoracic aortic aneurysms: a population-based study. *JAMA.* 1998;280:1926–9.
373. Cambria RA, Gloviczki P, Stanson AW, et al. Outcome and expansion rate of 57 thoracoabdominal aortic aneurysms managed nonoperatively. *Am J Surg.* 1995;170:213–7.
374. Coady MA, Rizzo JA, Hammond GL, et al. What is the appropriate size criterion for resection of thoracic aortic aneurysms? *J Thorac Cardiovasc Surg.* 1997;113:476–91.
375. Davies RR, Goldstein LJ, Coady MA, et al. Yearly rupture or dissection rates for thoracic aortic aneurysms: simple prediction based on size. *Ann Thorac Surg.* 2002;73:17–27.
376. Jossierand J, Boura B, Yakhou L, et al. [Rupture of a thoracic aortic aneurysm into the right pleural cavity.] *Ann Fr Anesth Reanim.* 2006;25:997–9.
377. Eagle KA, Armstrong WF. Disease of the Aorta. In: Dale DC, Federman DD, editors. *Scientific American Medicine.* New York: WebMD; 2003.
378. Tsokos M, Byard RW. Massive, fatal aspiration of blood: not necessarily a result of trauma. *Am J Forensic Med Pathol.* 2007;28:53–4.
379. Crawford ES, Crawford JL, Safi HJ, et al. Thoracoabdominal aortic aneurysms: preoperative and intraoperative factors determining immediate and long-term results of operations in 605 patients. *J Vasc Surg.* 1986;3:389–404.
380. Estrera AL, Miller CC III, Chen EP, et al. Descending thoracic aortic aneurysm repair: 12-year experience using distal aortic perfusion and cerebrospinal fluid drainage. *Ann Thorac Surg.* 2005;80:1290–6.
381. Svensson LG, Crawford ES, Hess KR, et al. Experience with 1509 patients undergoing thoracoabdominal aortic operations. *J Vasc Surg.* 1993;17:357–68.
382. Svensson LG, Crawford ES, Hess KR, et al. Variables predictive of outcome in 832 patients undergoing repairs of the descending thoracic aorta. *Chest.* 1993;104:1248–53.
383. Achneck H, Modi B, Shaw C, et al. Ascending thoracic aneurysms are associated with decreased systemic atherosclerosis. *Chest.* 2005;128:1580–6.
384. Anandaraja S, Mukhopadhyay S, Roy S, et al. Left main coronary artery aneurysm in Takayasu arteritis. *Echocardiography.* 2006;23:430–1.
385. Haddy SM, Bhatt M, Patel JM. Right coronary artery aneurysm in a patient with Takayasu's arteritis. *Echocardiography.* 2007;24:1108–9.
386. Chun PK, Jones R, Robinowitz M, et al. Coronary ostial stenosis in Takayasu's arteritis. *Chest.* 1980;78:330–1.
387. Kihara M, Kimura K, Yakuwa H, et al. Isolated left coronary ostial stenosis as the sole arterial involvement in Takayasu's disease. *J Intern Med.* 1992;232:353–5.
388. Feder W, Uerbach R. "Purple toes": an uncommon sequela of oral coumarin drug therapy. *Ann Intern Med.* 1961;55:911–7.
389. Rosansky SJ, Deschamps EG. Multiple cholesterol emboli syndrome after angiography. *Am J Med Sci.* 1984;288:45–8.
390. Ramirez G, O'Neill WM Jr., Lambert R, et al. Cholesterol embolization: a complication of angiography. *Arch Intern Med.* 1978;138:1430–2.
391. Drost H, Buis B, Haan D, et al. Cholesterol embolism as a complication of left heart catheterisation. Report of seven cases. *Br Heart J.* 1984;52:339–42.
392. Hyman BT, Landas SK, Ashman RF, et al. Warfarin-related purple toes syndrome and cholesterol microembolization. *Am J Med.* 1987;82:1233–7.
393. Shapiro LS. Cholesterol embolization after treatment with tissue plasminogen activator. *N Engl J Med.* 1989;321:1270.
394. Bols A, Nevelsteen A, Verhaeghe R. Atheromatous embolization precipitated by oral anticoagulants. *Int Angiol.* 1994;13:271–4.
395. Scolari F, Bracchi M, Valzorio B, et al. Cholesterol atheromatous embolism: an increasingly recognized cause of acute renal failure. *Nephrol Dial Transplant.* 1996;11:1607–12.
396. Dressler FA, Craig WR, Castello R, et al. Mobile aortic atheroma and systemic emboli: efficacy of anticoagulation and influence of plaque morphology on recurrent stroke. *J Am Coll Cardiol.* 1998;31:134–8.
397. Davila-Roman VG, Kouchoukos NT, Schechtman KB, et al. Atherosclerosis of the ascending aorta is a predictor of renal dysfunction after cardiac operations. *J Thorac Cardiovasc Surg.* 1999;117:111–6.
398. Blankenship JC, Butler M, Garbes A. Prospective assessment of cholesterol embolization in patients with acute myocardial infarction treated with thrombolytic vs conservative therapy. *Chest.* 1995;107:662–8.
399. Meyrier A. Cholesterol crystal embolism: diagnosis and treatment. *Kidney Int.* 2006;69:1308–12.
400. Hazanov N, Somin M, Attali M, et al. Acute renal embolism. Forty-four cases of renal infarction in patients with atrial fibrillation. *Medicine (Baltimore).* 2004;83:292–9.
401. Lock G. Acute intestinal ischaemia. *Best Pract Res Clin Gastroenterol.* 2001;15:83–98.
402. Wolf EL, Sprayregen S, Bakal CW. Radiology in intestinal ischemia. Plain film, contrast, and other imaging studies. *Surg Clin North Am.* 1992;72:107–24.
403. Rhee RY, Gloviczki P. Mesenteric venous thrombosis. *Surg Clin North Am.* 1997;77:327–38.
404. Rahmouni A, Mathieu D, Golli M, et al. Value of CT and sonography in the conservative management of acute splenoportal and superior mesenteric venous thrombosis. *Gastrointest Radiol.* 1992;17:135–40.
405. Kirkpatrick ID, Kroeker MA, Greenberg HM. Biphasic CT with mesenteric CT angiography in the evaluation of acute mesenteric ischemia: initial experience. *Radiology.* 2003;229:91–8.
406. Grierson C, Uthappa MC, Uberoi R, et al. Multidetector CT appearances of splanchnic arterial pathology. *Clin Radiol.* 2007;62:717–23.
407. Kramer H, Nikolaou K, Sommer W, et al. Peripheral MR angiography. *Magn Reson Imaging Clin N Am.* 2009;17:91–100.

408. Robinson BL, Nadolny EM, Entrup MH, et al. Management of right-sided aortic arch aneurysms. *Ann Thorac Surg*. 2001;72:1764–5.
409. Smith SC Jr., Allen J, Blair SN, et al. AHA/ACC guidelines for secondary prevention for patients with coronary and other atherosclerotic vascular disease. *J Am Coll Cardiol*. 2006;47:2130–9.
410. Genoni M, Paul M, Jenni R, et al. Chronic beta-blocker therapy improves outcome and reduces treatment costs in chronic type B aortic dissection. *Eur J Cardiothorac Surg*. 2001;19:606–10.
411. Ladouceur M, Fermanian C, Lupoglazoff JM, et al. Effect of beta-blockade on ascending aortic dilatation in children with the Marfan syndrome. *Am J Cardiol*. 2007;99:406–9.
412. Ahimastos AA, Aggarwal A, D'Orsa KM, et al. Effect of perindopril on large artery stiffness and aortic root diameter in patients with Marfan syndrome: a randomized controlled trial. *JAMA*. 2007;298:1539–47.
413. Mochizuki S, Dahlöf B, Shimizu M, et al. Valsartan in a Japanese population with hypertension and other cardiovascular disease (Jikei Heart Study): a randomised, open-label, blinded endpoint morbidity-mortality study. *Lancet*. 2007;369:1431–9.
414. Diehm N, Becker G, Katzen B, et al. Statins are associated with decreased mortality in abdominal, but not in thoracic aortic aneurysm patients undergoing endovascular repair: propensity score-adjusted analysis. *Vasa*. 2008;37:241–9.
415. Major outcomes in high-risk hypertensive patients randomized to angiotensin-converting enzyme inhibitor or calcium channel blocker vs diuretic: The Antihypertensive and Lipid-Lowering Treatment to Prevent Heart Attack Trial (ALLHAT). *JAMA*. 2002;288:2981–97.
416. Hunt SA, Baker DW, Chin MH, et al. ACC/AHA guidelines for the evaluation and management of chronic heart failure in the adult: executive summary. *J Am Coll Cardiol*. 2001;38:2101–13.
417. Lewington S, Clarke R, Qizilbash N, et al. Age-specific relevance of usual blood pressure to vascular mortality: a meta-analysis of individual data for one million adults in 61 prospective studies. *Lancet*. 2002;360:1903–13.
418. Neal B, MacMahon S, Chapman N. Effects of ACE inhibitors, calcium antagonists, and other blood-pressure-lowering drugs: results of prospectively designed overviews of randomised trials. Blood Pressure Lowering Treatment Trialists' Collaboration. *Lancet*. 2000;356:1955–64.
419. Ogden LG, He J, Lydick E, et al. Long-term absolute benefit of lowering blood pressure in hypertensive patients according to the JNC VI risk stratification. *Hypertension*. 2000;35:539–43.
420. Psaty BM, Smith NL, Siscovick DS, et al. Health outcomes associated with antihypertensive therapies used as first-line agents. A systematic review and meta-analysis. *JAMA*. 1997;277:739–45.
421. Chobanian AV, Bakris GL, Black HR, et al. Seventh report of the Joint National Committee on Prevention, Detection, Evaluation, and Treatment of High Blood Pressure. *Hypertension*. 2003;42:1206–52.
422. Evans J, Powell JT, Schwalbe E, et al. Simvastatin attenuates the activity of matrix metalloproteinase-9 in aneurysmal aortic tissue. *Eur J Vasc Endovasc Surg*. 2007;34:302–3.
423. Leurs LJ, Visser P, Laheij RJ, et al. Statin use is associated with reduced all-cause mortality after endovascular abdominal aortic aneurysm repair. *Vascular*. 2006;14:1–8.
424. Kurzenewy D, Filion KB, Pilote L, et al. Cardiac medical therapy among patients undergoing abdominal aortic aneurysm repair. *Ann Vasc Surg*. 2006;20:569–76.
425. Yilmaz MB, Biyikoglu SF, Guray Y, et al. Level of awareness of on-treatment patients about prescribed statins. *Cardiovasc Drugs Ther*. 2004;18:399–404.
426. Executive Summary of The Third Report of The National Cholesterol Education Program (NCEP) Expert Panel on Detection, Evaluation, and Treatment of High Blood Cholesterol In Adults (Adult Treatment Panel III). *JAMA*. 2001;285:2486–97.
427. MRC/BHF Heart Protection Study of cholesterol lowering with simvastatin in 20,536 high-risk individuals: a randomised placebo-controlled trial. *Lancet*. 2002;360:7–22.
428. Schouten O, van Laanen JH, Boersma E, et al. Statins are associated with a reduced infrarenal abdominal aortic aneurysm growth. *Eur J Vasc Endovasc Surg*. 2006;32:21–6.
429. Diehm N, Baumgartner I. ACE inhibitors and abdominal aortic aneurysm. *Lancet*. 2006;368:622–3.
430. Verma S, Lindsay TF. Regression of aortic aneurysms through pharmacologic therapy? *N Engl J Med*. 2006;354:2067–8.
431. Anderson JL, Adams CD, Antman EM, et al. ACC/AHA 2007 guidelines for the management of patients with unstable angina/non-ST-elevation myocardial infarction. *J Am Coll Cardiol*. 2007;50:e1–e157.
432. Ockene IS, Miller NH. Cigarette smoking, cardiovascular disease, and stroke: a statement for healthcare professionals from the American Heart Association. American Heart Association Task Force on Risk Reduction Circulation. 1997;96:3243–7.
- 432a. Daly LE, Mulcahy R, Graham IM, Hickey N. Long term effect on mortality of stopping smoking after unstable angina and myocardial infarction. *Br Med J (Clin Res Ed)*. 1983;287:324–6.
- 432b. U.S. Department of Health and Human Services, Public Health Service Agency. Clinical Practice Guidelines: Number 18. Smoking Cessation 1996; AHCPR Publication 96-0692.
433. Dapunt OE, Galla JD, Sadeghi AM, et al. The natural history of thoracic aortic aneurysms. *J Thorac Cardiovasc Surg*. 1994;107:1323–32.
434. Griep RB, Ergin MA, Galla JD, et al. Natural history of descending thoracic and thoracoabdominal aneurysms. *Ann Thorac Surg*. 1999;67:1927–30.
435. Jonason T, Bergstrom R. Cessation of smoking in patients with intermittent claudication. Effects on the risk of peripheral vascular complications, myocardial infarction and mortality. *Acta Med Scand*. 1987;221:253–60.
436. Kouchouk NT, Dougenis D. Surgery of the thoracic aorta. *N Engl J Med*. 1997;336:1876–88.
437. Elefteriades JA. Natural history of thoracic aortic aneurysms: indications for surgery, and surgical versus nonsurgical risks. *Ann Thorac Surg*. 2002;74:S1877–S1880.
438. Tzemos N, Therrien J, Yip J, et al. Outcomes in adults with bicuspid aortic valves. *JAMA*. 2008;300:1317–25.
439. Valley MP, Semsarian C, Bannon PG. Management of the ascending aorta in patients with bicuspid aortic valve disease. *Heart Lung Circ*. 2008;17:357–63.
440. Coady MA, Rizzo JA, Hammond GL, et al. Surgical intervention criteria for thoracic aortic aneurysms: a study of growth rates and complications. *Ann Thorac Surg*. 1999;67:1922–6.
441. Kouchouk NT. Composite graft replacement of the ascending aorta and aortic valve with the inclusion-wrap and open techniques. *Semin Thorac Cardiovasc Surg*. 1991;3:171–6.
442. Abedin M, Tintut Y, Demer LL. Vascular calcification: mechanisms and clinical ramifications. *Arterioscler Thromb Vasc Biol*. 2004;24:1161–70.
443. Iribarren C, Sidney S, Sternfeld B, et al. Calcification of the aortic arch: risk factors and association with coronary heart disease, stroke, and peripheral vascular disease. *JAMA*. 2000;283:2810–5.
444. Chiu KM, Lin TY, Chen JS, et al. Images in cardiovascular medicine. Left ventricle apical conduit to bilateral subclavian artery in a patient with porcelain aorta and aortic stenosis. *Circulation*. 2006;113:e388–e389.
445. Robicsek F, Cook JW, Reames MK Sr, et al. Size reduction ascending aortoplasty: is it dead or alive? *J Thorac Cardiovasc Surg*. 2004;128:562–70.
446. Sievers HH. Reflections on reduction ascending aortoplasty's liveliness. *J Thorac Cardiovasc Surg*. 2004;128:499–501.
447. Miller DC. Valve-sparing aortic root replacement: current state of the art and where are we headed? *Ann Thorac Surg*. 2007;83:S736–S739.
448. Svensson LG, Longoria J, Kimmel WA, et al. Management of aortic valve disease during aortic surgery. *Ann Thorac Surg*. 2000;69:778–83.
449. Svensson LG, Blackstone EH, Rajeswaran J, et al. Does the arterial cannulation site for circulatory arrest influence stroke risk? *Ann Thorac Surg*. 2004;78:1274–84.
450. Svensson LG, Crawford ES, Hess KR, et al. Dissection of the aorta and dissecting aortic aneurysms. Improving early and long-term surgical results. *Circulation*. 1990;82:IV24–IV38.
451. Greenberg RK, Haddad F, Svensson L, et al. Hybrid approaches to thoracic aortic aneurysms: the role of endovascular elephant trunk completion. *Circulation*. 2005;112:2619–26.
452. Svensson LG. The elephant trunk procedure: uses in complex aortic diseases. *Curr Opin Cardiol*. 2005;20:491–5.
453. Svensson LG, Kim KH, Blackstone EH, et al. Elephant trunk procedure: newer indications and uses. *Ann Thorac Surg*. 2004;78:109–16.
454. Kazui T, Washiyama N, Muhammad BA, et al. Total arch replacement using aortic arch branched grafts with the aid of antegrade selective cerebral perfusion. *Ann Thorac Surg*. 2000;70:3–8.

455. Kazui T, Washiyama N, Muhammad BA, et al. Improved results of atherosclerotic arch aneurysm operations with a refined technique. *J Thorac Cardiovasc Surg.* 2001;121:491-9.
456. Kouchoukos NT, Mauney MC, Masetti P, et al. Single-stage repair of extensive thoracic aortic aneurysms: experience with the arch-first technique and bilateral anterior thoracotomy. *J Thorac Cardiovasc Surg.* 2004;128:669-76.
457. Lemaire SA, Carter SA, Coselli JS. The elephant trunk technique for staged repair of complex aneurysms of the entire thoracic aorta. *Ann Thorac Surg.* 2006;81:1561-9.
458. Safi HJ, Miller CC III, Estrera AL, et al. Staged repair of extensive aortic aneurysms: long-term experience with the elephant trunk technique. *Ann Surg.* 2004;240:677-84.
459. Strauch JT, Spielvogel D, Lauten A, et al. Technical advances in total aortic arch replacement. *Ann Thorac Surg.* 2004;77:581-9.
460. Czerny M, Gottardi R, Zimpfer D, et al. Transposition of the supraaortic branches for extended endovascular arch repair. *Eur J Cardiothorac Surg.* 2006;29:709-13.
461. Bergeron P, Mangialardi N, Costa P, et al. Great vessel management for endovascular exclusion of aortic arch aneurysms and dissections. *Eur J Vasc Endovasc Surg.* 2006;32:38-45.
462. Griep RB. Cerebral protection during aortic arch surgery. *J Thorac Cardiovasc Surg.* 2001;121:425-7.
463. Lin R, Svensson L, Gupta R, et al. Chronic ischemic cerebral white matter disease is a risk factor for nonfocal neurologic injury after total aortic arch replacement. *J Thorac Cardiovasc Surg.* 2007;133:1059-65.
464. Hirose H, Svensson LG, Lytle BW, et al. Aortic dissection after previous cardiovascular surgery. *Ann Thorac Surg.* 2004;78:2099-105.
465. Svensson LG. Progress in ascending and aortic arch surgery: minimally invasive surgery, blood conservation, and neurological deficit prevention. *Ann Thorac Surg.* 2002;74:S1786-S1788.
466. Svensson LG, Nadolny EM, Penney DL, et al. Prospective randomized neurocognitive and S-100 study of hypothermic circulatory arrest, retrograde brain perfusion, and antegrade brain perfusion for aortic arch operations. *Ann Thorac Surg.* 2001;71:1905-12.
467. Safi HJ, Brien HW, Winter JN, et al. Brain protection via cerebral retrograde perfusion during aortic arch aneurysm repair. *Ann Thorac Surg.* 1993;56:270-6.
468. Estrera AL, Rubenstein FS, Miller CC III, et al. Descending thoracic aortic aneurysm: surgical approach and treatment using the adjuncts cerebrospinal fluid drainage and distal aortic perfusion. *Ann Thorac Surg.* 2001;72:481-6.
469. Matsumura JS, Cambria RP, Dake MD, et al. International controlled clinical trial of thoracic endovascular aneurysm repair with the Zenith TX2 endovascular graft: 1-year results. *J Vasc Surg.* 2008;47:247-57.
470. Svensson LG, Crawford ES, Hess KR, et al. Thoracoabdominal aortic aneurysms associated with celiac, superior mesenteric, and renal artery occlusive disease: methods and analysis of results in 271 patients. *J Vasc Surg.* 1992;16:378-89.
471. Demers P, Miller DC, Mitchell RS, et al. Midterm results of endovascular repair of descending thoracic aortic aneurysms with first-generation stent grafts. *J Thorac Cardiovasc Surg.* 2004;127:664-73.
472. Aljabri B, Al WK, Abner D, et al. Patient-reported quality of life after abdominal aortic aneurysm surgery: a prospective comparison of endovascular and open repair. *J Vasc Surg.* 2006;44:1182-7.
473. Kalef-Ezra JA, Karavasilis S, Ziogas D, et al. Radiation burden of patients undergoing endovascular abdominal aortic aneurysm repair. *J Vasc Surg.* 2009;49:283-7.
474. Gutsche JT, Cheung AT, McGarvey ML, et al. Risk factors for perioperative stroke after thoracic endovascular aortic repair. *Ann Thorac Surg.* 2007;84:1195-200.
475. Peterson BG, Eskandari MK, Gleason TG, et al. Utility of left subclavian artery revascularization in association with endoluminal repair of acute and chronic thoracic aortic pathology. *J Vasc Surg.* 2006;43:433-9.
476. Rehders TC, Petzsch M, Ince H, et al. Intentional occlusion of the left subclavian artery during stent-graft implantation in the thoracic aorta: risk and relevance. *J Endovasc Ther.* 2004;11:659-66.
477. Riesenman PJ, Farber MA, Mendes RR, et al. Coverage of the left subclavian artery during thoracic endovascular aortic repair. *J Vasc Surg.* 2007;45:90-4.
478. Jackson BM, Carpenter JP, Fairman RM, et al. Anatomic exclusion from endovascular repair of thoracic aortic aneurysm. *J Vasc Surg.* 2007;45:662-6.
479. Reece TB, Gazoni LM, Cherry KJ, et al. Reevaluating the need for left subclavian artery revascularization with thoracic endovascular aortic repair. *Ann Thorac Surg.* 2007;84:1201-5.
480. Song TK, Donayre CE, Walot I, et al. Endograft exclusion of acute and chronic descending thoracic aortic dissections. *J Vasc Surg.* 2006;43:247-58.
481. Buth J, Harris PL, Hobo R, et al. Neurologic complications associated with endovascular repair of thoracic aortic pathology: Incidence and risk factors. a study from the European Collaborators on Stent/Graft Techniques for Aortic Aneurysm Repair (EUROSTAR) registry. *J Vasc Surg.* 2007;46:1103-10.
482. Fairman RM, Criado F, Farber M, et al. Pivotal results of the Medtronic Vascular Talent Thoracic Stent Graft System: the VALOR trial. *J Vasc Surg.* 2008;48:546-54.
483. Schurink GW, Nijenhuis RJ, Backes WH, et al. Assessment of spinal cord circulation and function in endovascular treatment of thoracic aortic aneurysms. *Ann Thorac Surg.* 2007;83:S877-S881.
484. Khoynezhad A, Donayre CE, Bui H, et al. Risk factors of neurologic deficit after thoracic aortic endografting. *Ann Thorac Surg.* 2007;83:S882-S889.
485. Gravereaux EC, Faries PL, Burks JA, et al. Risk of spinal cord ischemia after endograft repair of thoracic aortic aneurysms. *J Vasc Surg.* 2001;34:997-1003.
486. Cheung AT, Pochettino A, McGarvey ML, et al. Strategies to manage paraplegia risk after endovascular stent repair of descending thoracic aortic aneurysms. *Ann Thorac Surg.* 2005;80:1280-8.
487. Resch TA, Greenberg RK, Lyden SP, et al. Combined staged procedures for the treatment of thoracoabdominal aneurysms. *J Endovasc Ther.* 2006;13:481-9.
488. Roselli EE, Greenberg RK, Pfaff K, et al. Endovascular treatment of thoracoabdominal aortic aneurysms. *J Thorac Cardiovasc Surg.* 2007;133:1474-82.
489. Flye MW, Choi ET, Sanchez LA, et al. Retrograde visceral vessel revascularization followed by endovascular aneurysm exclusion as an alternative to open surgical repair of thoracoabdominal aortic aneurysm. *J Vasc Surg.* 2004;39:454-8.
490. Barnes DM, Williams DM, Dasika NL, et al. A single-center experience treating renal malperfusion after aortic dissection with central aortic fenestration and renal artery stenting. *J Vasc Surg.* 2008;47:903-10.
491. Gorich J, Kramer S, Tomczak R, et al. Thromboembolic complications after endovascular aortic aneurysm repair. *J Endovasc Ther.* 2002;9:180-4.
492. Patel HJ, Williams DM, Upchurch GR Jr., et al. Long-term results from a 12-year experience with endovascular therapy for thoracic aortic disease. *Ann Thorac Surg.* 2006;82:2147-53.
493. W.L. Gore & Associates I. Gore TAG thoracic endoprosthesis annual clinical update. Available at: Available at: <http://www.resolutadapt.com/en/file/AK0314.pdf>. Accessed January 7, 2010.
494. Stavropoulos SW, Carpenter JP, Van den Brande P. Postoperative imaging surveillance and endoleak management after endovascular repair of thoracic aortic aneurysms. *J Vasc Surg.* 2006;43 Suppl A:89A-93A.
495. Mita T, Arita T, Matsunaga N, et al. Complications of endovascular repair for thoracic and abdominal aortic aneurysm: an imaging spectrum. *Radiographics.* 2000;20:1263-78.
496. Won JY, Suh SH, Ko HK, et al. Problems encountered during and after stent-graft treatment of aortic dissection. *J Vasc Interv Radiol.* 2006;17:271-81.
497. Zhang R, Kofidis T, Baus S, et al. Iatrogenic type A dissection after attempted stenting of a descending aortic aneurysm. *Ann Thorac Surg.* 2006;82:1523-5.
498. Bethuynne N, Bove T, Van den BP, et al. Acute retrograde aortic dissection during endovascular repair of a thoracic aortic aneurysm. *Ann Thorac Surg.* 2003;75:1967-9.
499. Nienaber CA, Kische S, Ince H. Thoracic aortic stent-graft devices: problems, failure modes, and applicability. *Semin Vasc Surg.* 2007;20:81-9.
500. Steinbauer MG, Stehr A, Pfister K, et al. Endovascular repair of proximal endograft collapse after treatment for thoracic aortic disease. *J Vasc Surg.* 2006;43:609-12.
501. Idu MM, Reekers JA, Balm R, et al. Collapse of a stent-graft following treatment of a traumatic thoracic aortic rupture. *J Endovasc Ther.* 2005;12:503-7.

502. Parmer SS, Carpenter JP, Stavropoulos SW, et al. Endoleaks after endovascular repair of thoracic aortic aneurysms. *J Vasc Surg.* 2006;44:447–52.
503. Hartung O, Alimi YS, Juhan C. Tinnitus resulting from tandem lesions of the internal carotid artery: combined extracranial endarterectomy and intrapetrous primary stenting. *J Vasc Surg.* 2004;39:679–81.
504. Leurs LJ, Bell R, Degrieck Y, et al. Endovascular treatment of thoracic aortic diseases: combined experience from the EUROSTAR and United Kingdom Thoracic Endograft registries. *J Vasc Surg.* 2004;40:670–9.
505. Preventza O, Wheatley GH III, Ramaiah VG, et al. Management of endoleaks associated with endovascular treatment of descending thoracic aortic diseases. *J Vasc Surg.* 2008;48:69–73.
506. Leon LR Jr., Rodriguez HE. Aortic endograft migration. *Perspect Vasc Surg Endovasc Ther.* 2005;17:363–73.
507. Panos A. Late retrograde aortic perforation by the uncovered part of an endograft: an increasing complication. *Hellenic J Cardiol.* 2007;48:115–6.
508. Malina M, Brunkwall J, Ivancev K, et al. Late aortic arch perforation by graft-anchoring stent: complication of endovascular thoracic aneurysm exclusion. *J Endovasc Surg.* 1998;5:274–7.
509. Fattori R, Nienaber CA, Rousseau H, et al. Results of endovascular repair of the thoracic aorta with the Talent Thoracic stent graft: the Talent Thoracic Retrospective Registry. *J Thorac Cardiovasc Surg.* 2006;132:332–9.
510. Makaroun MS, Dillavou ED, Kee ST, et al. Endovascular treatment of thoracic aortic aneurysms: results of the phase II multicenter trial of the GORE TAG thoracic endoprosthesis. *J Vasc Surg.* 2005;41:1–9.
511. Jacobs TS, Won J, Gravereaux EC, et al. Mechanical failure of prosthetic human implants: a 10-year experience with aortic stent graft devices. *J Vasc Surg.* 2003;37:16–26.
512. Bockler D, von Tengg-Kobligh H, Schumacher H, et al. Late surgical conversion after thoracic endograft failure due to fracture of the longitudinal support wire. *J Endovasc Ther.* 2005;12:98–102.
513. Silberfein EJ, Lin PH, Bush RL, et al. Aortic endograft infection due to *Pasteurella multocida* following a rabbit bite. *J Vasc Surg.* 2006;43:393–5.
514. Wheatley GH III, Gurbuz AT, Rodriguez-Lopez JA, et al. Midterm outcome in 158 consecutive Gore TAG thoracic endoprostheses: single center experience. *Ann Thorac Surg.* 2006;81:1570–7.
515. Parra JR, Lee C, Hodgson KJ, et al. Endograft infection leading to rupture of aortic aneurysm. *J Vasc Surg.* 2004;39:676–8.
516. Eggebrecht H, Nienaber CA, Neuhauser M, et al. Endovascular stent-graft placement in aortic dissection: a meta-analysis. *Eur Heart J.* 2006;27:489–98.
517. Bockler D, Schumacher H, Ganten M, et al. Complications after endovascular repair of acute symptomatic and chronic expanding Stanford type B aortic dissections. *J Thorac Cardiovasc Surg.* 2006;132:361–8.
518. Endovascular aneurysm repair versus open repair in patients with abdominal aortic aneurysm (EVAR trial 1): randomised controlled trial. *Lancet.* 2005;365:2179–86.
519. Blankensteijn JD, de Jong SE, Prinssen M, et al. Two-year outcomes after conventional or endovascular repair of abdominal aortic aneurysms. *N Engl J Med.* 2005;352:2398–405.
520. Cambria RP, Davison JK, Carter C, et al. Epidural cooling for spinal cord protection during thoracoabdominal aneurysm repair: a five-year experience. *J Vasc Surg.* 2000;31:1093–102.
521. Coselli JS, Conklin LD, Lemaire SA. Thoracoabdominal aortic aneurysm repair: review and update of current strategies. *Ann Thorac Surg.* 2002;74:S1881–S1884.
522. Coselli JS, Lemaire SA, Koksoy C, et al. Cerebrospinal fluid drainage reduces paraplegia after thoracoabdominal aortic aneurysm repair: results of a randomized clinical trial. *J Vasc Surg.* 2002;35:631–9.
523. Safi HJ, Miller CC III, Huynh TT, et al. Distal aortic perfusion and cerebrospinal fluid drainage for thoracoabdominal and descending thoracic aortic repair: ten years of organ protection. *Ann Surg.* 2003;238:372–80.
524. Svensson LG, Crawford ES, Patel V, et al. Spinal oxygenation, blood supply localization, cooling, and function with aortic clamping. *Ann Thorac Surg.* 1992;54:74–9.
525. Svensson LG, Khitin L, Nadolny EM, et al. Systemic temperature and paralysis after thoracoabdominal and descending aortic operations. *Arch Surg.* 2003;138:175–9.
526. Svensson LG. Paralysis after aortic surgery: in search of lost cord function. *Surgeon.* 2005;3:396–405.
527. Martens S, Neumann K, Sodemann C, et al. Carbon dioxide field flooding reduces neurologic impairment after open heart surgery. *Ann Thorac Surg.* 2008;85:543–7.
528. Nadolny EM, Svensson LG. Carbon dioxide field flooding techniques for open heart surgery: monitoring and minimizing potential adverse effects. *Perfusion.* 2000;15:151–3.
529. Miller DC, Mitchell RS, Oyer PE, et al. Independent determinants of operative mortality for patients with aortic dissections. *Circulation.* 1984;70:1153–1164.
530. Lauterbach SR, Cambria RP, Brewster DC, et al. Contemporary management of aortic branch compromise resulting from acute aortic dissection. *J Vasc Surg.* 2001;33:1185–92.
531. Girardi LN, Krieger KH, Lee LY, et al. Management strategies for type A dissection complicated by peripheral vascular malperfusion. *Ann Thorac Surg.* 2004;77:1309–14.
532. Deeb GM, Williams DM, Bolling SF, et al. Surgical delay for acute type A dissection with malperfusion. *Ann Thorac Surg.* 1997;64:1669–75.
533. Hsu RB, Ho YL, Chen RJ, et al. Outcome of medical and surgical treatment in patients with acute type B aortic dissection. *Ann Thorac Surg.* 2005;79:790–4.
534. Pacini L, Digne F, Boumendil A, et al. Maternal complication of pregnancy in Marfan syndrome. *Int J Cardiol.* 2009;136:156–61.
535. Strickland RA, Oliver WC Jr., Chantigian RC, et al. Anesthesia, cardiopulmonary bypass, and the pregnant patient. *Mayo Clin Proc.* 1991;66:411–29.
536. Williams GM, Gott VL, Brawley RK, et al. Aortic disease associated with pregnancy. *J Vasc Surg.* 1988;8:470–5.
537. Immer FF, Bansi AG, Immer-Bansi AS, et al. Aortic dissection in pregnancy: analysis of risk factors and outcome. *Ann Thorac Surg.* 2003;76:309–14.
538. Lind J, Wallenburg HC. The Marfan syndrome and pregnancy: a retrospective study in a Dutch population. *Eur J Obstet Gynecol Reprod Biol.* 2001;98:28–35.
539. Erbel R, Alfonso F, Boileau C, et al. Diagnosis and management of aortic dissection. *Eur Heart J.* 2001;22:1642–81.
540. Tunick PA, Nayar AC, Goodkin GM, et al. Effect of treatment on the incidence of stroke and other emboli in 519 patients with severe thoracic aortic plaque. *Am J Cardiol.* 2002;90:1320–5.
541. Amarenco P, Duyckaerts C, Tzourio C, et al. The prevalence of ulcerated plaques in the aortic arch in patients with stroke. *N Engl J Med.* 1992;326:221–5.
542. Khatibzadeh M, Mitusch R, Stierle U, et al. Aortic atherosclerotic plaques as a source of systemic embolism. *J Am Coll Cardiol.* 1996;27:664–9.
543. Amarenco P, Cohen A, Tzourio C, et al. Atherosclerotic disease of the aortic arch and the risk of ischemic stroke. *N Engl J Med.* 1994;331:1474–9.
544. Jones EF, Kalman JM, Calafiore P, et al. Proximal aortic atheroma. An independent risk factor for cerebral ischemia. *Stroke.* 1995;26:218–24.
545. Stern A, Tunick PA, Culliford AT, et al. Protruding aortic arch atheromas: risk of stroke during heart surgery with and without aortic arch endarterectomy. *Am Heart J.* 1999;138:746–52.
546. Nihoyannopoulos P, Joshi J, Athanopoulos G, et al. Detection of atherosclerotic lesions in the aorta by transesophageal echocardiography. *Am J Cardiol.* 1993;71:1208–12.
547. Stone DH, Brewster DC, Kwolek CJ, et al. Stent-graft versus open-surgical repair of the thoracic aorta: mid-term results. *J Vasc Surg.* 2006;44:1188–97.
548. Di Tullio MR, Sacco RL, Gersony D, et al. Aortic atheromas and acute ischemic stroke: a transesophageal echocardiographic study in an ethnically mixed population. *Neurology.* 1996;46:1560–6.
549. Davila-Roman VG, Barzilay B, Wareing TH, et al. Atherosclerosis of the ascending aorta. Prevalence and role as an independent predictor of cerebrovascular events in cardiac patients. *Stroke.* 1994;25:2010–6.
550. The French Study of Aortic Plaques in Stroke Group. Atherosclerotic disease of the aortic arch as a risk factor for recurrent ischemic stroke. *N Engl J Med.* 1996;334:1216–21.
551. Tunick PA, Rosenzweig BP, Katz ES, et al. High risk for vascular events in patients with protruding aortic atheromas: a prospective study. *J Am Coll Cardiol.* 1994;23:1085–90.
552. Mitusch R, Doherty C, Wucherpfennig H, et al. Vascular events during follow-up in patients with aortic arch atherosclerosis. *Stroke.* 1997;28:36–9.

553. Davila-Roman VG, Murphy SF, Nickerson NJ, et al. Atherosclerosis of the ascending aorta is an independent predictor of long-term neurologic events and mortality. *J Am Coll Cardiol*. 1999;33:1308–16.
554. Cohen A, Tzourio C, Bertrand B, et al. Aortic plaque morphology and vascular events: a follow-up study in patients with ischemic stroke. FAPS Investigators French Study of Aortic Plaques in Stroke. *Circulation*. 1997;96:3838–41.
555. Sen S, Oppenheimer SM, Lima J, et al. Risk factors for progression of aortic atheroma in stroke and transient ischemic attack patients. *Stroke*. 2002;33:930–5.
556. Montgomery DH, Verwer JJ, McGorisk G, et al. Natural history of severe atheromatous disease of the thoracic aorta: a transesophageal echocardiographic study. *J Am Coll Cardiol*. 1996;27:95–101.
557. Pitsavos CE, Aggeli KI, Barbetseas JD, et al. Effects of pravastatin on thoracic aortic atherosclerosis in patients with heterozygous familial hypercholesterolemia. *Am J Cardiol*. 1998;82:1484–8.
558. Geraci A, Weinberger J. Natural history of aortic arch atherosclerotic plaque. *Neurology*. 2000;54:749–51.
559. Sen S, Hinderliter A, Sen PK, et al. Aortic arch atheroma progression and recurrent vascular events in patients with stroke or transient ischemic attack. *Circulation*. 2007;116:928–35.
560. Agmon Y, Khandheria BK, Meissner I, et al. Independent association of high blood pressure and aortic atherosclerosis: a population-based study. *Circulation*. 2000;102:2087–93.
561. Tsimikas S, Brilakis ES, Miller ER, et al. Oxidized phospholipids, Lp(a) lipoprotein, and coronary artery disease. *N Engl J Med*. 2005;353:46–57.
562. The Stroke Prevention in Atrial Fibrillation Investigators Committee on Echocardiography. Transesophageal echocardiographic correlates of thromboembolism in high-risk patients with nonvalvular atrial fibrillation. *Ann Intern Med*. 1998;128:639–47.
563. Deleted in proof.
564. Agmon Y, Khandheria BK, Meissner I, et al. C-reactive protein and atherosclerosis of the thoracic aorta: a population-based transesophageal echocardiographic study. *Arch Intern Med*. 2004;164:1781–7.
565. Konecky N, Malinow MR, Tunick PA, et al. Correlation between plasma homocyst(e)ine and aortic atherosclerosis. *Am Heart J*. 1997;133:534–40.
566. Kronzon I, Tunick PA. Aortic atherosclerotic disease and stroke. *Circulation*. 2006;114:63–75.
567. Zaidat OO, Suarez JI, Hedrick D, et al. Reproducibility of transesophageal echocardiography in evaluating aortic atheroma in stroke patients. *Echocardiography*. 2005;22:326–30.
568. Tenenbaum A, Garniek A, Shemesh J, et al. Dual-helical CT for detecting aortic atheromas as a source of stroke: comparison with transesophageal echocardiography. *Radiology*. 1998;208:153–8.
569. Blanchard DG, Kimura BJ, Dittrich HC, et al. Transesophageal echocardiography of the aorta. *JAMA*. 1994;272:546–51.
570. Weinberger J, Azhar S, Danisi F, et al. A new noninvasive technique for imaging atherosclerotic plaque in the aortic arch of stroke patients by transcutaneous real-time B-mode ultrasonography: an initial report. *Stroke*. 1998;29:673–6.
571. Schwammenthal E, Schwammenthal Y, Tanne D, et al. Transcutaneous detection of aortic arch atheromas by suprasternal harmonic imaging. *J Am Coll Cardiol*. 2002;39:1127–32.
572. Gottsegen JM, Coplan NL. The atherosclerotic aortic arch: considerations in diagnostic imaging. *Prev Cardiol*. 2008;11:162–7.
573. Wareing TH, Davila-Roman VG, Barzilay B, et al. Management of the severely atherosclerotic ascending aorta during cardiac operations. A strategy for detection and treatment. *J Thorac Cardiovasc Surg*. 1992;103:453–62.
574. Khatri IA, Mian N, Alkawi A, et al. Catheter-based aortography fails to identify aortic atherosclerotic lesions detected on transesophageal echocardiography. *J Neuroimaging*. 2005;15:261–5.
575. Corti R. Noninvasive imaging of atherosclerotic vessels by MRI for clinical assessment of the effectiveness of therapy. *Pharmacol Ther*. 2006;110:57–70.
576. Kronzon I. Protruding aortic atheroma: is there a need for a new imaging modality? *Isr Med Assoc J*. 2000;2:54–5.
577. Tahara N, Kai H, Ishibashi M, et al. Simvastatin attenuates plaque inflammation: evaluation by fluorodeoxyglucose positron emission tomography. *J Am Coll Cardiol*. 2006;48:1825–31.
578. Hausmann D, Gulba D, Bargheer K, et al. Successful thrombolysis of an aortic-arch thrombus in a patient after mesenteric embolism. *N Engl J Med*. 1992;327:500–1.
579. Dahlberg PJ, Frecentese DF, Cogbill TH. Cholesterol embolism: experience with 22 histologically proven cases. *Surgery*. 1989;105:737–46.
580. Bruns FJ, Segel DP, Adler S. Control of cholesterol embolization by discontinuation of anticoagulant therapy. *Am J Med Sci*. 1978;275:105–8.
581. Hyman BT, Landas SK, Ashman RF, et al. Warfarin-related purple toes syndrome and cholesterol microembolization. *Am J Med*. 1987;82:1233–7.
582. Blackshear JL, Jahangir A, Oldenburg WA, et al. Digital embolization from plaque-related thrombus in the thoracic aorta: identification with transesophageal echocardiography and resolution with warfarin therapy. *Mayo Clin Proc*. 1993;68:268–72.
583. Koppang JR, Nanda NC, Coghlan HC, et al. Histologically Confirmed Cholesterol Atheroemboli with Identification of the Source by Transesophageal Echocardiography. *Echocardiography*. 1992;9:379–83.
584. Deleted in proof.
585. Tunick PA, Culliford AT, Lamparello PJ, et al. Atheromatosis of the aortic arch as an occult source of multiple systemic emboli. *Ann Intern Med*. 1991;114:391–2.
586. Ferrari E, Vidal R, Chevallier T, et al. Atherosclerosis of the thoracic aorta and aortic debris as a marker of poor prognosis: benefit of oral anticoagulants. *J Am Coll Cardiol*. 1999;33:1317–22.
587. Corti R, Fuster V, Fayad ZA, et al. Effects of aggressive versus conventional lipid-lowering therapy by simvastatin on human atherosclerotic lesions: a prospective, randomized, double-blind trial with high-resolution magnetic resonance imaging. *J Am Coll Cardiol*. 2005;46:106–12.
588. Yonemura A, Momiyama Y, Fayad ZA, et al. Effect of lipid-lowering therapy with atorvastatin on atherosclerotic aortic plaques detected by non-invasive magnetic resonance imaging. *J Am Coll Cardiol*. 2005;45:733–42.
589. Goldstein LB, Adams R, Alberts MJ, et al. Primary prevention of ischemic stroke: a guideline from the American Heart Association/American Stroke Association Stroke Council: cosponsored by the Atherosclerotic Peripheral Vascular Disease Interdisciplinary Working Group; Cardiovascular Nursing Council; Clinical Cardiology Council; Nutrition, Physical Activity, and Metabolism Council; and the Quality of Care and Outcomes Research Interdisciplinary Working Group. *Circulation*. 2006;113:e873–e923.
590. Sacco RL, Adams R, Albers G, et al. Guidelines for prevention of stroke in patients with ischemic stroke or transient ischemic attack: a statement for healthcare professionals from the American Heart Association/American Stroke Association Council on Stroke: co-sponsored by the Council on Cardiovascular Radiology and Intervention; the American Academy of Neurology affirms the value of this guideline. *Stroke*. 2006;37:577–617.
591. Bar-El Y, Goor DA. Clamping of the atherosclerotic ascending aorta during coronary artery bypass operations. Its cost in strokes. *J Thorac Cardiovasc Surg*. 1992;104:469–74.
592. Cosgrove DM. Management of the calcified aorta: an alternative method of occlusion. *Ann Thorac Surg*. 1983;36:718–9.
593. Grossi EA, Kanchuger MS, Schwartz DS, et al. Effect of cannula length on aortic arch flow: protection of the atheromatous aortic arch. *Ann Thorac Surg*. 1995;59:710–2.
594. Mills NL, Everson CT. Atherosclerosis of the ascending aorta and coronary artery bypass. Pathology, clinical correlates, and operative management. *J Thorac Cardiovasc Surg*. 1991;102:546–53.
595. Peigh PS, DiSesa VJ, Collins JJ, Jr., et al. Coronary bypass grafting with totally calcified or acutely dissected ascending aorta. *Ann Thorac Surg*. 1991;51:102–4.
596. Rokkas CK, Kouchoukos NT. Surgical management of the severely atherosclerotic ascending aorta during cardiac operations. *Semin Thorac Cardiovasc Surg*. 1998;10:240–6.
597. Wimmer-Greinecker G. Reduction of neurologic complications by intra-aortic filtration in patients undergoing combined intracardiac and CABG procedures. *Eur J Cardiothorac Surg*. 2003;23:159–64.
598. Girardi LN, Krieger KH, Mack CA, et al. No-clamp technique for valve repair or replacement in patients with a porcelain aorta. *Ann Thorac Surg*. 2005;80:1688–92.
599. Aranki SF, Nathan M, Shekar P, et al. Hypothermic circulatory arrest enables aortic valve replacement in patients with unclampable aorta. *Ann Thorac Surg*. 2005;80:1679–86.
600. Deslauriers J, Gregoire J. Clinical and surgical staging of non-small cell lung cancer. *Chest*. 2000;117:96S–103S.
601. Kameda K, Adachi S, Kono M. Detection of T-factor in lung cancer using magnetic resonance imaging and computed tomography. *J Thorac Imaging*. 1988;3:73–80.

602. Ohtsuka T, Minami M, Nakajima J, et al. Cine computed tomography for evaluation of tumors invasive to the thoracic aorta: seven clinical experiences. *J Thorac Cardiovasc Surg.* 1996;112:190–2.
603. Schroder C, Schonhofer B, Vogel B. Transesophageal echographic determination of aortic invasion by lung cancer. *Chest.* 2005;127:438–42.
604. Oldenburg WA. *Primary Tumors of Major Blood Vessels.* 6th ed. Philadelphia: Elsevier Saunders, 2005.
605. Chen WJ, Chen CL, Liau CS, et al. Primary malignant fibrous histiocytoma of the aorta associated with aortic dissection. *Chest.* 1991;99:1049–50.
606. Utsunomiya D, Ikeda O, Ideta I, et al. Malignant fibrous histiocytoma arising from the aortic wall mimicking a pseudoaneurysm with ulceration. *Circ J.* 2007;71:1659–61.
607. Guttentag A, Lazar HL, Franklin P, et al. Malignant fibrous histiocytoma obstructing the thoracic aorta. *Ann Thorac Surg.* 1989;47:775–7.
608. Kouchoukos NT, Masetti P. Primary sarcoma of the thoracic aorta. *Ann Thorac Surg.* 2007;83:e1.
609. Boden WE, O'Rourke RA, Teo KK, et al. Optimal medical therapy with or without PCI for stable coronary disease. *N Engl J Med.* 2007;356:1503–16.
610. McFalls EO, Ward HB, Moritz TE, et al. Coronary-artery revascularization before elective major vascular surgery. *N Engl J Med.* 2004;351:2795–804.
611. Poldermans D, Schouten O, Vidakovic R, et al. A clinical randomized trial to evaluate the safety of a noninvasive approach in high-risk patients undergoing major vascular surgery: the DECREASE-V Pilot Study. *J Am Coll Cardiol.* 2007;49:1763–9.
612. Heng AE, Cellarier E, ublet-Cuvelier B, et al. Is treatment with N-acetylcysteine to prevent contrast-induced nephropathy when using bicarbonate hydration out of date? *Clin Nephrol.* 2008;70:475–84.
613. Nigwekar SU, Kandula P. N-Acetylcysteine in cardiovascular-surgery-associated renal failure: a meta-analysis. *Ann Thorac Surg.* 2009;87:139–47.
614. Juvonen T, Ergin MA, Galla JD, et al. Prospective study of the natural history of thoracic aortic aneurysms. *Ann Thorac Surg.* 1997;63:1533–45.
615. Svensson LG, Crawford ES, Hess KR, et al. Deep hypothermia with circulatory arrest. Determinants of stroke and early mortality in 656 patients. *J Thorac Cardiovasc Surg.* 1993;106:19–28.
616. Cain HD, Stevens PM, Adaniya R. Preoperative pulmonary function and complications after cardiovascular surgery. *Chest.* 1979;76:130–5.
617. Safi HJ, Harlin SA, Miller CC, et al. Predictive factors for acute renal failure in thoracic and thoracoabdominal aortic aneurysm surgery. *J Vasc Surg.* 1996;24:338–44.
618. Eagle KA, Rihal CS, Mickel MC, et al. Cardiac risk of noncardiac surgery: influence of coronary disease and type of surgery in 3368 operations. CASS Investigators and University of Michigan Heart Care Program. *Coronary Artery Surgery Study.* *Circulation.* 1997;96:1882–7.
619. Hertzner NR, Beven EG, Young JR, et al. Coronary artery disease in peripheral vascular patients. A classification of 1000 coronary angiograms and results of surgical management. *Ann Surg.* 1984;199:223–33.
620. Hertzner NR, Young JR, Beven EG, et al. Late results of coronary bypass in patients with peripheral vascular disease. I. Five-year survival according to age and clinical cardiac status. *Cleve Clin Q.* 1986;53:133–43.
621. Hertzner NR, Young JR, Beven EG, et al. Late results of coronary bypass in patients with peripheral vascular disease. II. Five-year survival according to sex, hypertension, and diabetes. *Cleve Clin J Med.* 1987;54:15–23.
622. Rihal CS, Eagle KA, Mickel MC, et al. Surgical therapy for coronary artery disease among patients with combined coronary artery and peripheral vascular disease. *Circulation.* 1995;91:46–53.
623. Fleisher LA, Beckman JA, Brown KA, et al. ACC/AHA 2006 guideline update on perioperative cardiovascular evaluation for noncardiac surgery. *Circulation.* 2006;113:2662–74.
624. Svensson LG, Hess KR, Coselli JS, et al. A prospective study of respiratory failure after high-risk surgery on the thoracoabdominal aorta. *J Vasc Surg.* 1991;14:271–82.
625. Kashyap VS, Cambria RP, Davison JK, et al. Renal failure after thoracoabdominal aortic surgery. *J Vasc Surg.* 1997;26:949–55.
626. Svensson LG, Coselli JS, Safi HJ, et al. Appraisal of adjuncts to prevent acute renal failure after surgery on the thoracic or thoracoabdominal aorta. *J Vasc Surg.* 1989;10:230–9.
627. Berens ES, Kouchoukos NT, Murphy SF, et al. Preoperative carotid artery screening in elderly patients undergoing cardiac surgery. *J Vasc Surg.* 1992;15:313–21.
628. Crawford ES, Svensson LG, Coselli JS, et al. Surgical treatment of aneurysm and/or dissection of the ascending aorta, transverse aortic arch, and ascending aorta and transverse aortic arch. Factors influencing survival in 717 patients. *J Thorac Cardiovasc Surg.* 1989;98:659–73.
629. Coselli JS, Lemaire SA, Miller CC III, et al. Mortality and paraplegia after thoracoabdominal aortic aneurysm repair: a risk factor analysis. *Ann Thorac Surg.* 2000;69:409–14.
630. Kouchoukos NT, Masetti P, Rokkas CK, et al. Safety and efficacy of hypothermic cardiopulmonary bypass and circulatory arrest for operations on the descending thoracic and thoracoabdominal aorta. *Ann Thorac Surg.* 2001;72:699–707.
631. Practice guidelines for perioperative transesophageal echocardiography. A report by the American Society of Anesthesiologists and the Society of Cardiovascular Anesthesiologists Task Force on Transesophageal Echocardiography. *Anesthesiology.* 1996;84:986–1006.
632. Fattori R, Calderara I, Rapezzi C, et al. Primary endoleakage in endovascular treatment of the thoracic aorta: importance of intraoperative transesophageal echocardiography. *J Thorac Cardiovasc Surg.* 2000;120:490–5.
633. Abe S, Ono S, Murata K, et al. Usefulness of transesophageal echocardiographic monitoring in transluminal endovascular stent-graft repair for thoracic aortic aneurysm. *Jpn Circ J.* 2000;64:960–4.
634. Dong CC, MacDonald DB, Janusz MT. Intraoperative spinal cord monitoring during descending thoracic and thoracoabdominal aneurysm surgery. *Ann Thorac Surg.* 2002;74:S1873–S1876.
635. Meylaerts SA, Jacobs MJ, van Iterson V, et al. Comparison of transcranial motor evoked potentials and somatosensory evoked potentials during thoracoabdominal aortic aneurysm repair. *Ann Surg.* 1999;230:742–9.
636. Horlocker TT, Wedel DJ, Benzon H, et al. Regional anesthesia in the anticoagulated patient: defining the risks (the second ASRA Consensus Conference on Neuraxial Anesthesia and Anticoagulation). *Reg Anesth Pain Med.* 2003;28:172–97.
637. Aadahl P, Lundbom J, Hatlinghus S, et al. Regional anesthesia for endovascular treatment of abdominal aortic aneurysms. *J Endovasc Surg.* 1997;4:56–61.
638. Kim SS, Leibowitz AB. Endovascular thoracic aortic aneurysm repair using a single catheter for spinal anesthesia and cerebrospinal fluid drainage. *J Cardiothorac Vasc Anesth.* 2001;15:88–9.
639. Henretta JP, Hodgson KJ, Mattos MA, et al. Feasibility of endovascular repair of abdominal aortic aneurysms with local anesthesia with intravenous sedation. *J Vasc Surg.* 1999;29:793–8.
640. Mathes DD, Kern JA. Continuous spinal anesthetic technique for endovascular aortic stent graft surgery. *J Clin Anesth.* 2000;12:487–90.
641. Lachat M, Pfammatter T, Turina M. Transfemoral endografting of thoracic aortic aneurysm under local anesthesia: a simple, safe and fast track procedure. *Vasa.* 1999;28:204–6.
642. Bettex DA, Lachat M, Pfammatter T, et al. To compare general, epidural and local anaesthesia for endovascular aneurysm repair (EVAR). *Eur J Vasc Endovasc Surg.* 2001;21:179–84.
643. Verhoeven EL, Cina CS, Tielliu IF, et al. Local anesthesia for endovascular abdominal aortic aneurysm repair. *J Vasc Surg.* 2005;42:402–9.
644. Ruppert V, Leurs LJ, Steckmeier B, et al. Influence of anesthesia type on outcome after endovascular aortic aneurysm repair: an analysis based on EUROSTAR data. *J Vasc Surg.* 2006;44:16–21.
645. Stone JG, Young WL, Smith CR, et al. Do standard monitoring sites reflect true brain temperature when profound hypothermia is rapidly induced and reversed? *Anesthesiology.* 1995;82:344–51.
646. Pronovost P, Needham D, Berenholtz S, et al. An intervention to decrease catheter-related bloodstream infections in the ICU. *N Engl J Med.* 2006;355:2725–32.
647. Merrer J, De JB, Golliot F, et al. Complications of femoral and subclavian venous catheterization in critically ill patients: a randomized controlled trial. *JAMA.* 2001;286:700–7.
648. Daniel WG, Erbel R, Kasper W, et al. Safety of transesophageal echocardiography. A multicenter survey of 10,419 examinations. *Circulation.* 1991;83:817–21.
649. Moskowitz DM, Kahn RA, Konstadt SN, et al. Intraoperative transesophageal echocardiography as an adjuvant to fluoroscopy during endovascular thoracic aortic repair. *Eur J Vasc Endovasc Surg.* 1999;17:22–7.
650. Orihashi K, Matsuura Y, Sueda T, et al. Echocardiography-assisted surgery in transaortic endovascular stent grafting: role of transesophageal echocardiography. *J Thorac Cardiovasc Surg.* 2000;120:672–8.
651. Campos JH, Massa FC, Kernstine KH. The incidence of right upper-lobe collapse when comparing a right-sided double-lumen tube versus a modified left double-lumen tube for left-sided thoracic surgery. *Anesth Analg.* 2000;90:535–40.

652. Ferraris VA, Ferraris SP, Saha SP, et al. Perioperative blood transfusion and blood conservation in cardiac surgery: the Society of Thoracic Surgeons and The Society of Cardiovascular Anesthesiologists clinical practice guideline. *Ann Thorac Surg.* 2007;83:S27–S86.
653. Illig KA, Green RM, Ouriel K, et al. Primary fibrinolysis during supraceliac aortic clamping. *J Vasc Surg.* 1997;25:244–51.
654. Cohen JR, Schroder W, Leal J, et al. Mesenteric shunting during thoracoabdominal aortic clamping to prevent disseminated intravascular coagulation in dogs. *Ann Vasc Surg.* 1988;2:261–7.
655. Schneiderman J, Eguchi Y, Adar R, et al. Modulation of the fibrinolytic system by major peripheral ischemia. *J Vasc Surg.* 1994;19:516–24.
656. Welch M, Douglas JT, Smyth JV, et al. Systemic endotoxaemia and fibrinolysis during aortic surgery. *Eur J Vasc Endovasc Surg.* 1995;9:228–32.
657. Henry DA, Carless PA, Moxey AJ, et al. Anti-fibrinolytic use for minimising perioperative allogeneic blood transfusion. *John Wiley & Sons, Ltd.* Available at: <http://www.mrw.interscience.wiley.com/cochrane/clsysrev/articles/CD001886/frame.html>. Accessed January 7, 2010.
658. Fiechtner BK, Nuttall GA, Johnson ME, et al. Plasma tranexamic acid concentrations during cardiopulmonary bypass. *Anesth Analg.* 2001;92:1131–6.
659. Shore-Lesserson L, Bodian C, Vela-Cantos F, et al. Antifibrinolytic use and bleeding during surgery on the descending thoracic aorta: a multivariate analysis. *J Cardiothorac Vasc Anesth.* 2005;19:453–8.
660. Akashi H, Tayama K, Fujino T, et al. Cerebral protection selection in aortic arch surgery for patients with preoperative complications of cerebrovascular disease. *Jpn J Thorac Cardiovasc Surg.* 2000;48:782–8.
661. Ehrlich MP, Fang WC, Grabenwoger M, et al. Impact of retrograde cerebral perfusion on aortic arch aneurysm repair. *J Thorac Cardiovasc Surg.* 1999;118:1026–32.
662. Di Eusanio M, Wesselink RM, Morshuis WJ, et al. Deep hypothermic circulatory arrest and antegrade selective cerebral perfusion during ascending aorta-hemiarch replacement: a retrospective comparative study. *J Thorac Cardiovasc Surg.* 2003;125:849–54.
663. Hagl C, Ergin MA, Galla JD, et al. Neurologic outcome after ascending aorta-aortic arch operations: effect of brain protection technique in high-risk patients. *J Thorac Cardiovasc Surg.* 2001;121:1107–21.
664. Reich DL, Uysal S, Sliwinski M, et al. Neuropsychologic outcome after deep hypothermic circulatory arrest in adults. *J Thorac Cardiovasc Surg.* 1999;117:156–63.
665. Reich DL, Uysal S, Ergin MA, et al. Retrograde cerebral perfusion during thoracic aortic surgery and late neuropsychological dysfunction. *Eur J Cardiothorac Surg.* 2001;19:594–600.
666. Usui A, Yasuura K, Watanabe T, et al. Comparative clinical study between retrograde cerebral perfusion and selective cerebral perfusion in surgery for acute type A aortic dissection. *Eur J Cardiothorac Surg.* 1999;15:571–8.
667. Kuniyama T, Grun T, Aicher D, et al. Hypothermic circulatory arrest is not a risk factor for neurologic morbidity in aortic surgery: a propensity score analysis. *J Thorac Cardiovasc Surg.* 2005;130:712–8.
668. Schepens MA, Dossche KM, Morshuis WJ, et al. The elephant trunk technique: operative results in 100 consecutive patients. *Eur J Cardiothorac Surg.* 2002;21:276–81.
669. Deeb GM, Williams DM, Quint LE, et al. Risk analysis for aortic surgery using hypothermic circulatory arrest with retrograde cerebral perfusion. *Ann Thorac Surg.* 1999;67:1883–6.
670. Ehrlich MP, Schillinger M, Grabenwoger M, et al. Predictors of adverse outcome and transient neurological dysfunction following surgical treatment of acute type A dissections. *Circulation.* 2003;108(suppl 1):II318–II323.
671. Fleck TM, Czerny M, Hutschala D, et al. The incidence of transient neurologic dysfunction after ascending aortic replacement with circulatory arrest. *Ann Thorac Surg.* 2003;76:1198–202.
672. Moshkovitz Y, David TE, Caleb M, et al. Circulatory arrest under moderate systemic hypothermia and cold retrograde cerebral perfusion. *Ann Thorac Surg.* 1998;66:1179–84.
673. Okita Y, Takamoto S, Ando M, et al. Mortality and cerebral outcome in patients who underwent aortic arch operations using deep hypothermic circulatory arrest with retrograde cerebral perfusion: no relation of early death, stroke, and delirium to the duration of circulatory arrest. *J Thorac Cardiovasc Surg.* 1998;115:129–38.
674. Ueda Y, Okita Y, Aomi S, et al. Retrograde cerebral perfusion for aortic arch surgery: analysis of risk factors. *Ann Thorac Surg.* 1999;67:1879–82.
675. Wong CH, Bonser RS. Does retrograde cerebral perfusion affect risk factors for stroke and mortality after hypothermic circulatory arrest? *Ann Thorac Surg.* 1999;67:1900–3.
676. Di Eusanio M, Schepens MA, Morshuis WJ, et al. Brain protection using antegrade selective cerebral perfusion: a multicenter study. *Ann Thorac Surg.* 2003;76:1181–8.
677. Di Eusanio M, Schepens MA, Morshuis WJ, et al. Antegrade selective cerebral perfusion during operations on the thoracic aorta: factors influencing survival and neurologic outcome in 413 patients. *J Thorac Cardiovasc Surg.* 2002;124:1080–6.
678. Di Eusanio M, Tan ME, Schepens MA, et al. Surgery for acute type A dissection using antegrade selective cerebral perfusion: experience with 122 patients. *Ann Thorac Surg.* 2003;75:514–9.
679. Kazui T, Yamashita K, Washiyama N, et al. Impact of an aggressive surgical approach on surgical outcome in type A aortic dissection. *Ann Thorac Surg.* 2002;74:S1844–S1847.
680. Kazui T, Yamashita K, Washiyama N, et al. Aortic arch replacement using selective cerebral perfusion. *Ann Thorac Surg.* 2007;83:S796–S798.
681. Numata S, Ogino H, Sasaki H, et al. Total arch replacement using antegrade selective cerebral perfusion with right axillary artery perfusion. *Eur J Cardiothorac Surg.* 2003;23:771–5.
682. Sasaki H, Ogino H, Matsuda H, et al. Integrated total arch replacement using selective cerebral perfusion: a 6-year experience. *Ann Thorac Surg.* 2007;83:S805–S810.
683. Strauch JT, Spielvogel D, Lauten A, et al. Axillary artery cannulation: routine use in ascending aorta and aortic arch replacement. *Ann Thorac Surg.* 2004;78:103–8.
684. Kamiya H, Hagl C, Kropivnitskaya I, et al. Quick proximal arch replacement with moderate hypothermic circulatory arrest. *Ann Thorac Surg.* 2007;83:1055–8.
685. Matalanis G, Hata M, Buxton BF. A retrospective comparative study of deep hypothermic circulatory arrest, retrograde, and antegrade cerebral perfusion in aortic arch surgery. *Ann Thorac Cardiovasc Surg.* 2003;9:174–9.
686. Okita Y, Minatoya K, Tagusari O, et al. Prospective comparative study of brain protection in total aortic arch replacement: deep hypothermic circulatory arrest with retrograde cerebral perfusion or selective antegrade cerebral perfusion. *Ann Thorac Surg.* 2001;72:72–9.
687. Zierer A, Aybek T, Risteski P, et al. Moderate hypothermia (30 degrees C) for surgery of acute type A aortic dissection. *Thorac Cardiovasc Surg.* 2005;53:74–9.
688. Okita Y, Ando M, Minatoya K, et al. Predictive factors for mortality and cerebral complications in arteriosclerotic aneurysm of the aortic arch. *Ann Thorac Surg.* 1999;67:72–8.
689. Grigore AM, Grocott HP, Mathew JP, et al. The rewarming rate and increased peak temperature alter neurocognitive outcome after cardiac surgery. *Anesth Analg.* 2002;94:4–10, table.
690. Grocott HP, Mackensen GB, Grigore AM, et al. Postoperative hyperthermia is associated with cognitive dysfunction after coronary artery bypass graft surgery. *Stroke.* 2002;33:537–41.
691. Bar-Yosef S, Mathew JP, Newman MF, et al. Prevention of cerebral hyperthermia during cardiac surgery by limiting on-bypass rewarming in combination with post-bypass body surface warming: a feasibility study. *Anesth Analg.* 2004;99:641–6, table.
692. Chong SY, Chow MY, Kang DS, et al. Deep hypothermic circulatory arrest in adults undergoing aortic surgery: local experience. *Ann Acad Med Singapore.* 2004;33:289–93.
693. Gega A, Rizzo JA, Johnson MH, et al. Straight deep hypothermic arrest: experience in 394 patients supports its effectiveness as a sole means of brain preservation. *Ann Thorac Surg.* 2007;84:759–66.
694. Bavaria JE, Pochettino A, Brinster DR, et al. New paradigms and improved results for the surgical treatment of acute type A dissection. *Ann Surg.* 2001;234:336–42.
695. Bonser RS, Wong CH, Harrington D, et al. Failure of retrograde cerebral perfusion to attenuate metabolic changes associated with hypothermic circulatory arrest. *J Thorac Cardiovasc Surg.* 2002;123:943–50.
696. Cheung AT, Bavaria JE, Pochettino A, et al. Oxygen delivery during retrograde cerebral perfusion in humans. *Anesth Analg.* 1999;88:8–15.
697. Estrera AL, Miller CC III, Huynh TT, et al. Replacement of the ascending and transverse aortic arch: determinants of long-term survival. *Ann Thorac Surg.* 2002;74:1058–64.
698. Lemaire SA, Bhamra JK, Schmittling ZC, et al. S100beta correlates with neurologic complications after aortic operation using circulatory arrest. *Ann Thorac Surg.* 2001;71:1913–8.



699. Moon MR, Sundt TM III. Influence of retrograde cerebral perfusion during aortic arch procedures. *Ann Thorac Surg.* 2002;74:426–31.
700. Ehrlich MP, Hagl C, McCullough JN, et al. Retrograde cerebral perfusion provides negligible flow through brain capillaries in the pig. *J Thorac Cardiovasc Surg.* 2001;122:331–8.
701. Karadeniz U, Erdemli O, Ozatik MA, et al. Assessment of cerebral blood flow with transcranial Doppler in right brachial artery perfusion patients. *Ann Thorac Surg.* 2005;79:139–46.
702. Neri E, Massetti M, Barabesi L, et al. Extrathoracic cannulation of the left common carotid artery in thoracic aorta operations through a left thoracotomy: preliminary experience in 26 patients. *J Thorac Cardiovasc Surg.* 2002;123:901–10.
703. Wozniak G, Dapper F, Zickmann B, et al. Selective Cerebral perfusion via innominate artery in aortic arch replacement without deep hypothermic circulatory arrest. *Int J Angiol.* 1999;8:50–6.
704. Yilik L, Emrehan B, Kestelli M, et al. Direct versus side-graft cannulation of the right axillary artery for antegrade cerebral perfusion. *Tex Heart Inst J.* 2006;33:310–5.
705. Olsson C, Thelin S. Antegrade cerebral perfusion with a simplified technique: unilateral versus bilateral perfusion. *Ann Thorac Surg.* 2006;81:868–74.
706. Harrington DK, Walker AS, Kaukuntla H, et al. Selective antegrade cerebral perfusion attenuates brain metabolic deficit in aortic arch surgery: a prospective randomized trial. *Circulation.* 2004;110:II231–II236.
707. Neri E, Sassi C, Barabesi L, et al. Cerebral autoregulation after hypothermic circulatory arrest in operations on the aortic arch. *Ann Thorac Surg.* 2004;77:72–9.
708. Cook RC, Gao M, Macnab AJ, et al. Aortic arch reconstruction: safety of moderate hypothermia and antegrade cerebral perfusion during systemic circulatory arrest. *J Card Surg.* 2006;21:158–64.
709. Bahktiary F. Cerebral perfusion associated with profound hypothermia. *J Thorac Cardiovasc Surg.* 2006;132:153–154. Abstract.
710. Kamiya H, Hagl C, Kropivnitskaya I, et al. The safety of moderate hypothermic lower body circulatory arrest with selective cerebral perfusion: a propensity score analysis. *J Thorac Cardiovasc Surg.* 2007;133:501–9.
711. Kaneda T, Saga T, Onoe M, et al. Antegrade selective cerebral perfusion with mild hypothermic systemic circulatory arrest during thoracic aortic surgery. *Scand Cardiovasc J.* 2005;39:87–90.
712. Testolin L, Roques X, Laborde MN, et al. Moderately hypothermic cardiopulmonary bypass and selective cerebral perfusion in ascending aorta and aortic arch surgery. Preliminary experience in twenty-two patients. *Cardiovasc Surg.* 1998;6:398–405.
713. Khan SN, Stansby G. Cerebrospinal fluid drainage for thoracic and thoracoabdominal aortic aneurysm surgery. *Cochrane Database Syst Rev.* 2004;CD003635.
714. Safi HJ, Hess KR, Randal M, et al. Cerebrospinal fluid drainage and distal aortic perfusion: reducing neurologic complications in repair of thoracoabdominal aortic aneurysm types I and II. *J Vasc Surg.* 1996;23:223–8.
715. Hollier LH, Money SR, Naslund TC, et al. Risk of spinal cord dysfunction in patients undergoing thoracoabdominal aortic replacement. *Am J Surg.* 1992;164:210–3.
716. Cambria RP, Davison JK, Zannetti S, et al. Clinical experience with epidural cooling for spinal cord protection during thoracic and thoracoabdominal aneurysm repair. *J Vasc Surg.* 1997;25:234–41.
717. Woloszyn TT, Marini CP, Coons MS, et al. Cerebrospinal fluid drainage and steroids provide better spinal cord protection during aortic cross-clamping than does either treatment alone. *Ann Thorac Surg.* 1990;49:78–82.
718. Ogino H, Sasaki H, Minatoya K, et al. Combined use of adamkiewicz artery demonstration and motor-evoked potentials in descending and thoracoabdominal repair. *Ann Thorac Surg.* 2006;82:592–6.
719. Guerit JM, Witdoeck C, Verhelst R, et al. Sensitivity, specificity, and surgical impact of somatosensory evoked potentials in descending aorta surgery. *Ann Thorac Surg.* 1999;67:1943–6.
720. Mauney MC, Blackburne LH, Langenburg SE, et al. Prevention of spinal cord injury after repair of the thoracic or thoracoabdominal aorta. *Ann Thorac Surg.* 1995;59:245–52.
721. Niessen K, Karsan A. Notch signaling in the developing cardiovascular system. *Am J Physiol Cell Physiol.* 2007;293:C1–11.
722. Crafoord C, Hierton T. Surgical treatment of thrombotic obliteration of the aortic bifurcation. *Acta Chir Scand.* 1952;104:81–6.
723. Hollier LH, Symmonds JB, Pairolero PC, et al. Thoracoabdominal aortic aneurysm repair. Analysis of postoperative morbidity. *Arch Surg.* 1988;123:871–5.
724. Greenberg RK, Lu Q, Roselli EE, et al. Contemporary analysis of descending thoracic and thoracoabdominal aneurysm repair: a comparison of endovascular and open techniques. *Circulation.* 2008;118:808–17.
725. Svensson LG, Patel V, Robinson MF, et al. Influence of preservation or perfusion of intraoperatively identified spinal cord blood supply on spinal motor evoked potentials and paraplegia after aortic surgery. *J Vasc Surg.* 1991;13:355–65.
726. Svensson LG, Von Ritter CM, Groeneveld HT, et al. Cross-clamping of the thoracic aorta. Influence of aortic shunts, laminectomy, papaverine, calcium channel blocker, allopurinol, and superoxide dismutase on spinal cord blood flow and paraplegia in baboons. *Ann Surg.* 1986;204:38–47.
727. Juvonen T, Biancari F, Rimpilainen J, et al. Strategies for spinal cord protection during descending thoracic and thoracoabdominal aortic surgery: Up-to-date experimental and clinical results: a review. *Scand Cardiovasc J.* 2002;36:136–60.
728. Lotto ML, Banoub M, Schubert A. Effects of anesthetic agents and physiologic changes on intraoperative motor evoked potentials. *J Neurosurg Anesthesiol.* 2004;16:32–42.
729. Angel A, LeBeau F. A comparison of the effects of propofol with other anaesthetic agents on the centripetal transmission of sensory information. *Gen Pharmacol.* 1992;23:945–63.
730. Chen Z. The effects of isoflurane and propofol on intraoperative neurophysiological monitoring during spinal surgery. *J Clin Monit Comput.* 2004;18:303–8.
731. Clapcich AJ, Emerson RG, Roye DP Jr., et al. The effects of propofol, small-dose isoflurane, and nitrous oxide on cortical somatosensory evoked potential and bispectral index monitoring in adolescents undergoing spinal fusion. *Anesth Analg.* 2004;99:1334–40.
732. King J, Sloan TB. *Evoked Potentials Intraoperative Monitoring of the Spinal Cord and Peripheral Nerves.* St. Louis: Mosby; 2001.
733. Moller AR. *Intraoperative Neurophysiologic Monitoring.* Luxembourg: Harwood, 1995.
734. Nuwer MR, Dawson EG, Carlson LG, et al. Somatosensory evoked potential spinal cord monitoring reduces neurologic deficits after scoliosis surgery: results of a large multicenter survey. *Electroencephalogr Clin Neurophysiol.* 1995;96:6–11.
735. Peterson DO, Drummond JC, Todd MM. Effects of halothane, enflurane, isoflurane, and nitrous oxide on somatosensory evoked potentials in humans. *Anesthesiology.* 1986;65:35–40.
736. Scheufler KM, Zentner J. Total intravenous anesthesia for intraoperative monitoring of the motor pathways: an integral view combining clinical and experimental data. *J Neurosurg.* 2002;96:571–9.
737. Sloan T. Evoked potentials. In: Albin MS, editor. *A Textbook of Neuroanesthesia With Neurosurgical and Neuroscience Perspectives.* New York: McGraw-Hill, 1997;221–76.
738. Sloan TB, Heyer EJ. Anesthesia for intraoperative neurophysiologic monitoring of the spinal cord. *J Clin Neurophysiol.* 2002;19:430–43.
739. Crawford ES, Mizrahi EM, Hess KR, et al. The impact of distal aortic perfusion and somatosensory evoked potential monitoring on prevention of paraplegia after aortic aneurysm operation. *J Thorac Cardiovasc Surg.* 1988;95:357–67.
740. Lyon R, Feiner J, Lieberman JA. Progressive suppression of motor evoked potentials during general anesthesia: the phenomenon of “anesthetic fade.” *J Neurosurg Anesthesiol.* 2005;17:13–9.
741. Etz CD, Halstead JC, Spielvogel D, et al. Thoracic and thoracoabdominal aneurysm repair: is reimplantation of spinal cord arteries a waste of time? *Ann Thorac Surg.* 2006;82:1670–7.
742. Svensson LG, Stewart RW, Cosgrove DM III, et al. Intrathecal papaverine for the prevention of paraplegia after operation on the thoracic or thoracoabdominal aorta. *J Thorac Cardiovasc Surg.* 1988;96:823–9.
743. Laschinger JC. Spinal cord injury following surgical correction of acute aortic disruption. *Semin Thorac Cardiovasc Surg.* 1992;4:217–22.
744. Piano G, Gewertz BL. Mechanism of increased cerebrospinal fluid pressure with thoracic aortic occlusion. *J Vasc Surg.* 1990;11:695–701.
745. Spence PA, Lust RM, Iida H, et al. Reappraisal of the mechanism for cerebrospinal fluid hypertension during aortic surgery. *Circulation.* 1990;82:IV51–IV57.
746. Dardik A, Perler BA, Roseborough GS, et al. Subdural hematoma after thoracoabdominal aortic aneurysm repair: an underreported complication of spinal fluid drainage? *J Vasc Surg.* 2002;36:47–50.

747. Roland PS, Marple BF, Meyerhoff WL, et al. Complications of lumbar spinal fluid drainage. *Otolaryngol Head Neck Surg.* 1992;107:564–9.
748. Mutch WA, Thomson IR, Teskey JM, et al. Phlebotomy reverses the hemodynamic consequences of thoracic aortic cross-clamping: relationships between central venous pressure and cerebrospinal fluid pressure. *Anesthesiology.* 1991;74:320–4.
749. Mutch WA, Thiessen DB, Girling LG, et al. Neuroanesthesia adjunct therapy (mannitol and hyperventilation) is as effective as cerebrospinal fluid drainage for prevention of paraplegia after descending thoracic aortic cross-clamping in the dog. *Anesth Analg.* 1995;81:800–5.
750. Cheung AT, Pochettino A, Guvakov DV, et al. Safety of lumbar drains in thoracic aortic operations performed with extracorporeal circulation. *Ann Thorac Surg.* 2003;76:1190–6.
751. Grocott HP, Nussmeier NA. Neuroprotection in cardiac surgery. *Anesthesiol Clin North Am.* 2003;21:487–509, viii.
752. Hindman BJ, Todd MM. Improving neurologic outcome after cardiac surgery. *Anesthesiology.* 1999;90:1243–7.
753. Moomiaie RM, Ransden J, Stein J, et al. Cooling catheter for spinal cord preservation in thoracic aortic surgery. *J Cardiovasc Surg (Torino).* 2007;48:103–8.
754. Barone GW, Joob AW, Flanagan TL, et al. The effect of hyperemia on spinal cord function after temporary thoracic aortic occlusion. *J Vasc Surg.* 1988;8:535–40.
755. Jacobs MJ, de Mol BA, Legemate DA, et al. Retrograde aortic and selective organ perfusion during thoracoabdominal aortic aneurysm repair. *Eur J Vasc Endovasc Surg.* 1997;14:360–6.
756. Koksoy C, Lemaire SA, Curling PE, et al. Renal perfusion during thoracoabdominal aortic operations: cold crystalloid is superior to normothermic blood. *Ann Thorac Surg.* 2002;73:730–8.
757. Perdue PW, Balsler JR, Lipsett PA, et al. “Renal dose” dopamine in surgical patients: dogma or science? *Ann Surg.* 1998;227:470–3.
758. Hager B, Betschart M, Krapf R. Effect of postoperative intravenous loop diuretic on renal function after major surgery. *Schweiz Med Wochenschr.* 1996;126:666–73.
759. Godet G, Fleron MH, Vicaut E, et al. Risk factors for acute postoperative renal failure in thoracic or thoracoabdominal aortic surgery: a prospective study. *Anesth Analg.* 1997;85:1227–32.
760. Nicholson ML, Baker DM, Hopkinson BR, et al. Randomized controlled trial of the effect of mannitol on renal reperfusion injury during aortic aneurysm surgery. *Br J Surg.* 1996;83:1230–3.
761. Baldwin L, Henderson A, Hickman P. Effect of postoperative low-dose dopamine on renal function after elective major vascular surgery. *Ann Intern Med.* 1994;120:744–7.
762. Paul MD, Mazer CD, Byrick RJ, et al. Influence of mannitol and dopamine on renal function during elective infrarenal aortic clamping in man. *Am J Nephrol.* 1986;6:427–34.
763. Pavoni V, Verri M, Ferraro L, et al. Plasma dopamine concentration and effects of low dopamine doses on urinary output after major vascular surgery. *Kidney Int Suppl.* 1998;66:S75–S80.
764. Salem MG, Crooke JW, McLoughlin GA, et al. The effect of dopamine on renal function during aortic cross clamping. *Ann R Coll Surg Engl.* 1988;70:9–12.
765. Zehr KJ, Orszulak TA, Mullany CJ, et al. Surgery for aneurysms of the aortic root: a 30-year experience. *Circulation.* 2004;110:1364–71.
766. Motomura N, Miyata H, Tsukihara H, et al. Risk model of thoracic aortic surgery in 4707 cases from a nationwide single-race population through a web-based data entry system: the first report of 30-day and 30-day operative outcome risk models for thoracic aortic surgery. *Circulation.* 2008;118:S153–9.
767. Kouchoukos NT, Masetti P, Mauney MC, et al. One-stage repair of extensive chronic aortic dissection using the arch-first technique and bilateral anterior thoracotomy. *Ann Thorac Surg.* 2008;86:1502–9.
768. Coselli JS, Bozinovski J, Lemaire SA. Open surgical repair of 2286 thoracoabdominal aortic aneurysms. *Ann Thorac Surg.* 2007;83:S862–S864.
769. Etz CD, Luehr M, Kari FA, et al. Paraplegia after extensive thoracic and thoracoabdominal aortic aneurysm repair: does critical spinal cord ischemia occur postoperatively? *J Thorac Cardiovasc Surg.* 2008;135:324–30.
770. Keyhani K, Miller CC III, Estrera AL, et al. Analysis of motor and somatosensory evoked potentials during thoracic and thoracoabdominal aortic aneurysm repair. *J Vasc Surg.* 2009;49:36–41.
771. Lemaire SA, Jones MM, Conklin LD, et al. Randomized comparison of cold blood and cold crystalloid renal perfusion for renal protection during thoracoabdominal aortic aneurysm repair. *J Vasc Surg.* 2009;49:11–9.
772. Safi HJ, Estrera AL, Azizzadeh A, et al. Progress and future challenges in thoracoabdominal aortic aneurysm management. *World J Surg.* 2008;32:355–60.
773. Svensson LG, Hess KR, Coselli JS, et al. Influence of segmental arteries, extent, and atriofemoral bypass on postoperative paraplegia after thoracoabdominal aortic operations. *J Vasc Surg.* 1994;20:255–62.
774. Borger MA, Preston M, Ivanov J, et al. Should the ascending aorta be replaced more frequently in patients with bicuspid aortic valve disease? *J Thorac Cardiovasc Surg.* 2004;128:677–83.
775. Sioris T, David TE, Ivanov J, et al. Clinical outcomes after separate and composite replacement of the aortic valve and ascending aorta. *J Thorac Cardiovasc Surg.* 2004;128:260–5.
776. David TE, Ivanov J, Armstrong S, et al. Aortic valve-sparing operations in patients with aneurysms of the aortic root or ascending aorta. *Ann Thorac Surg.* 2002;74:S1758–S1761.
777. Trimarchi S, Nienaber CA, Rampoldi V, et al. Contemporary results of surgery in acute type A aortic dissection: The International Registry of Acute Aortic Dissection experience. *J Thorac Cardiovasc Surg.* 2005;129:112–22.
778. Sundt TM III, Orszulak TA, Cook DJ, et al. Improving results of open arch replacement. *Ann Thorac Surg.* 2008;86:787–96.
779. Spielvogel D, Halstead JC, Meier M, et al. Aortic arch replacement using a trifurcated graft: simple, versatile, and safe. *Ann Thorac Surg.* 2005;80:90–5.
780. Safi HJ, Estrera AL, Miller CC, et al. Evolution of risk for neurologic deficit after descending and thoracoabdominal aortic repair. *Ann Thorac Surg.* 2005;80:2173–9.
781. Svensson LG, Hess KR, D’Agostino RS, et al. Reduction of neurologic injury after high-risk thoracoabdominal aortic operation. *Ann Thorac Surg.* 1998;66:132–8.
782. Rigberg DA, McGory ML, Zingmond DS, et al. Thirty-day mortality statistics underestimate the risk of repair of thoracoabdominal aortic aneurysms: a statewide experience. *J Vasc Surg.* 2006;43:217–22.
783. Knipp BS, Deeb GM, Prager RL, et al. A contemporary analysis of outcomes for operative repair of type A aortic dissection in the United States. *Surgery.* 2007;142:524–8.
784. Grundy SM. United States Cholesterol Guidelines 2001: expanded scope of intensive low-density lipoprotein-lowering therapy. *Am J Cardiol.* 2001;88:23J–7J.
785. Davies RR, Kaple RK, Mandapati D, et al. Natural history of ascending aortic aneurysms in the setting of an unreplaced bicuspid aortic valve. *Ann Thorac Surg.* 2007;83:1338–44.
786. Song JM, Kim SD, Kim JH, et al. Long-term predictors of descending aorta aneurysmal change in patients with aortic dissection. *J Am Coll Cardiol.* 2007;50:799–804.
787. Halstead JC, Meier M, Etz C, et al. The fate of the distal aorta after repair of acute type A aortic dissection. *J Thorac Cardiovasc Surg.* 2007;133:127–35.
788. Immer FF, Krahenbuhl E, Hagen U, et al. Large area of the false lumen favors secondary dilatation of the aorta after acute type A aortic dissection. *Circulation.* 2005;112:1249–1252.
789. Sundt TM. Intramural hematoma and penetrating atherosclerotic ulcer of the aorta. *Ann Thorac Surg.* 2007;83:S835–S841.
790. Benowitz NL. Drug therapy. Pharmacologic aspects of cigarette smoking and nicotine addiction. *N Engl J Med.* 1988;319:1318–30.
791. Grundy SM, Becker DMCLT. Third Report of the National Cholesterol Education Program (NCEP) Expert Panel on Detection, Evaluation, and Treatment of High Blood Cholesterol in Adults (Adult Treatment Panel III) final report. *Circulation.* 2002;106:3143–421.
792. Wung SF, Aouizerat BE. Newly mapped gene for thoracic aortic aneurysm and dissection. *J Cardiovasc Nurs.* 2004;19:409–16.
793. Davidson JE, Powers K, Hedayat KM, et al. Clinical practice guidelines for support of the family in the patient-centered intensive care unit: American College of Critical Care Medicine Task Force 2004–2005. *Crit Care Med.* 2007;35:605–22.
794. Latessa V. Endovascular stent-graft repair of descending thoracic aortic aneurysms: the nursing implications for care. *J Vasc Nurs.* 2002;20:86–93.
795. Garber AJ, Moghissi ES, Bransome ED Jr., et al. American College of Endocrinology position statement on inpatient diabetes and metabolic control. *Endocr Pract.* 2004;10:77–82.
796. Van den Berghe G, Wouters P, Weekers F, et al. Intensive insulin therapy in the critically ill patients. *N Engl J Med.* 2001;345:1359–67.

797. Furnary AP, Gao G, Grunkemeier GL, et al. Continuous insulin infusion reduces mortality in patients with diabetes undergoing coronary artery bypass grafting. *J Thorac Cardiovasc Surg*. 2003;125:1007–21.
798. Inzucchi SE. Clinical practice. Management of hyperglycemia in the hospital setting. *N Engl J Med*. 2006;355:1903–11.
799. Miyairi T, Takamoto S, Kotsuka Y, et al. Comparison of neurocognitive results after coronary artery bypass grafting and thoracic aortic surgery using retrograde cerebral perfusion. *Eur J Cardiothorac Surg*. 2005;28:97–101.
800. Eagle KA, Isselbacher EM, DeSanctis RW. Cocaine-related aortic dissection in perspective. *Circulation*. 2002;105:1529–30.
801. Maron BJ, Chaitman BR, Ackerman MJ, et al. Recommendations for physical activity and recreational sports participation for young patients with genetic cardiovascular diseases. *Circulation*. 2004;109:2807–16.
802. Williams MA, Haskell WL, Ades PA, et al. Resistance exercise in individuals with and without cardiovascular disease: 2007 update: a scientific statement from the American Heart Association Council on Clinical Cardiology and Council on Nutrition, Physical Activity, and Metabolism. *Circulation*. 2007;116:572–84.
803. Palatini P, Mos L, Munari L, et al. Blood pressure changes during heavy-resistance exercise. *J Hypertens Suppl*. 1989;7:S72–S73.
804. Hatzaras I, Tranquilli M, Coady M, et al. Weight lifting and aortic dissection: more evidence for a connection. *Cardiology*. 2007;107:103–6.
805. Nataf P, Lansac E. Dilation of the thoracic aorta: medical and surgical management. *Heart*. 2006;92:1345–52.
806. Elefteriades JA, Hatzaras I, Tranquilli MA, et al. Weight lifting and rupture of silent aortic aneurysms. *JAMA*. 2003;290:2803.
807. Williams OD. Quality of care versus provider volume: does one lead to the other? *Med Care*. 2003;41:1127–8.
808. Hill JS, McPhee JT, Messina LM, et al. Regionalization of abdominal aortic aneurysm repair: evidence of a shift to high-volume centers in the endovascular era. *J Vasc Surg*. 2008;48:29–36.
809. Schermerhorn ML, Giles KA, Hamdan AD, et al. Population-based outcomes of open descending thoracic aortic aneurysm repair. *J Vasc Surg*. 2008.
810. Norgren L, Larzon T. Endovascular repair of the ruptured abdominal aortic aneurysm. *Scand J Surg*. 2008;97:178–81.
811. Troeng T. Volume versus outcome when treating abdominal aortic aneurysm electively: is there evidence to centralise? *Scand J Surg*. 2008;97:154–9.
- 811a. Bonow RO, Masoudi FA, Rumsfeld JS, et al. ACC/AHA classification of care metrics: performance measures and quality metrics: a report of the American College of Cardiology/American Heart Association Task Force on Performance Measures. *J Am Coll Cardiol*. 2008;52:2113–7.
812. Estes NA III, Halperin JL, Calkins H, et al. ACC/AHA/Physician Consortium 2008 clinical performance measures for adults with nonvalvular atrial fibrillation or atrial flutter. *J Am Coll Cardiol*. 2008;51:865–84.
813. Krumholz HM, Anderson JL, Brooks NH, et al. ACC/AHA clinical performance measures for adults with ST-elevation and non-ST-elevation myocardial infarction. *J Am Coll Cardiol*. 2006;47:236–65.
814. Thomas RJ, King M, Lui K, et al. AACVPR/ACC/AHA 2007 Performance measures on cardiac rehabilitation for referral to and delivery of cardiac rehabilitation/secondary prevention services. *J Am Coll Cardiol*. 2007;50:1400–33.
815. Luft HS. From observing the relationship between volume and outcome to making policy recommendations: comments on Sheikh. *Med Care*. 2003;41:1118–22.
816. Ting HH, Yang EH, Rihal CS. Narrative review: reperfusion strategies for ST-segment elevation myocardial infarction. *Ann Intern Med*. 2006;145:610–7.
817. Luft HS, Bunker JP, Enthoven AC. Should operations be regionalized? The empirical relation between surgical volume and mortality. *N Engl J Med*. 1979;301:1364–9.
818. Dudley RA, Johansen KL, Brand R, et al. Selective referral to high-volume hospitals: estimating potentially avoidable deaths. *JAMA*. 2000;283:1159–66.
819. Jacobs AK. Regional systems of care for patients with ST-elevation myocardial infarction: being at the right place at the right time. *Circulation*. 2007;116:689–92.
820. Rosenberg AL, Hofer TP, Strachan C, et al. Accepting critically ill transfer patients: adverse effect on a referral center's outcome and benchmark measures. *Ann Intern Med*. 2003;138:882–90.
821. Kosseim M, Mayo NE, Scott S, et al. Ranking hospitals according to acute myocardial infarction mortality: should transfers be included? *Med Care*. 2006;44:664–70.
822. Leonard JC. Thomas Beville Peacock and the early history of dissecting aneurysm. *Br Med J*. 1979;2:260–2.
823. Reece TB, Green GR, Kron IL. Aortic dissection. In: Cohn LH, editor. *Cardiac Surgery in the Adult*. New York: McGraw-Hill, 2008;1195–222.
824. Gore I. Pathogenesis of dissecting aneurysm of the aorta. *AMA Arch Pathol*. 1952;53:142–53.
825. Krukenberg E. Beiträge zur pathologischen Anatomie und zur allgemeinen Pathologie. *Beitr Pathol Anat Allg Pathol*. 1920;67:329–51.
826. Toda R, Moriyama Y, Masuda H, et al. Organ malperfusion in acute aortic dissection. *Jpn J Thorac Cardiovasc Surg*. 2000;48:545–50.
827. Dietz H, Devereaux R, Loeys BL. NHLBI working group research in Marfan syndrome and related disorders. Available at: <http://www.nhlbi.nih.gov/meetings/workshops/marfan20070430.htm>. Accessed January 7, 2010.

KEY WORDS: ACC/AHA Clinical Practice Guideline ■ thoracic aortic disease ■ thoracic aortic dissection ■ thoracic aortic aneurysm ■ intramural hematoma ■ genetic syndromes associated with thoracic aortic aneurysm ■ emergency department ■ acute thoracic aortic disease presentation and evaluation

**Appendix 1. Author Relationships With Industry and Other Entities—2010 ACCF/AHA/AATS/ACR/ASA/SCA/SCAI/SIR/STS/SVM Guidelines for the Diagnosis and Management of Patients With Thoracic Aortic Disease**

Committee Member	Employment	Consultant	Speaker	Ownership/ Partnership/ Principal	Research	Institutional, Organizational or Other Financial Benefit	Expert Witness
Loren F. Hiratzka, <i>Chair</i>	Cardiac, Vascular & Thoracic Surgeons Inc. and TriHealth Inc.—Medical Director, Cardiac Surgery	None	None	None	None	None	● 2007; Defense; Aortic Dissection
George L. Bakris	University of Chicago Medical Center—Professor of Medicine; Director, Hypertension Center	<ul style="list-style-type: none"> <li>● Abbott</li> <li>● Boehringer Ingelheim</li> <li>● Bristol-Myers Squibb/Sanofi-aventis</li> <li>● Forest Laboratories</li> <li>● GlaxoSmithKline</li> <li>● Merck</li> </ul>	<ul style="list-style-type: none"> <li>● Forest Laboratories</li> <li>● GlaxoSmithKline</li> <li>● Merck</li> <li>● Novartis</li> </ul>	None	<ul style="list-style-type: none"> <li>● Forest Laboratories</li> <li>● GlaxoSmithKline</li> <li>● Myogen</li> <li>● National Institutes of Health (NIDDK/NHLBI)</li> </ul>	None	None
Joshua A. Beckman	Brigham & Women's Hospital—Director, Cardiovascular Fellows Program	<ul style="list-style-type: none"> <li>● Bristol-Myers Squibb</li> <li>● Sanofi-aventis</li> </ul>	<ul style="list-style-type: none"> <li>● Bristol-Myers Squibb</li> <li>● GlaxoSmithKline</li> <li>● Merck</li> <li>● Sanofi-aventis</li> </ul>	None	None	None	None
Robert M. Bersin	Seattle Cardiology—Director, Endovascular Services & Clinical Research	<ul style="list-style-type: none"> <li>● Abbott Vascular</li> <li>● Boston Scientific</li> <li>● Bristol-Myers Squibb</li> <li>● Cordis Endovascular</li> <li>● Eli Lilly</li> <li>● EV3</li> <li>● Revascular Therapeutics</li> <li>● Sanofi-aventis</li> <li>● Vascular Solution</li> <li>● W.L. Gore</li> </ul>	<ul style="list-style-type: none"> <li>● Boston Scientific</li> <li>● Bristol-Myers Squibb</li> <li>● Daiichi Sankyo</li> <li>● Eli Lilly</li> <li>● Sanofi-aventis</li> <li>● The Medicines Company</li> </ul>	● Vascular Solutions	● Boston Scientific	<ul style="list-style-type: none"> <li>● Boston Scientific</li> <li>● Cordis Endovascular</li> <li>● Vascular Solutions</li> </ul>	● Expert witness in a case involving iatrogenic type B dissection
Vincent F. Carr	Uniformed Services University of Health Science—Professor of Medicine	None	None	None	None	None	None
Donald E. Casey, Jr	Atlantic Health—Vice President of Quality & Chief Medical Officer; Associate Professor of Medicine, Mount Sinai School of Medicine	None	None	None	None	None	None
Kim A. Eagle	University of Michigan Health System—Albion Walter Professor of Internal Medicine; Clinical Director, Cardiovascular Center	<ul style="list-style-type: none"> <li>● NHLBI</li> <li>● Robert Wood Johnson Foundation</li> <li>● Sanofi-aventis</li> </ul>	None	None	<ul style="list-style-type: none"> <li>● Blue Cross/Blue Shield</li> <li>● Bristol-Myers Squibb</li> <li>● National Institutes of Health</li> <li>● Pfizer</li> </ul>	None	None
Luke K. Hermann	Mount Sinai Medical Center—Assistant Professor of Emergency Medicine; Director, Chest Pain Unit	None	None	None	None	None	None
Eric M. Isselbacher	Massachusetts General Hospital—Associate Professor of Medicine, Harvard Medical School; Co-Director, Thoracic Aortic Center	None	None	None	None	None	● 2007; Plaintiff; Aortic Dissection
Ella A. Kazerooni	University of Michigan Health System—Professor of Medicine; Director, Cardiothoracic Radiology	<ul style="list-style-type: none"> <li>● GE Healthcare</li> <li>● Vital Images</li> </ul>	None	None	None	● GERRAF (GE Radiology Research Fellowship)	None
Nicholas T. Kouchoukos	Missouri Baptist Medical Center—Cardiovascular Surgeon	● Edwards Lifesciences	None	None	None	None	● 2006; Defense; Aortic Dissection

(Continued)

**Appendix 1. Continued**

Committee Member	Employment	Consultant	Speaker	Ownership/ Partnership/ Principal	Research	Institutional, Organizational or Other Financial Benefit	Expert Witness
Bruce W. Lytle	The Cleveland Clinic—Chair, Heart and Vascular Institute	None	None	None	None	None	None
Dianna M. Milewicz	University of Texas Southwestern Medical Center—President George H.W. Bush Chair in Cardiovascular Medicine; Professor & Director, Division of Medical Genetics	None	None	None	<ul style="list-style-type: none"> <li>● Doris Duke Foundation</li> <li>● Genetech</li> <li>● National Institutes of Health</li> <li>● Vivian Smith Foundation</li> </ul>	None	None
David L. Reich	Mount Sinai Medical Center—Professor & Chair, Department of Anesthesiology	None	None	None	None	None	None
Souvik Sen	University of South Carolina School of Medicine—Professor and Chair, Department of Neurology	<ul style="list-style-type: none"> <li>● Coaxia</li> <li>● Bristol-Myers Squibb</li> <li>● Pfizer</li> <li>● Sanofi-aventis</li> </ul>	<ul style="list-style-type: none"> <li>● Boehringer Ingelheim</li> </ul>	None	<ul style="list-style-type: none"> <li>● American Heart Association</li> <li>● Genetech</li> <li>● Sanofi-aventis</li> </ul>	None	None
Julie A. Shinn	Stanford University School of Medicine—Cardiovascular Clinical Nurse Specialist	None	None	None	None	None	None
Lars G. Svensson	The Cleveland Clinic—Director, The Center for Aortic Surgery; Director, Marfan Syndrome and Collective Tissue Disorder Clinic	None	None	None	<ul style="list-style-type: none"> <li>● Edwards Lifesciences</li> <li>● Evalve</li> </ul>	None	None
David M. Williams	University of Michigan Health System—Professor, Department of Radiology; Director, Interventional Radiology	<ul style="list-style-type: none"> <li>● W.L. Gore</li> </ul>	None	None	<ul style="list-style-type: none"> <li>● W.L. Gore</li> <li>● Medtronic</li> </ul>	None	<ul style="list-style-type: none"> <li>● 2000; Defense; Failure to diagnose and treat mesenteric ischemia with aortic dissection</li> <li>● 2009; Defense; Failure to diagnose and treat mesenteric ischemia with aortic dissection</li> </ul>

NHLBI indicates National Heart, Lung, and Blood Institute; NIDDK, National Institute of Diabetes and Digestive and Kidney Diseases.

This table represents the relevant relationships of committee members with industry and other entities that were reported orally at the initial writing committee meeting and updated in conjunction with all meetings and conference calls of the writing committee during the document development process. It does not necessarily reflect relationships with industry at the time of publication. A person is deemed to have a significant interest in a business if the interest represents ownership of 5% or more of the voting stock or share of the business entity, or ownership of \$10 000 or more of the fair market value of the business entity; or if funds received by the person from the business entity exceed 5% of the person's gross income for the previous year. A relationship is considered to be modest if it is less than significant under the preceding definition. Relationships noted in this table are modest unless otherwise noted.

\*Significant (greater than \$10 000) relationship.

**Appendix 2. Reviewer Relationships With Industry and Other Entities—2010 ACCF/AHA/AATS/ACR/ASA/SCA/SCAI/SIR/STS/SVM Guidelines for the Diagnosis and Management of Patients With Thoracic Aortic Disease**

Peer Reviewer	Representation	Consultant	Speaker	Ownership/ Partnership/ Principal	Research	Institutional, Organizational or Other Financial Benefit	Expert Witness
Amjad Almahameed	Official Reviewer—Society for Vascular Medicine	None	None	None	None	None	None
Richard A. Bernstein	Official Reviewer—American Stroke Association	None	None	None	None	None	None
Christopher E. Buller	Official Reviewer—ACCF/AHA Task Force Lead Reviewer	None	None	None	None	None	None
Albert T. Cheung	Official Reviewer—Society of Cardiovascular Anesthesiologists	<ul style="list-style-type: none"> <li>● EKR Therapeutics</li> <li>● The Medicines Company</li> <li>● Neuralstem</li> <li>● Schering Plough</li> </ul>	<ul style="list-style-type: none"> <li>● EKR Therapeutics</li> <li>● The Medicines Company</li> <li>● PDL Biopharm</li> </ul>	None	<ul style="list-style-type: none"> <li>● The Medicines Company*</li> <li>● Neuralstem*</li> <li>● PDL Biopharm*</li> </ul>	None	None
Michael D. Dake	Official Reviewer—Society of Interventional Radiologists	<ul style="list-style-type: none"> <li>● W.L. Gore*</li> <li>● Medtronic</li> </ul>	<ul style="list-style-type: none"> <li>● Cook</li> </ul>	None	<ul style="list-style-type: none"> <li>● Cook</li> <li>● W.L. Gore*</li> <li>● Medtronic</li> </ul>	None	None
Antionette S. Gomes	Official Reviewer—AHA Cardiovascular Surgery and Anesthesia Committee	None	None	None	None	None	None
Robert A. Guyton	Official Reviewer—ACCF Board of Trustees	<ul style="list-style-type: none"> <li>● Medtronic</li> </ul>	None	None	None	None	None
Clifford J. Kavinsky	Official Reviewer—Society for Cardiovascular Angiography and Interventions	None	None	None	<ul style="list-style-type: none"> <li>● Possis Corp.</li> </ul>	None	None
Scott Kinlay	Official Reviewer—Society for Vascular Medicine	None	<ul style="list-style-type: none"> <li>● Merck</li> <li>● Pfizer</li> </ul>	None	<ul style="list-style-type: none"> <li>● Pfizer</li> </ul>	None	None
Richard J. Kovacs	Official Reviewer—ACCF Board of Governors	None	None	None	None	None	None
Christine Mora Mangano	Official Reviewer—Society of Cardiovascular Anesthesiologists	None	None	None	None	None	None
Steven R. Messé	Official Reviewer—American Stroke Association	None	<ul style="list-style-type: none"> <li>● Boehringer Ingelheim</li> </ul>	None	<ul style="list-style-type: none"> <li>● American Heart Association*</li> </ul>	None	None
Eric Roselli	Official Reviewer—Society of Thoracic Surgeons	<ul style="list-style-type: none"> <li>● Medtronic</li> <li>● Vascutek</li> </ul>	None	None	<ul style="list-style-type: none"> <li>● Cook</li> </ul>	None	None
Geoff D. Rubin	Official Reviewer—American College of Radiology	<ul style="list-style-type: none"> <li>● Fovia</li> </ul>	<ul style="list-style-type: none"> <li>● Bracco</li> </ul>	<ul style="list-style-type: none"> <li>● TeraRecon</li> </ul>	<ul style="list-style-type: none"> <li>● Biosense-Webster*</li> </ul>	None	None
Frank J. Rybicki	Official Reviewer—American College of Radiology	<ul style="list-style-type: none"> <li>● Bracco</li> <li>● Siemens Medical</li> <li>● Toshiba Medical Systems*</li> <li>● Vital Images</li> </ul>	<ul style="list-style-type: none"> <li>● Bracco</li> <li>● Siemens Medical</li> <li>● Toshiba Medical Systems*</li> <li>● Vital Images</li> </ul>	<ul style="list-style-type: none"> <li>● Siemens Medical</li> </ul>	<ul style="list-style-type: none"> <li>● Bracco</li> <li>● Toshiba Medical Systems*</li> </ul>	None	None
Thoralf M. Sundt	Official Reviewer—American Association for Thoracic Surgery	None	None	None	<ul style="list-style-type: none"> <li>● Bolton Medical</li> </ul>	<ul style="list-style-type: none"> <li>● Atricure</li> <li>● Bolton Medical</li> <li>● Jarvik Heart</li> <li>● Medtronic</li> <li>● Sorin Group/Carbomedics</li> <li>● St. Jude Medical</li> <li>● Thoratec Corporation</li> <li>● Ventracor</li> <li>● W.L. Gore</li> </ul>	None
Richard D. White	Official Reviewer—AHA Peripheral Vascular Disease Council	None	None	None	None	None	None

(Continued)

**Appendix 2. Continued**

Peer Reviewer	Representation	Consultant	Speaker	Ownership/ Partnership/ Principal	Research	Institutional, Organizational or Other Financial Benefit	Expert Witness
James P. Zidar	Official Reviewer—Society for Cardiovascular Angiography and Interventions	<ul style="list-style-type: none"> <li>● Abbott Vascular</li> <li>● Cordis*</li> <li>● Medtronic Vascular</li> </ul>	<ul style="list-style-type: none"> <li>● Abbott Vascular</li> <li>● Cordis*</li> <li>● Medtronic Vascular</li> </ul>	None	<ul style="list-style-type: none"> <li>● Abbott Vascular</li> <li>● Cordis*</li> <li>● Medtronic Vascular</li> </ul>	None	None
Wyatt Decker	Organizational Reviewer—American College of Emergency Physicians	None	None	None	None	None	None
Josh M. Kosowsky	Organizational Reviewer—American College of Emergency Physicians	None	None	None	None	None	None
Emile Mohler	Organizational Reviewer—American College of Physicians	None	None	None	None	None	None
James Burke	Content Reviewer—ACCF Catherization Committee	None	None	None	None	None	None
Edward P. Chen	Content Reviewer	None	None	None	None	None	None
Mark A. Creager	Content Reviewer—ACCF/AHA Task Force on Practice Guidelines	None	None	None	None	None	None
Jose G. Diez	Content Reviewer—ACCF Catherization Committee	<ul style="list-style-type: none"> <li>● Sanofi-aventis</li> </ul>	None	None	None	None	None
John A. Elefteriades	Content Reviewer	<ul style="list-style-type: none"> <li>● Baxter</li> </ul>	None	<ul style="list-style-type: none"> <li>● Coolspine</li> </ul>	<ul style="list-style-type: none"> <li>● Celera Diagnostics</li> </ul>	None	<ul style="list-style-type: none"> <li>● 2006; Plaintiff; Aortic Dissection*</li> </ul>
D. Craig Miller	Content Reviewer	<ul style="list-style-type: none"> <li>● Medtronic</li> </ul>	<ul style="list-style-type: none"> <li>● St. Jude Medical</li> </ul>	None	<ul style="list-style-type: none"> <li>● NHLBI</li> <li>● Stanford PARTNER Trial</li> </ul>	None	None
Rick Nishimura	Content Reviewer—ACCF/AHA Task Force on Practice Guidelines	None	None	None	None	None	None
Patrick T. O'Gara	Content Reviewer	None	None	None	None	None	None
Carlos Ruiz	Content Reviewer—ACCF Interventional Council	None	None	None	None	None	None

ACCF indicates American College of Cardiology Foundation; AHA, American Heart Association; NHLBI, National Heart, Lung, and Blood Institute.

This table represents the relevant relationships with industry and other entities that were disclosed at the time of peer review. It does not necessarily reflect relationships with industry at the time of publication. A person is deemed to have a significant interest in a business if the interest represents ownership of 5% or more of the voting stock or share of the business entity, or ownership of \$10 000 or more of the fair market value of the business entity; or if funds received by the person from the business entity exceed 5% of the person's gross income for the previous year. A relationship is considered to be modest if it is less than significant under the preceding definition. Relationships in this table are modest unless otherwise noted. Names are listed in alphabetical order within each category of review.

\*Significant (greater than \$10 000) relationship.

**Appendix 3. Abbreviation List**

---

AAA=abdominal aortic aneurysm  
AoD=aortic dissection  
CAD=coronary artery disease  
CSF=cerebrospinal fluid  
CT=computed tomographic imaging  
ECG=electrocardiogram  
GCA=giant cell arteritis  
IMH=intramural hematoma  
INR=international normalized ratio  
IRAD=International Registry of Acute Aortic Dissection  
MEP= motor evoked potential  
MI=myocardial infarction  
MMP=matrix metalloproteinase  
MR=magnetic resonance imaging  
PAU=penetrating atherosclerotic ulcer  
SSEP=somatosensory evoked potentials  
SSFP=steady-state free precession  
STEMI=ST-elevation myocardial infarction  
TAA=thoracoabdominal aneurysm  
TEE=transesophageal echocardiogram  
TIA=transient ischemic attack  
TRA=traumatic rupture of the aorta  
TTE=transthoracic echocardiogram  
UHC=University HealthSystem Consortium

---